



NOTES and single access surgery

Special Interest Group Reproductive Surgery

7

27 June 2010
Rome, Italy

PRE-CONGRESS COURSE 7 – Table of contents

NOTES and single access surgery

Organised by the Special Interest Group Reproductive Surgery

Introduction to ESHRE	Page 3
Course programme	Page 9
Speakers' contributions	
Natural orifice transluminal endoscopic surgery: history and present – Marcus Dantas (Brazil)	Page 11
NOTES and the exploration of the female pelvis - Patrick Puttemans (Belgium)	Page 23
Single access surgery and development of new instruments - Joseph Nassif (France)	Page 50
Single access surgery and the uterine cavity, called hysteroscopy - Milan Reljic (Slovenia)	Page 56
NOTES and the exploration of the retroperitoneal space - Joseph Nassif (France)	Page 70
NOTES: Current animal and clinical applications state of the ART – Silvana Perretta (France)	Page 81
Role of NOTES in the gynaecological surgical palette possible clinical application in gyneco – Joseph Nassif (France)	Page 108
Upcoming ESHRE activities	Page 115
Notes	Page 117



ESHRE – European Society of Human Reproduction and Embryology

What is ESHRE?

ESHRE was founded in 1985 and its **Mission Statement** is to:

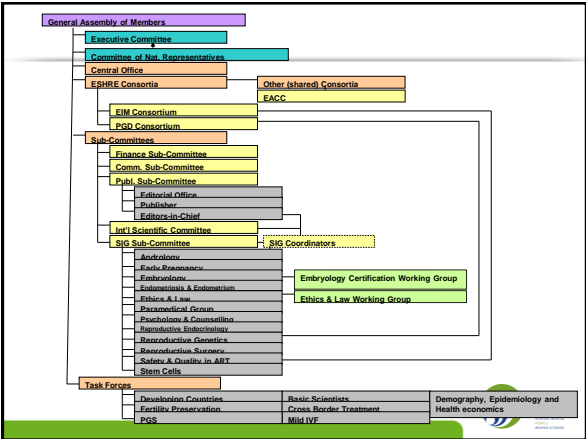
- promote interest in, and understanding of, reproductive science and medicine.
- facilitate research and dissemination of research findings in human reproduction and embryology to the general public, scientists, clinicians and patient associations.
- inform politicians and policy makers in Europe.
- promote improvements in clinical practice through educational activities
- develop and maintain data registries
- implement methods to improve safety and quality assurance



Executive Committee 2009/2011

Chairman	• Luca Gianaroli	Italy
Chairman Elect	• Anna Veiga	Spain
Past Chairman	• Joep Geraedts	Netherlands
	• Jean François Guérin	France
	• Timur Gürgan	Turkey
	• Ursula Eichenlaub-Ritter	Germany
	• Antonis Makrigiannakis	Greece
	• Miodrag Stojkovic	Serbia
	• Anne-Maria Suikkari	Finland
	• Carlos Plancha	Portugal
	• Françoise Shenfield	United Kingdom
	• Etienne Van den Abbeel	Belgium
	• Heidi Van Ranst	Belgium
	• Veljko Vlaisavljevic	Slovenia
	• Søren Ziebe	Denmark





ESHRE Activities – Annual Meeting

- One of the most important events in reproductive science and medicine
- Steady increase in terms of attendance and of scientific recognition

Track record:

ESHRE 2008 – Barcelona: 7559 participants
ESHRE 2009 – Amsterdam: 8132 participants

Future meetings:

ESHRE 2010 – Rome, 27-30 June 2010
ESHRE 2011 – Stockholm, 3-6 July 2011



ESHRE Activities – Scientific Journals

Human Reproduction with impact factor 3.773



Human Reproduction Update with impact factor 7.590



Molecular Human Reproduction with impact factor 2.537



ESHRE Activities – Campus and Data Collection

- Educational Activities / Workshops
 - Meetings on dedicated topics are organised across Europe
 - Organised by the Special Interest Groups
 - Visit: www.eshre.eu under CALENDAR
- Data collection and monitoring
 - EIM data collection
 - PGD data collection
 - Cross border reproductive care survey



ESHRE Activities - Other

- Embryology Certification
- Guidelines & position papers
- News magazine "Focus on Reproduction"
- Web services:
 - RSS feeds for news in reproductive medicine / science
 - Find a member
 - ESHRE Community



ESHRE Membership (1/3)

- ESHRE represents over 5,300 members (infertility specialists, embryologists, geneticists, stem cell scientists, developmental biologists, technicians and nurses)
- Overall, the membership is distributed over 114 different countries, with 50% of members from Europe (EU). 11% come from the US, India and Australia.



ESHRE Membership (2/3)

	1 yr	3 yrs
Ordinary Member	€ 60	€ 180
Paramedical Member*	€ 30	€ 90
Student Member**	€ 30	N.A.

*Paramedical membership applies to support personnel working in a routine environment such as nurses and lab technicians.
**Student membership applies to undergraduate, graduate and medical students, residents and post-doctoral research trainees.



ESHRE Membership – Benefits (3/3)

- 1) Reduced registration fees for all ESHRE activities:
- | | | | |
|----------------|-----------------------|-------|---------|
| Annual Meeting | Ordinary | € 480 | (€ 720) |
| | Students/Paramedicals | € 240 | (€ 360) |
| Workshops | All members | € 150 | (€ 200) |
- 2) Reduced subscription fees to all ESHRE journals – e.g. for Human Reproduction €191 (€ 573!)
- 3) ESHRE monthly e-newsletter
- 4) News Magazine “Focus on Reproduction” (3 issues p. a.)
- 5) Active participation in the Society’s policy-making



Special Interest Groups (SIGs)

The SIGs reflect the scientific interests of the Society’s membership and bring together members of the Society in sub-fields of common interest

- | | |
|-----------------------------|----------------------------|
| Andrology | Psychology & Counselling |
| Early Pregnancy | Reproductive Genetics |
| Embryology | Reproductive Surgery |
| Endometriosis / Endometrium | Stem Cells |
| Ethics & Law | Reproductive Endocrinology |
| Safety & Quality in ART | |



Task Forces

A task force is a unit established to work on a single defined task / activity

- Fertility Preservation in Severe Diseases
- Developing Countries and Infertility
- Cross Border Reproductive Care
- Reproduction and Society
- Basic Reproductive Science
- Fertility and Viral Diseases
- Management of Infertility Units
- PGS
- EU Tissues and Cells Directive



Annual Meeting

Rome, Italy 27 June to 30 June 2010



Pre-congress courses (27 June):

- PCC 1: Cross-border reproductive care: information and reflection
- PCC 2: From gametes to embryo: genetics and developmental biology
- PCC 3: New developments in the diagnosis and management of early pregnancy complications
- PCC 4: Basic course on environment and human male reproduction
- PCC 5: The lost art of ovulation induction
- PCC 6: Endometriosis: How new technologies may help
- PCC 7: NOTES and single access surgery
- PCC 8: Stem cells in reproductive medicine
- PCC 9: Current developments and their impact on counselling
- PCC 10: Patient-centred fertility care
- PCC 11: Fertility preservation in cancer disease
- PCC 12: ESHRE journals course for authors



Annual Meeting – Scientific Programme (1/2)

Rome, Italy 27 June to 30 June 2010



- Molecular timing in reproduction
- Rise and decline of the male
- Pluripotency
- Preventing maternal death
- Use and abuse of sperm in ART
- Live surgery
- Emerging technologies in the ART laboratory
- Debate: *Multiple natural cycle IVF versus single stimulated cycle and freezing*



Annual Meeting – Scientific Programme (2/2)

- Fertility preservation
- Congenital malformations
- ESHRE guidelines
- Data from the PGD Consortium
- European IVF Monitoring 2007
- Debate: *Selection of male/female gametes*
- Third party reproduction in the United States
- Debate: *Alternative Medicine, patients feeling in control?*
- Historical lecture: "Catholicism and human reproduction"



Certificate of attendance

- 1/ Please fill out the evaluation form during the campus
- 2/ After the campus you can retrieve your certificate of attendance at www.eshre.eu
- 3/ You need to enter the results of the evaluation form online
- 4/ Once the results are entered, you can print the certificate of attendance from the ESHRE website
- 5/ After the campus you will receive an email from ESHRE with the instructions
- 6/ You will have TWO WEEKS to print your certificate of attendance



Contact



ESHRE Central Office
Meerstraat 60, 1852 Grimbergen, Belgium
Tel: +32 (0)2 269 09 69
Fax: +32 (0)2 269 56 00
E-mail: info@eshre.eu
www.eshre.eu



PRE-CONGRESS COURSE 7 - Programme

NOTES and single access surgery

Organised by the Special Interest Group Reproductive Surgery

Course coordinators: Marco Gergolet (Italy), Vassilios Tanos (Cyprus), Rudi Campo (Belgium), Stephan Gordts (Belgium)

Course description: New endoscopic techniques and new flexible endoscopes developed by all the companies involved in endoscopic surgery offers wide clinical approaches in single access surgery, using natural orifice as entry port. The course is focused on the wide panel of endoscopic procedures in infertility treatment using this new, minimally invasive, approach to abdominal cavity.

Target audience: Specialist gynaecologist, particularly those, involving in reproductive and endoscopic surgery

Scientific programme:

09:00 – 09:30	Natural orifice transluminal endoscopic surgery: history and present – Marcus Dantas (Brazil)
09:30 – 09:45	Discussion
09:45 – 10:15	NOTES and the exploration of the female pelvis - Patrick Puttemans (Belgium)
10:15 – 10:30	Discussion
10:30 – 11:00	Coffee break
11:00 – 11:30	Single access surgery and development of new instruments - Joseph Nassif (France)
11:30 – 11:45	Discussion
11:45 – 12:15	Single access surgery and the uterine cavity, called hysteroscopy - Milan Reljic (Slovenia)
12:15 – 12:30	Discussion
12:30 – 13:30	Lunch
13:30 – 13:50	NOTES and the exploration of the retroperitoneal space - Joseph Nassif (France)
13:50 – 14:00	Discussion
14:00 – 14:20	NOTES: Current animal and clinical applications state of the ART – Silvana Perretta (France)
14:20 – 14:30	Discussion
14:30 – 14:50	Consensus statement on NOTES and single access laparoscopic surgery – Liliana Mereu (Italy)
14:50 – 15:00	Discussion
15:00 – 15:30	Coffee break
15:30 – 16:00	Operative possibilities of the transvaginal endoscopic access: only a gimmick? – Silvana Perretta (France)
16:00 – 16:15	Discussion

- 16:15 – 16:45 Role of NOTES in the gynaecological surgical palette possible clinical application in gyneco – **Joseph Nassif (France)**
- 16:45 – 17:15 NOTES: is it an evolution or revolution in minimal invasive surgery? Conclusion – Round table: **J. Nassif, R. Campo, S. Perretta, St. Gordts**
- 17:15 – 17:30 Discussion and closing remarks - **M. Gergolet (Italy)**

NOTES

History and Present: Where are we?

Marcus Dantas Martins

Professor of Surgery, Estacio de Sá University
Chairman Department of Surgery, Lourenço Jorge Hospital

Disclosure: EDLO S.A. PRODUTOS MÉDICOS
- Consultant for new technologies and products

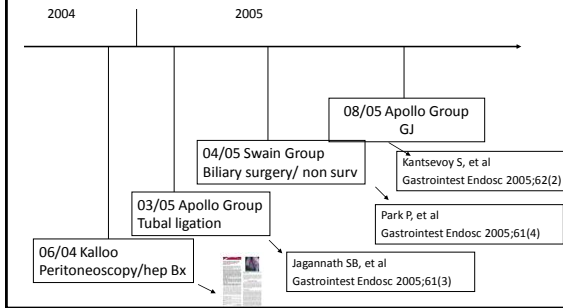
What's NOTES ?

- N – Natural
- O - Orifices
- T - Transluminal
- E - Endoscopic
- S - Surgery

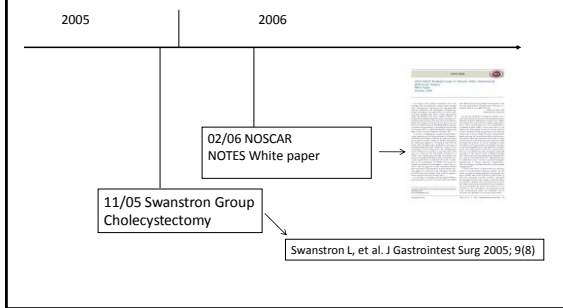
Rationale for NOTES

- Less is Better
 - Less manipulation
 - Less operative stress(TNF, IL6, C-reactive protein)
 - Less suppression of immune response
- No incisions
 - smaller abdominal wall incisions are better. Could zero abdominal incision be best?
- Evolution of endoscopic therapy ?

HISTORY



HISTÓRICO



NOSCAR

National Orifice Surgery
Consortium for Assessment
And Research



Fundamental Challenges to The Safe Development of NOTES

- Safe Access to the peritoneal cavity
- Secure closure of gastric incision
- Prevention of infection
- Development of suturing device
- Spatial orientation
- Multitasking platform to accomplish procedures

Fundamental Challenges to The Safe Development of NOTES

- Control of hemorrhage
- Manage of complications
- Physiologic untoward events
- Compression syndromes
- Training issues

First Human Appendectomy

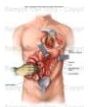- GV Rao
 - Asian Institute of Gastroenterology, India
 - 7 cases from feb 2003 to aug 2005
 - Transgastric approach
 - Presented at SAGES 2006

NOTES

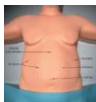- NOTES
 - Transgastric
 - Transcolonic
 - Transvesical
 - Transvaginal
 - Transumbilical

First Transvaginal Cholecystectomy

- March 13rd, 2007. Zorron R. Brazil
- Marh 20th, 2007. Marc Bessler. Columbia University, US
- April 2nd, 2007. Marescaux J. Strasbourg, Fr.



Laparotomy

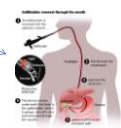

Laparoscopy

- Problems:
- Infection
 - New platforms
 - New instruments
 - Spatial orientation
 - Visceral Closure
 - Sterelization

SITRACC

NOTES



Many names, One thing

- SITRACC – Single Trocar Access
- SPA – Single Port Access
- TUES – Transumbilical Endoscopic Surgery
- NOTUS – Natural Orifice Transumbilical Surgery
- E-NOTES – Embriologic NOTES
- SILS – Single Incision Laparoscopic Surgery
- SAS – Single Access Surgery
- LESS – Laparoendoscopic Single-Site

NOSCAR
National Orifice Surgery
Consortium for Assessment
And Research
Jul 2005



LESSCAR
Laparosendoscopic Single-Site Surgery
Consortium for Assessment and Research
Jul 2008



Advantages

- Less invasive?
- Similar of laparoscopy
- No contamination
- Hybrid techniques
- Step for development of new technology ?

How Can We Operate From a Single Site ?

- Modified Trocars
 - One Trocar with multiple ports
- Modified Laparoscopic Instruments
 - Articulated instruments
- Modified Laparoscopes
 - Longer, thinner and camera and light as a same unit
- Modified Techniques
 - No triangulation

Our Experience

- Jun 2006
 - Transgastric surgery in Pigs
 - Spatial orientation and hepatic biopsies
 - First brazilian publication on NOTES



SITRACC PROJECT



Partnership:



X



Development

Umbilical e Vaginal Instruments

Multidisciplinary Team

PICTURE 1

First Generation Instruments

PICTURE 2

Research Project



From Dez 2007 to Mar 2008

- . 10 Sitracc Cholecystectomies in Pigs
- . Operative Time: 40 -150 minutos



Second Generation Instruments

PICTURE 3

Second Generation Instruments

PICTURES 4,5 6,7

Second Generation Trocar

PICTURES 8,9,10

MOVIE 1

— **Una News**
Colocinetronica videodisegnistica per trovare amici CDRAC®
— Una news inglese
Capomonte: indispensabile per single minor attenti CDRAC® — A new option
 Milano (Italia) 20/01/91 di Lando Padellaro, T.02 - 87.11.661 (telex), T.02 - 492.190 (fax) (Borsa Italiana Capital)

S T I L O

Stilo, la nuova rivista per giovani professionisti, è una rivista di consulenza e informazione. **Stilo** è la rivista di riferimento per tutti i giovani professionisti che vogliono migliorare la loro immagine e la loro performance. **Stilo** è la rivista di riferimento per tutti i giovani professionisti che vogliono migliorare la loro immagine e la loro performance. **Stilo** è la rivista di riferimento per tutti i giovani professionisti che vogliono migliorare la loro immagine e la loro performance.

Stilo, la nuova rivista per giovani professionisti, è una rivista di consulenza e informazione. **Stilo** è la rivista di riferimento per tutti i giovani professionisti che vogliono migliorare la loro immagine e la loro performance.

introduzione

Nel corso del 1987, dopo aver letto della **Business Intelligence**, ho deciso di creare una rivista che potesse essere di aiuto a tutti i giovani professionisti che volevano migliorare la loro immagine e la loro performance. **Stilo** è la rivista di riferimento per tutti i giovani professionisti che vogliono migliorare la loro immagine e la loro performance.

La rivista, che sarà pubblicata in formato elettronico, è una rivista di consulenza e informazione. **Stilo** è la rivista di riferimento per tutti i giovani professionisti che vogliono migliorare la loro immagine e la loro performance.

A Capomonte: indispensabile per single minor attenti CDRAC®
 Capomonte è la rivista di riferimento per tutti i giovani professionisti che vogliono migliorare la loro immagine e la loro performance.

Capomonte è la rivista di riferimento per tutti i giovani professionisti che vogliono migliorare la loro immagine e la loro performance.

La rivista, che sarà pubblicata in formato elettronico, è una rivista di consulenza e informazione. **Stilo** è la rivista di riferimento per tutti i giovani professionisti che vogliono migliorare la loro immagine e la loro performance.

Capomonte è la rivista di riferimento per tutti i giovani professionisti che vogliono migliorare la loro immagine e la loro performance.

Capomonte è la rivista di riferimento per tutti i giovani professionisti che vogliono migliorare la loro immagine e la loro performance.

86 - 01/91 - 86/87 - 86/88

NEXT STEP

Multicentric Study

- 10 Brazilian Surgeons
- Training (animal facilities) on october 2008
- IRB approval
- Surgeries from jan 2009 to april 2009



SITRACC
Small Intestine Transcatheter Access

-
-
-
-
-
-

-
-
-
-
-
-

-
-
-
-
-
-

SITRACC

- Safe
- Effective
- Better?
 - More difficult(no triangulation)
 - Pain
 - Recovery
 - Inflammatory response
 - Cosmesis

Single Ports

PICTURE 11

Single Ports

	Company	Ports	Skin Incision
SITRACC	Edlo	4	2,5-3cm
SILS	Covidien	3	2-2,5cm
GelPort	Applied	Up to 4	3cm
X-Cone/Endocone	Karl Storz	3-6	2,5-3,5cm
TriPort/QuadPort	Olympus*	3-4	2cm
SSL	Ethicon	3	2,5cm
AirSeal	Surgiquest	-	

* Advanced Surgical Concepts

Single Ports

PICTURES 12-17

Conclusions

Laparoscopy

Minilaparoscopy

Reduced Ports

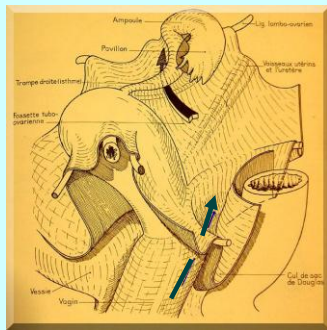
SITRACC

NOTES

We need a ergonomic, cost-effective
and easily reproducible technique.
This technique should offer advantages
over the traditional laparoscopy.

NOTES & the exploration of the female pelvis

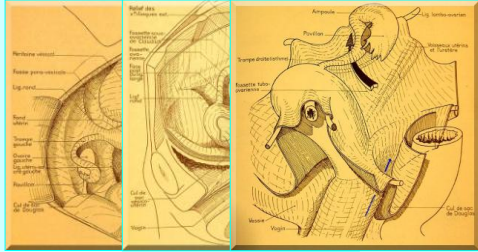
Patrick Puttemans
PCC ESHRE - Roma 2010



Terminology

- THL = transvaginal hydrolaparoscopy
- TVE = transvaginal endoscopy
 - including hysteroscopy, salpingoscopy, ovarioscopy
 - including operative TVE, a first application of NOTES = Natural Orifice Transluminal Endoscopic Surgery

Same anatomy Reversed topography

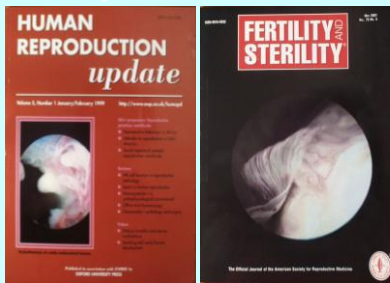


29/05/2010

www.life-science

4

TVE Watery distension medium



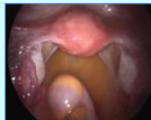29/05/2010

www.life-science

5

Conventional Laparoscopy

- Offers a panoramic view
- Possibility of surgical treatment
- Inconvenient access
- Inconvenient distension medium
- Invasive procedure under general anaesthesia
- High threshold - frequently postponed

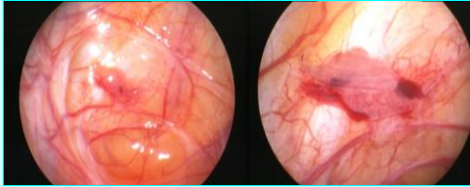


29/05/2010

www.life-science

6

TVE versus laparoscopy

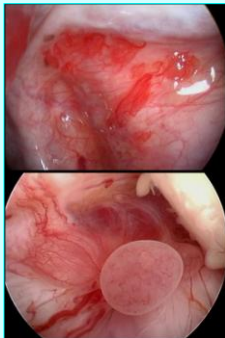


- hydro-floatation of tissues/organs
- closer vision // higher zoom factor

29/05/2010

www.life-science

7



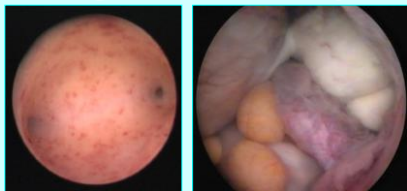
29/05/2010

www.life-science

8

TVE

Rigid mini-endoscopes

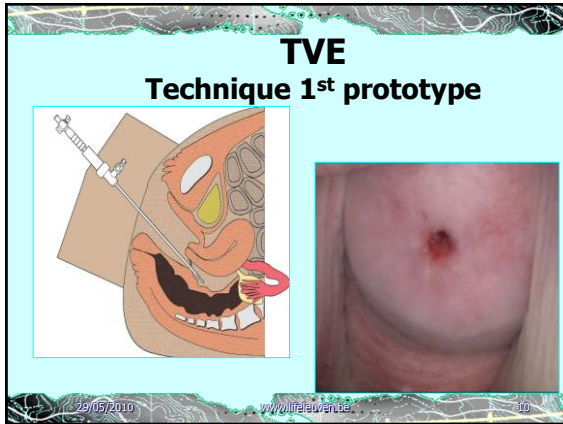



Rigid scope, Hopkins rod lenses, 30°, 2.9 mm ø

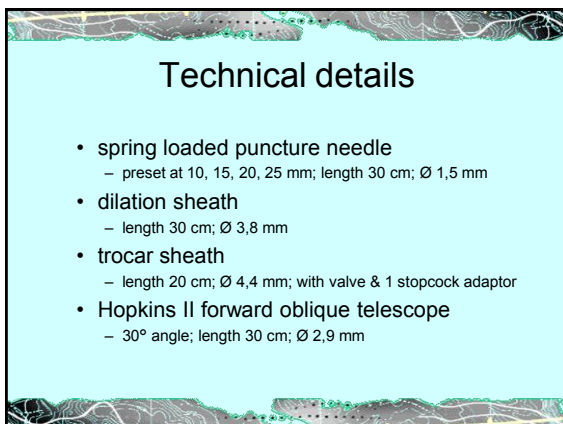
29/05/2010

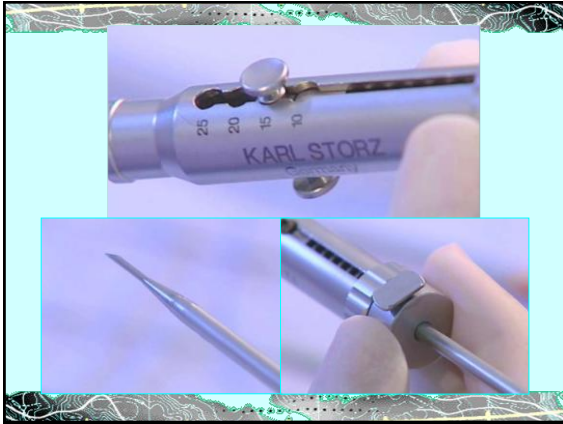www.life-science

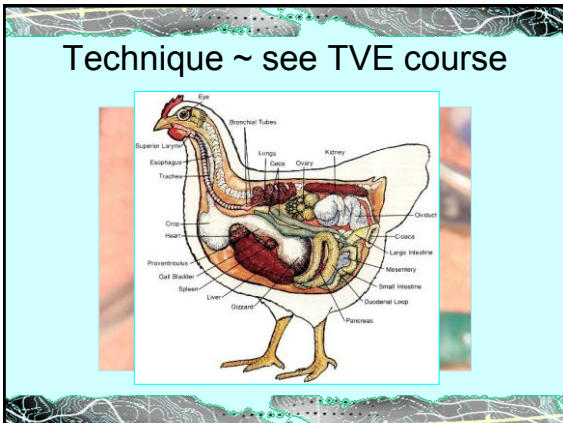
9











Technique ~ see TVE course

TVE versus conventional laparoscopy

- The transvaginal approach allows **easy and direct access to the tubo-ovarian structures**, including the fossa ovarica and the posterior surface of the ovary **without additional manipulation**.
- In the **absence of a panoramic view**, one needs to be **systematic** during the exploration of the pelvis:
 - follow the posterior side of the uterus ~ ovarian ligament
 - inspect the ovary, its fossa and the tube carefully
 - inspect the fimbrial end & perform a SSC/MBT
 - don't forget to inspect the Douglas & uterosacral ligts!

30/05/2010 www.life4u.ch 20

Transvaginal Endoscopy

Complete endoscopic investigation of the entire* female reproductive tract in a One Stop Fertility Clinic:

Mini-hysteroscopy (HSC) & TvUS & Contrastsono

Transvaginal HydroLaparoscopy (THL)

Salpingoscopy (SSC)

Patency or dye test (MBT)

(*except for the intramural and isthmic part of the Fallopian tube)

29/05/2010

www.life-fertility.co.uk

721

Minihysteroscopy

- No speculum
- No tenaculum
- No cervical dilatation
- No anaesthesia or analgesia
- Atraumatic and sight controlled insertion of the 2.0 or 2.9 mm hysteroscope

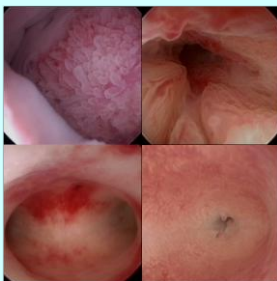


29/05/2010

www.life-fertility.co.uk

722

Mini-hysteroscopy

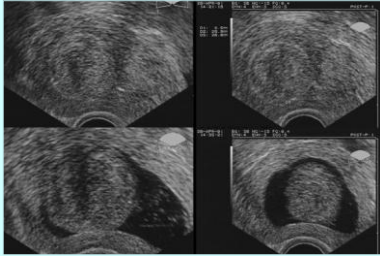


29/05/2010

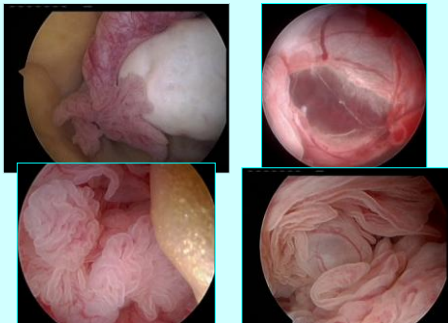
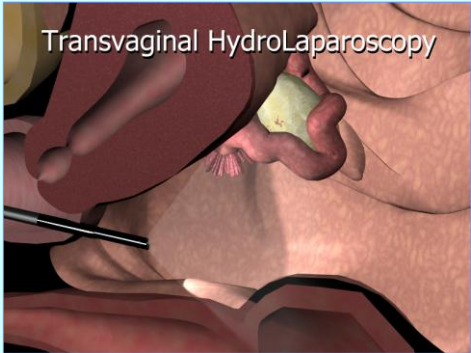www.life-fertility.co.uk

723

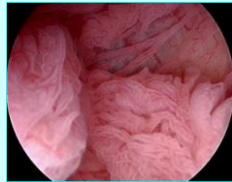
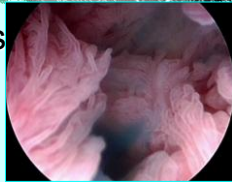
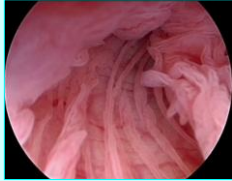... combined with vaginal
ultrasound & hydrosalpingography



Transvaginal HydroLaparoscopy



Salpingos

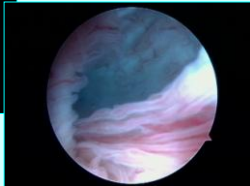
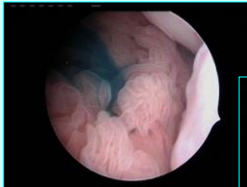

29/05/2010

www.lifebalance.ch

29

Dye test



29/05/2010

www.lifebalance.ch

29

TVE

Patient comfort & compliance

Patients can choose between:

- local anaesthesia - office or OR
- conscious sedation - office (cf. OPU) or OR
- general anaesthesia - only OR
- purely diagnostic procedure incl. biopsies
- operative TVE if necessary, now or later
- conventional operative LSC, now or later

29/05/2010

www.lifebalance.ch

29

TVE

Procedure sequence

1. Clinical examination !

2. Vaginal ultrasound !

3. Mini-hysteroscopy (no speculum or Pozzi!)

4. Saline infusion sonography (SIS)

5. Transvaginal hydrolaparoscopy

6. Salpingoscopy, if possible

7. Tubal patency test (8 Fr balloon catheter)

8. (Endometrial biopsy (pipelle de Cornier))

29/05/2010

www.life4u.ch

30

TVE

Indications

☐ Infertile patients without obvious pathology

☐ Second look after surgery or drug treatment

☐ Surveillance of endometriosis

☐ (Exploration of tubal and ovarian physiology)

☐ (Conscious pain mapping)

☐ (Early diagnosis of ectopic pregnancy)

29/05/2010

www.life4u.ch

31

TVE

Contra-indications

☐ Acute or subacute PID

☐ A fixed retroverted uterus

☐ Extreme obesity

☐ Virgo, narrow vagina

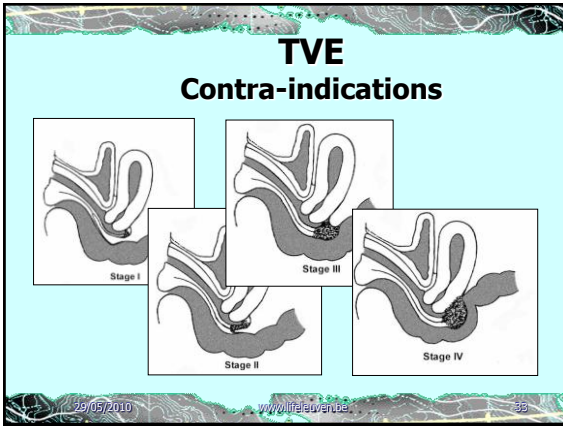
☐ History of (intestinal or) pelvic surgery

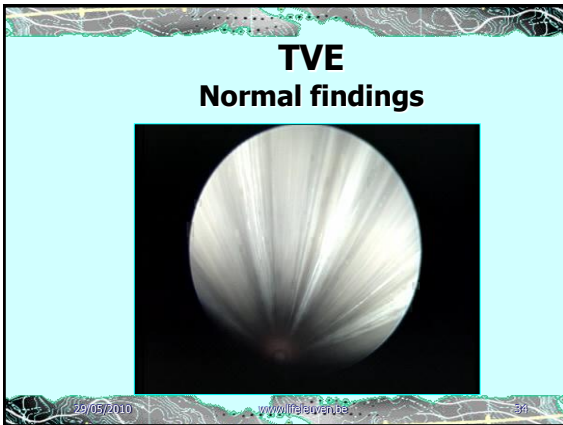☐ Suspected pathology in the posterior fornix

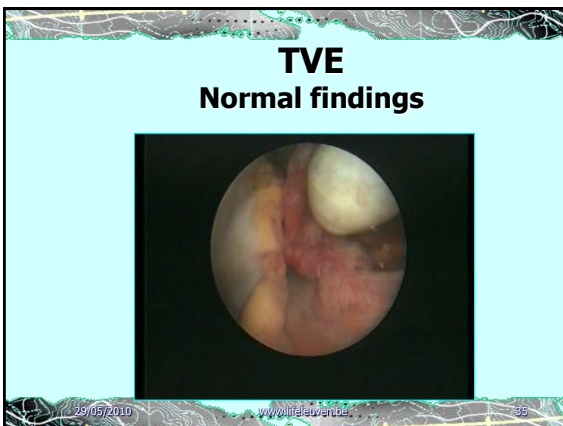
29/05/2010

www.life4u.ch

32







TVE easily detects subtle or incipient lesions

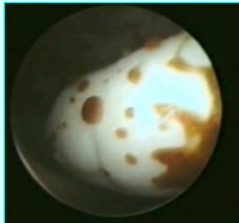
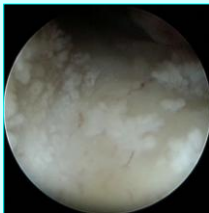
- ❑ These subtle or incipient lesions can be the cause of or at least be associated with the infertility.
- ❑ Is "unexplained infertility" being caused by these subtle lesions, undetected by standard LSC ?

29/05/2010

www.reference

36

Subtle lesions

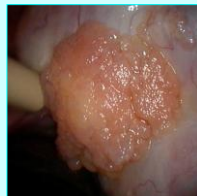
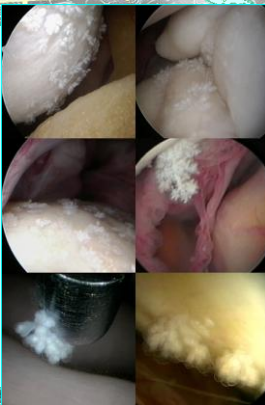
29/05/2010

www.reference

37

Benign surface papilloma

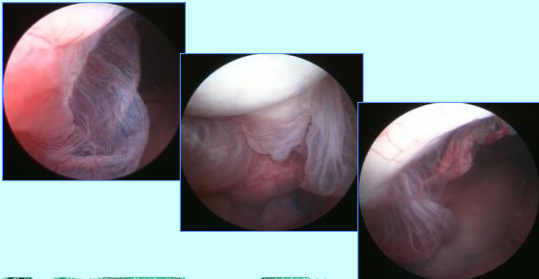


29/05/2010

www.reference

38

Free floating adhesions

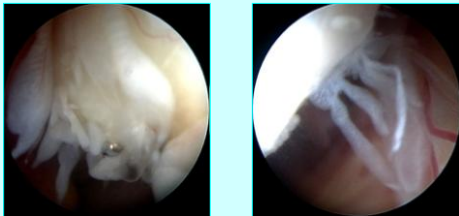


29/05/2010

www.lifeenrich.be

39

Free floating adhesions

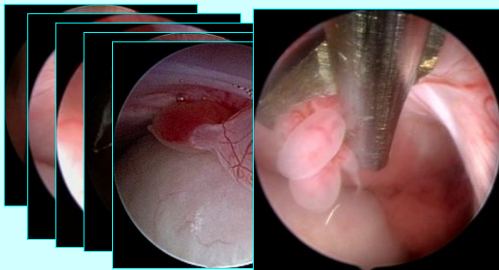


29/05/2010

www.lifeenrich.be

40

Subtle endometriotic lesions (peritoneal)

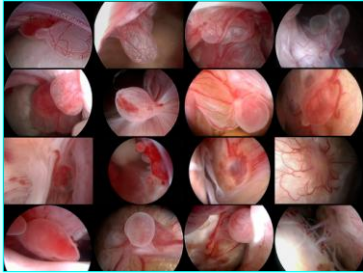

29/05/2010

www.lifeenrich.be

41

Active peritoneal endometriosis

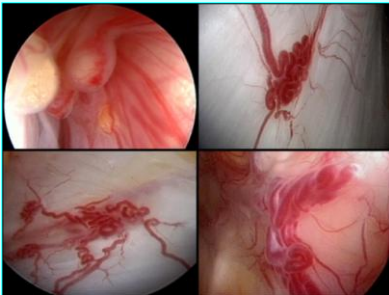


29/05/2010

www.reference

745

Active peritoneal endometriosis

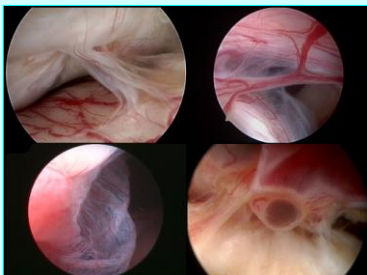


29/05/2010

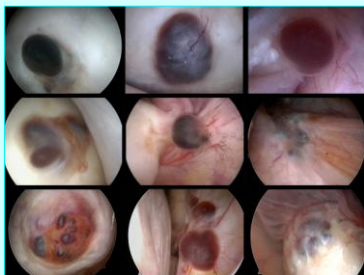www.reference

746

Endometriotic adhesions



Typical yet inactive peritoneal endometriosis



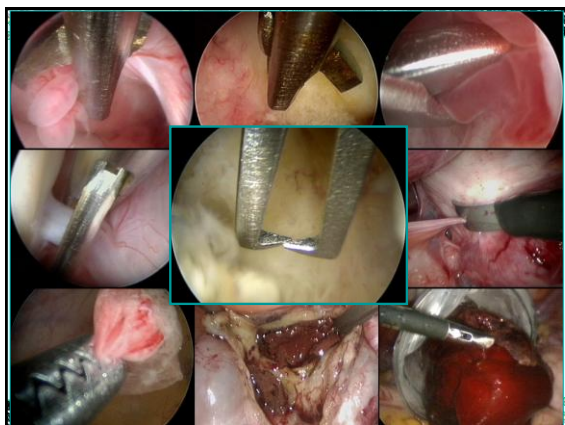
29/05/2010

www.reference

745

Operative THL

NOTES
with
mechanical & bipolar energy

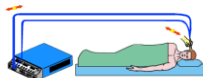


Bipolar electrosurgery

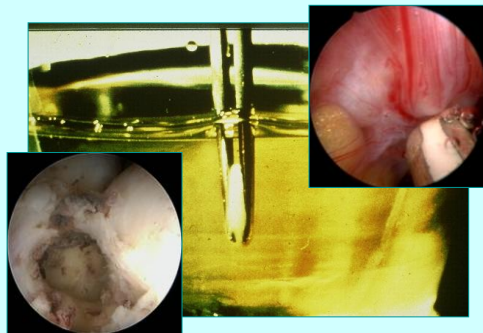
- here the circuit is confined within an instrument using two adjacent poles - one positive and one negative electrode - located in close proximity to one another; current flow is restricted between the two poles and the tissue it holds
- the surgical effect is mainly coagulating and hemostatic (lower voltages, no carbonisation)
- electrical current only flows between the 2 electrodes and the tissue in between; there is no electrical current going deeper inside the patient's body = safer +++
- a patient plate or passive electrode is not necessary
- the low voltages make it less effective on large bleeders

Bipolar electrosurgery

play animation

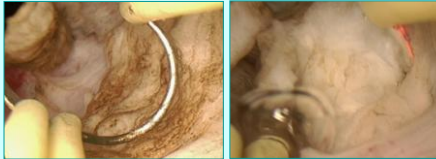

Can be used under water!
~ operative hysteroscopy
& operative THL in/with
saline (isotonic lactated
Ringer's & Hartmann's
solution)

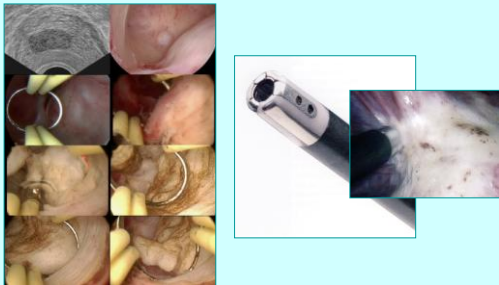

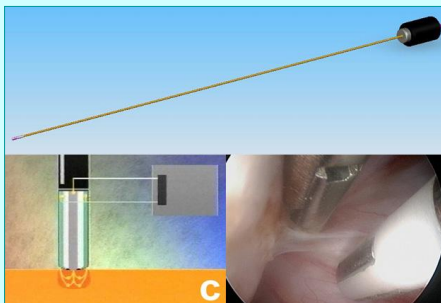
Bipolar cutting

- uses higher voltages in a so-called 'macrobipolar' modus
- this bipolar wave form allows to cut, even under water
- its use is safer than unipolar cutting
- has a more limited depth penetration and thermal spread compared to monopolar current

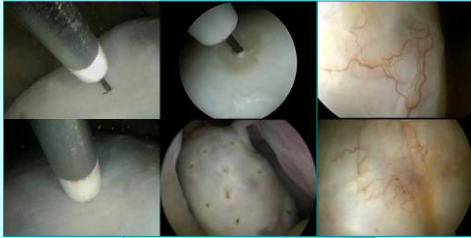


Modern bipolar electrodes





Modern bipolar electrodes



The small endometrioma

Endometrioma, excisional surgery & fertility: what is the evidence ?

- Laparoscopic cystectomy is an invasive treatment in that it reduces the frequency of spontaneous ovulation; **however the pregnancy rate per ovulation does not deteriorate**
- In IVF a higher amount of FSH is needed to achieve an acceptable outcome, **although implantation, pregnancy, and delivery rates are similar**, suggesting that embryo quality remains unaffected despite diminished ovarian reserve
- prospective RCT of Demirol et al. (2006): ovarian surgery resulted in longer stimulation, higher FSH requirement and lower oocyte number, **but fertilization, pregnancy and implantation rates did not differ between the groups**

Endometrioma, conservative surgery & fertility: the risk of recurrence

- conservative surgery with adhesiolysis, ovariolysis, fenestration, drainage of its content, rinsing and bipolar coagulation of the inner wall of the chocolate cyst (ablation of the cyst lining)
- the risk of recurrence is especially higher in the larger thick walled (i.e. older) endometrioma, and during controlled ovarian hyperstimulation
- overall increased risk of postop adhesion formation
- beneficial impact of GnRH agonist for 3-6 months on the recurrence rate following conservative laparoscopic surgery

Cochrane review (2005, 2008)

Hart RJ, Hickey M, Maouris P, Buckett W: Excisional surgery versus ablative surgery for ovarian endometriomata

- "excisional laparoscopic surgery provides significantly better results than draining and destruction of the cyst wall with regard to the recurrence rate, both of the endometriotic cyst itself as of its symptoms, but also with regard to the subsequent chance of a spontaneous pregnancy. "

Cochrane review (2005, 2008)

Hart RJ, Hickey M, Maouris P, Buckett W: Excisional surgery versus ablative surgery for ovarian endometriomata

- only 3 RCT's were/could be included
- performed in only 2 centres
- on 245 patients
- not multicentric
- include a potential bias since both patient and surgeon were not blinded as to the type of procedure that was going to be performed

What about functional prognosis ? reproductive potential ?

Growing concern in recent literature with regard to the serious risk of **diminished (endo- & exogenous, spontaneous & stimulated) ovarian reserve up to POF** following laparoscopic cystectomy, not only quantitatively but also qualitatively, due to **extensive and aggressive hemostasis, damaging the blood supply of and towards the affected ovary**

2009

- Busacca M & Vignali M Endometrioma excision and ovarian reserve: a dangerous relation. J Minim Invasive Gynecol
- Chang HJ et al. Impact of laparoscopic cystectomy on ovarian reserve: serial changes of serum anti-Mullerian hormone levels. FS
- Li CZ et al. The impact of electrocoagulation on ovarian reserve after laparoscopic excision of ovarian cysts: a prospective clinical study of 191 patients. FS
 - Conclusion(s): Bipolar electrocoagulation after laparoscopic excision of ovarian cysts is associated with a statistically significant reduction in ovarian reserve (FSH assay, basal antral follicle count, mean ovarian diameter, ovarian stromal blood flow velocity on day 3 of menstrual cycles 1, 3, 6, and 12 after surgery), which is partly a consequence of the damage to the ovarian vascular system
- Tsolakidis et al. The impact on ovarian reserve after laparoscopic ovarian cystectomy versus three-stage conservative management in patients with endometriomas: a prospective randomized study. FS
 - Conclusion(s): Ovarian reserve determined by AMH is less diminished after the 3-step procedure compared with radical cystectomy

The assets of transvaginal hydrolaparoscopy

- A. The exploration
- B. The information
- C. The interpretation
- D. The implication
- E. The operation

A. The exploration

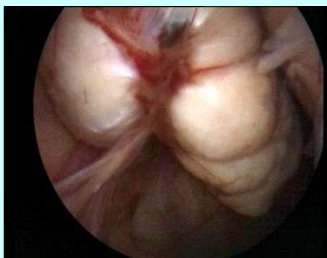- TVE allows for the detection of endometriomas that may be invisible at TVS (<10-12 mm)
- hydrolaparoscopy offers the ideal inclination angle to explore the ovarian fossa
- i.e. the predilection site for the development of an endometrioma
- highly suspicious in the presence of adhesions and/or an area of fibrotic retraction
- visual information + surgical exploration with mini scissors = the best guarantee for the detection of even the smallest endometriomas

564 consecutive infertile women, 169 of whom show endometriosis at TVE

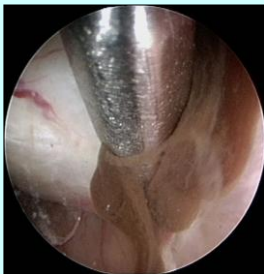
Detection of small endometriomas at TVS & TVE in 169 patients with endometriosis (15-16% of all TVE)

size	TVS +	TVE +	TVS sensitivity
≤ 15 mm	5	11	45 %
> 15 mm	11	11	100 %
total	16	22	16/22 (73%)

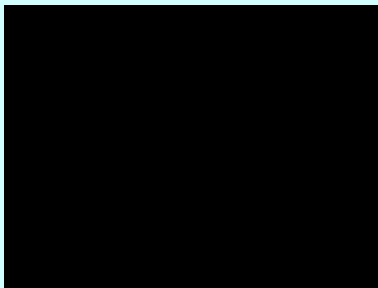
fibrosis & capsule retraction



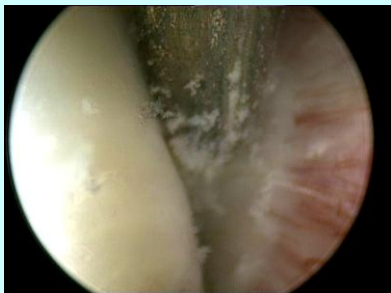surgical exploration



surgical exploration



surgical exploration



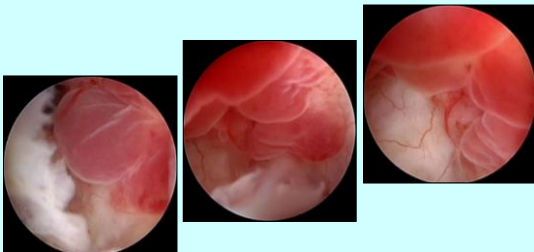
B. The information

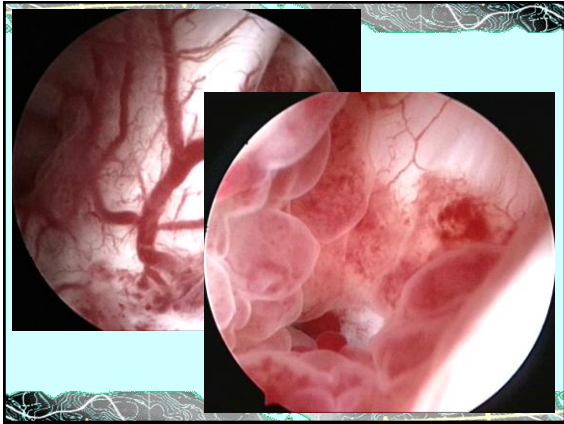
- red, flame like, active, superficially spreading, peritoneal-like endometriotic implants on the borders and at the inside
- can easily be peeled off (like a decidual cast inside the uterine cavity) and
- sent to pathology, that will name it well differentiated endometriotic implants
- in contrast with pearl-white surface that contains oogonia, i.e. inverted cortex

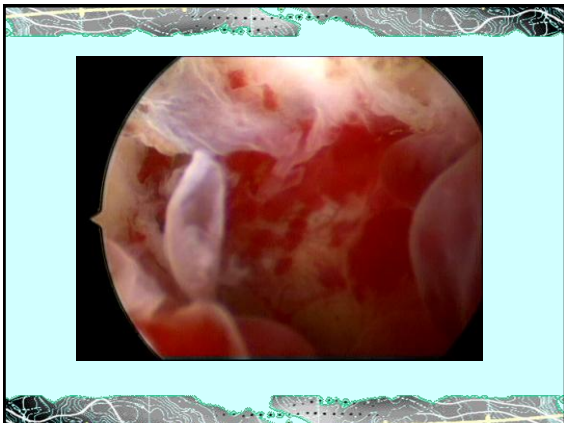
Muzii et al., Fertil Steril 2007

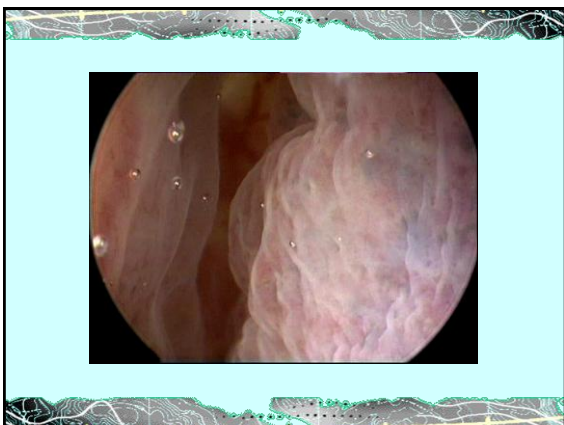
- 70 endometriotic cysts were examined
- following stripping technique and excision
- its endometriotic nature was confirmed in 100%
- the inner wall of the endometrioma was covered by endometriotic tissue on an average of 60% of the surface (between 10% and 98%)
- the mean cyst wall thickness was 1.4 mm
- the maximal depth of wall penetration was 0.6 mm
- in 99% of cases the maximal penetration of the endometriotic tissue into the wall was <1.5 mm
- maximum depth penetration: 2 mm

active lesions





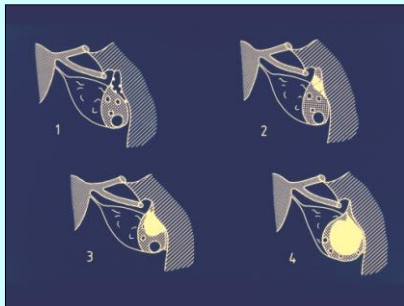




C. The interpretation

- The endometrioma is a pseudocyst
 - chronic shedding and bleeding of active peritoneal implants in the ovarian fossa cause
 - adherence of the ovary to the pelvic sidewall &
 - progressive invagination (folding inwards) of the ovarian cortex together with
 - superficially spreading implants on the inside
 - if this is true, an endometrioma would be a pseudocyst (false cyst), the wall of which is actually the inverted ovarian cortex;
 - hence the removal of this cyst wall might involve removal of normal ovarian tissue, with possible adverse implications for future fertility (Vercellini 2003)

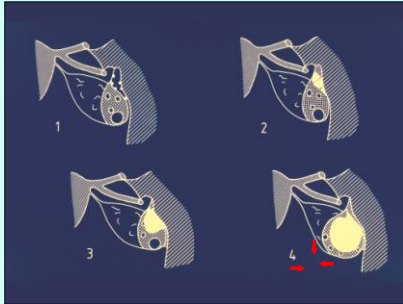
C. The interpretation



C. The interpretation

- Factors contributing to the growth of the endometrioma:
 - shedding/bleeding of peritoneal implants
 - important fibrosis at the hilus of the ovary with repeated bleeding of venules
 - ovulation towards and hemorrhagic cystic corpus luteum formation inside the endometrioma

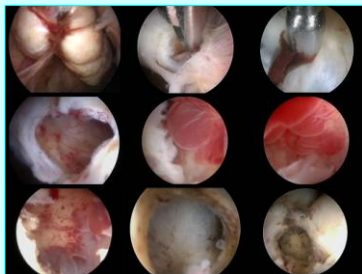C. The interpretation



D. The implication

- we can't make a distinction between the small endometrioma with a good prognosis and the one that will continue to grow towards the more destructive stages of the disease;
- so we need to focus on the early detection of the small endometrioma in the young female patient (TVS, MRI, CA-125, TVE);
- and treat it when surgery is feasible & efficient, with distinct cleavage planes, minimal fibrosis and implants that can easily be recognized;
- ~ maximal preservation of healthy ovarian tissue, i.e. functional prognosis (↓ postop adhesion formation, ↓ functional cyst formation) and reproductive potential of the affected ovary

E. The operation

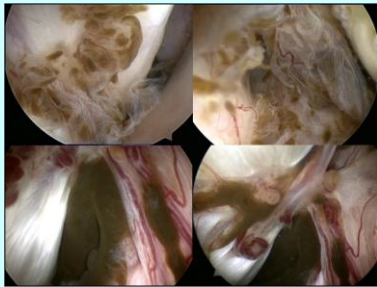


... and its limitations

$$V = \frac{4}{3}\pi r^3$$

diameter (cm)	radius (cm)	volume (cm³)
1	0,5	0,52
2	1	4,18
3	1,5	14,13
4	2	33,49

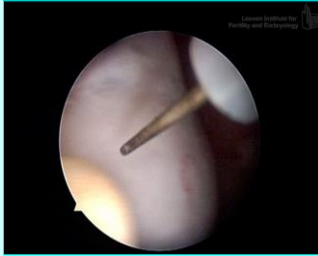... chocolate spill harmless?



PCOS and
ovarian capsule drilling

NOTES

Ovarian capsule drilling in PCOS with bipolar needle

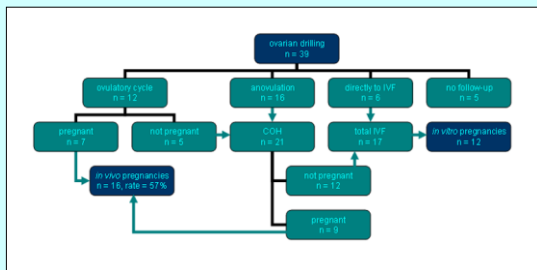


29/05/2010

www.lifebalance

187

Results bipolar drilling via TVE



Single access surgery and development of new instruments

Joseph NASSIF, MD*
Arnaud WATTIEZ, MD*

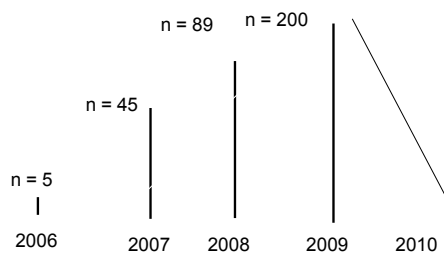
* IRCAD/EITS, Strasbourg, France

26th Annual Meeting
ESHRE – ROME 2010

Disclosure Slide

- We declare that we have no conflict of interest and no commercial relationship with any product that may be cited in the current presentation

Publications on Pubmed



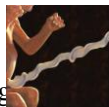

SILS

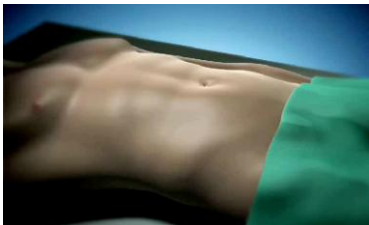


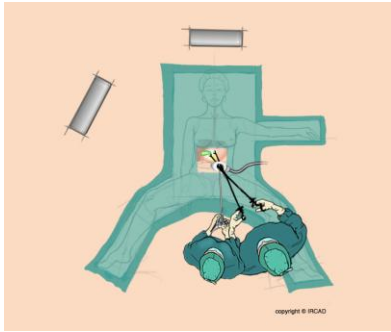
SPA single port access

TUES transumbilical endoscopic surg

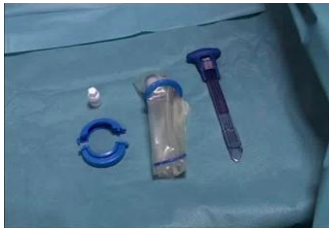

NOTUS Natural Orifice Trans Umbilical
Surgery

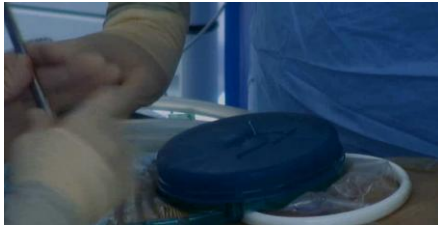

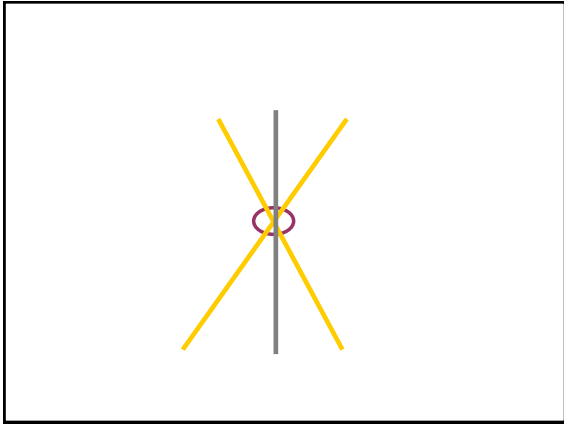


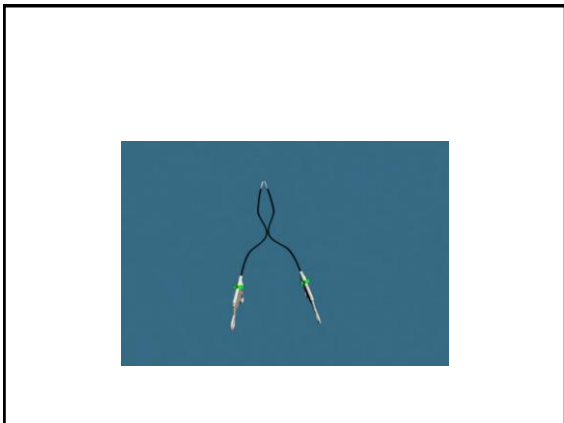
Triport

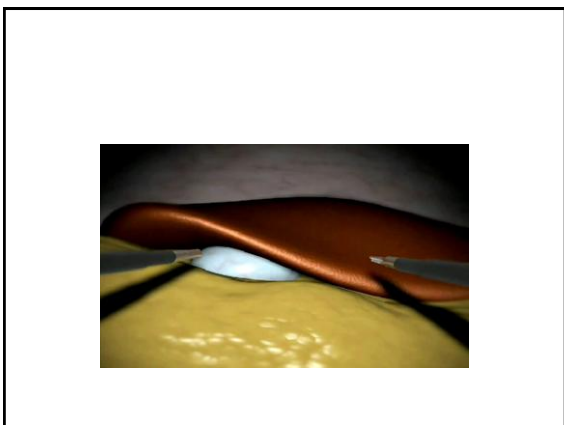


Gelport

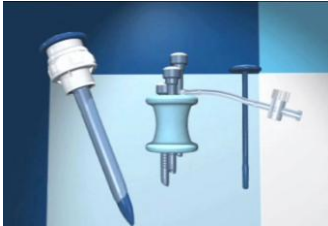


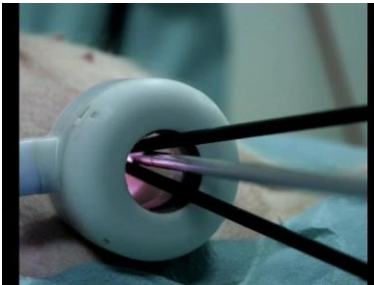





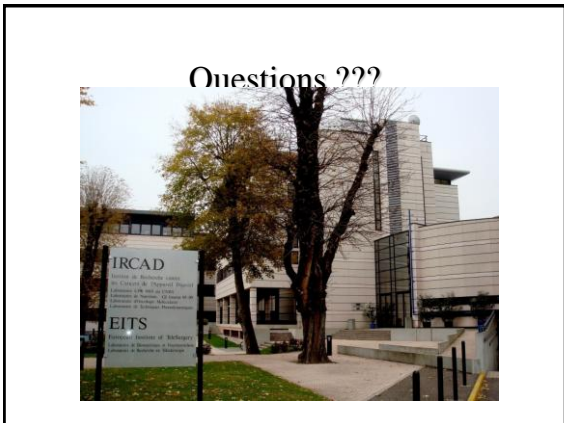SILS COVIDIEN











Single access surgery and the uterine cavity, called hysteroscopy

Milan Reljič, MD, PhD
Prof in Obstetrics & Gynaecology

Department for Reproductive Medicine and Gynecologic
Endocrinology, UKC Maribor, SLOVENIA

Overview

Hysteroscopy in infertility evaluation

- accuracy of diagnostic hysteroscopy
- effectiveness of operative hysteroscopy in improving fertility and pregnancy rates
- outpatient hysteroscopy in infertility evaluation

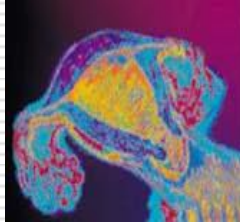
Uterine abnormalities

□ Infertility related to uterine cavity abnormalities has been estimated to be the etiologic factor in as many as 10-15% of couples seeking treatment (Wallach EE, 1972).

□ Abnormal intrauterine findings occur in approximately 34-62% of infertile women (Lindeman et al, 1976, Gallinat A, 1984).

Assessing uterine abnormalities

- 2 D ultrasound
- 3 D ultrasound
- Hysterosalpingography (HSG)
- Hysterosonography (SIS)
- MR
- hysteroscopy



Comparison of hysteroscopy and other methods in the diagnosis of intrauterine lesions in infertile women

	Sensitivity (%)	Specificity (%)	Poz. PV (%)	Neg. PV (%)
Sonography*	91	83	85	90
Hydrosonography*	98	94	95	98
Hysterosalpingography**	81	80	63	84

*Ragni G et al, 2005; **Roma AD, 2004

Diagnostic accuracy of outpatient uterine evaluation techniques compared to operative hysteroscopic findings

	No. (%) with correct diagnosis	No. (%) with incorrect diagnosis
Hysterosalpingography	15 (60)	10 (40)
Hydrosonography	13 (54)	12 (46)
Office hysteroscopy	18 (72)	7 (28)

Brown SE et al, 2000

The advantages of hysteroscopy

- Hysteroscopy is considered the gold standard for the detection intrauterine pathologies.
- The possibility of surgical treatment during the same procedure (see and threat option).

ESHRE Capri Workshop Group (2000)

- It seems that the primary investigation of the morphology of the uterus and tubes should be hysterosalpingography.
- Hysteroscopy is only required for confirmation of doubtful uterine pathology and for the relevant therapy.

ESHRE Capri Workshop Group Hum Reprod 2000.



Fertility: assessment and treatment for people with fertility problems: NICE clinical guedeline 2004

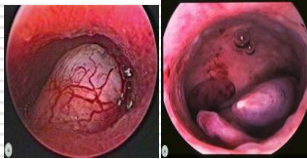Assessing uterine abnormalities

- Women should not be offered hysteroscopy on its own as part of the initial investigation unless clinically indicated because the effectiveness of surgical treatment of uterine abnormalities on improving pregnancy rates has not been established.

Level of evidence B

The effectiveness of surgical treatment of uterine abnormalities on improving pregnancy rates

- endometrial polyps
- submucosal fibroids
- uterus septus
- intrauterine adhesions
- repeated IVF- ET failures



Polypectomy and improved spontaneous pregnancy rates – non randomized studies

□ Hysteroscopic polypectomy improve fertility and increase pregnancy rates irrespective of the size or number of the polyps (Stamatellos I et al, 2008, Shokeir TA et al, 2004, Spiewankiewicz B et al, 2003).

□ Excision of polyps that were located at the uterotubal junction significantly improved the pregnancy rate. Endometrial polyps should be categorized by both size and location (Yanaihara A et al, 2008).

Endometrial polyps and IVF/ICSI outcome – non randomized studies

□ Small endometrial polyps, less than 2 cm, do not decrease the pregnancy rate, but there is a trend toward increased pregnancy loss (Lass A et al, 1999).

□ Endometrial polyps smaller than 1.5 cm do not affect ICSI outcome. (Isikoglu M et al, 2006).

Endometrial polyps and their implication in the pregnancy rates of patients undergoing IUI: a prospective, randomized study

	Hysteroscopic polypectomy (n=101)	Diagnostic hysteroscopy (n=103)
Pregnancy (%)		
Yes	64 (63.4)	29 (28.2)
No	37 (36.6)	74 (71.8)

RR = 2.1 (95% CI 1.5 - 2.9)

Perez-Medina et al, 2005

Effect of submucous fibroids on fertility: systematic review of the evidence

	No. of studies	RR	95% CI	P-value
Clinical pregnancy rate	4	0.36	0.18-0.74	0.005
Ongoing pregnancy rate/ live birth rate	2	0.28	0.12-0.85	<0.001
Spontaneous abortion rate	2	1.68	1.37-2.05	0.022

Pritts EA et al, 2009

Effect of hysteroscopic myomectomy on fertility: systematic review of the evidence

	No. of studies	RR	95% CI	P-value
Controls: fibroids in situ (no myomectomy)				
Clinical pregnancy rate	2	2.03	1.08-3.83	0.028
Spontaneous abortion rate	1	0.77	0.36-1.66	NS
Controls: infertile women with no fibroids				
Clinical pregnancy rate	2	1.54	1.00-2.39	NS
Spontaneous abortion rate	2	1.24	0.47-3.24	NS

Pritts EA et al, 2009

Myomectomy vs. expectant management in subfertile patients with one submucous fibroid <4 cm: a prospective, randomized study

	Hysteroscopic myomectomy (n=52)	Expectant management (n=42)
Pregnancy (%)		
Yes	43.3	27.2
No	56.7	72.8

RR = 1.9 (95% CI 1.0 - 3.7)

Casini et al, 2005

Hysteroscopic metroplasty in infertility patient

- improve pregnancy outcome after conceiving
- improve fertility and increase pregnancy rates ?

Evaluation of the efficacy of metroplasty for the septate uterus presents a number of problems

- The lack of a standard, quantitative definition and diagnostic criteria for septate uterus (what is normal or what degree of abnormality is clinically significant?).
- Observations that reproductive outcomes tend to improve without intervention (what happens when nothing is done ?).
- The lack of any properly conducted randomized, controlled trial.

Pregnancy outcome before and after hysteroscopic metroplasty for the septate uterus

Study	Before metroplasty		After metroplasty	
	Pregnancies (n)	Abortions (%)	Pregnancies (n)	Abortions (%)
March and Israel (1987)	240	88.3	56	14.3
Daly et al. (1989)	150	87.1	84	20.2
Cararach et al. (1994)	176	90.1	41	29.3
Pabuccu et al. (1995)	108	89.5	44	4.5
Valle (1996)	299	86.3	103	11.6
Grimbizis et al. (1998)	78	88.4	44	25.0
Reljić et al. (2005)	230	83.0	111	27.0

Pregnancy outcome after hysteroscopic metroplasty in different groups of patients

	NO previous pregnancy	One spontaneous abortion	Two or more spontaneous abort.
No. of pregnancies	70	50	49
Abortion rate	15.7	28.0	32.7
Preterm delivery rate	7.0	11.1	24.2
Term delivery rate	75.7	64.0	51.0

Reljić et al, 2005

Pregnancy outcome in patients with untreated septate and arquate uterus

	Septate uterus	Arquate uterus
No. of pregnancies	291	241
Abortion rate	28.1	25.7
Preterm delivery rate	14.5	7.5
Term delivery rate	56.7	62.7

Grimbizis GF., 2001

Pregnancy rate after metroplasty for the septate uterus in women with primary infertility

	No. of patient with infertility	Pregnancy rate after treatment (%)
Fayez, 1986	7	71
Perino et al,1987	8	63
Daly et al, 1989	15	47
Querleu et al, 1990	9	67
Marabini et al, 1994	14	44
Pabuccu et al, 1995	10	63
Colacurci et al, 1996	21	29
Total	84	48

Homer et al, 2000

Hysteroscopic resection of the septum improves the pregnancy rate of women with unexplained infertility: a prospective controlled trial

	Hysteroscopic metroplasty	Expectant management	P-value
Number	44	132	
Pregnancies, n(%)	17 (38.6)	27 (20.4)	<0.05
Live birth rate, %	34.1	18.9	<0.05
Fecundity rate	4.27	1.92	

Mollo A et al, 2009

Indications for hysteroscopic metroplasty in infertility (Homer HA et al, 2000)

- ❑ Women with long-standing unexplained infertility in whom an extensive workup has ruled out other factors.
- ❑ Women >35 years of age.
- ❑ Women in whom laparoscopy and hysteroscopy are being performed for other reasons, as septal incision at the same time is opportune and appears logical .
- ❑ Women in whom assisted conception is being contemplated.

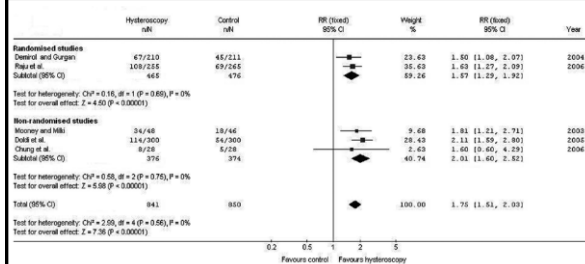
Intrauterine adhesiolysis

- Randomized or controlled studies on reproductive outcome after hysteroscopic synechiolysis are absent (Bosteels J et al, 2009).
- The overall quality of the available non-controlled studies is very poor (Bosteels J et al, 2009).
- The results cannot be directly compared since different non-validated classification systems of the severity of disease are used.

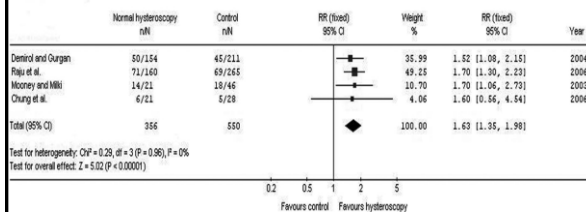
Reproductive outcome of hysteroscopic adhesiolysis for Ascherman syndrome

	No. of patient	Pregnancy rate (%)	Live birth rate (%)
Valle et al, 1988	81	59.2	60.4
Parent et al, 1988	169	63.3	85.0
Pistofidis et al, 1996	86	34.9	70.0
Roge et al, 1997	50	56.0	85.7
Pabuccu et al, 1997	16	62.0	60.0
Feng et al, 1999	189	83.9	92.9
Preutthipan et al, 2000	45	35.6	100.0
Yu D et al, 2009			

Outpatient hysteroscopy and subsequent IVF cycle outcome: summary of the outcome for the five studies included in the systematic review



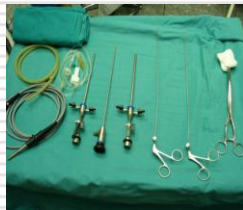Outpatient hysteroscopy and subsequent IVF cycle outcome: summary of the outcome of four studies after excluding patients with abnormal hysteroscopy



El-Toukhy et al, RBMOnline; 2008

Technological improvements in hysteroscopy

- smaller diameter endoscopes (3.5-5.0 mm)
- continuous flow
- bipolar energy
- saline solution distension media



New techniques in hysteroscopy

- vaginoscopy
- atraumatic and sight-controlled insertion of hysteroscope
- no anaesthesia or analgesia necessary
- diagnostic and operative office hysteroscopy
- performed in a "see and treat" fashion

Office hysteroscopy –UKC Maribor

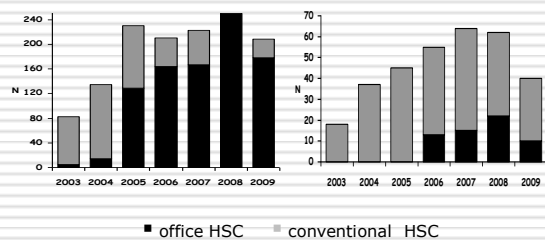
- July 2003- October 2009
- 2526 women
- 37.4% diagnostic hysteroscopy
- 62.6% operative hysteroscopy
- 99.16% "see and treat procedure"



Office vs. conventional operative hysteroscopy UKC Maribor

Endometrial polyp ablation

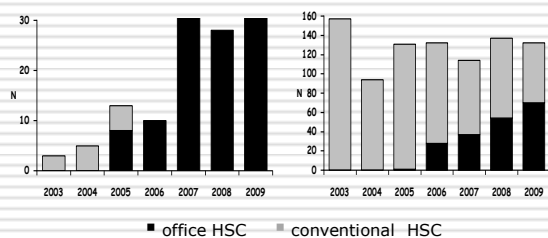
Myoma resection



Office vs. conventional operative hysteroscopy UKC Maribor

Intrauterine adhesiolysis

Septum resection

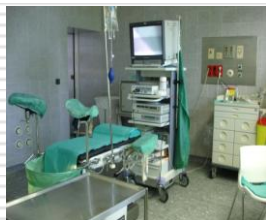

Office hysteroscopy –UKC Maribor

- ❑ Successful hysteroscopy in 96.8%
- ❑ Failed hysteroscopy in 3.19% (occlusion of the cervical canal, poor hysteroscopic view, severe discomfort)
- ❑ Mean pain score; VAS: 1.7 ± 1.4 (0-8)
- ❑ Complications: 0.87% - vasovagal attack immediately after procedure

Office hysteroscopy

- ❑ Accurate and reliable
- ❑ Combined diagnostic/therapeutic approach
- ❑ Simple, fast, safe
- ❑ Patient friendly procedure
- ❑ Low cost



Hysteroscopy in infertility evaluation – our approach

- ❑ US screening for intrauterine pathology.
- ❑ Hysteroscopy is performed in patients:
 - with poor pregnancy outcome
 - with dubious US findings
 - to treat intrauterine pathology
 - after several failed embryo transfers



Conclusions

- Hysteroscopy is gold standard for evaluating intrauterine pathology and should be offered to all patients with suspected intrauterine pathology.
- Operative hysteroscopy increase the pregnancy rate in subfertile patients with a specified intrauterine pathology.
- Diagnostic and operative hysteroscopic procedures can be performed in office setting.

References

- Bosteels J, Weyers S, Puttemans P, Panayotidis C, Van Herendael B, Gomel V, Mol BW, Mathieu C, D'Hooghe T. The effectiveness of hysteroscopy in improving pregnancy rates in subfertile women without other gynaecological symptoms: a systematic review. *Hum Reprod Update*. 2010 Jan-Feb;16(1):1-11.
- Brown SE, Coddington CC, Schnorr J, Toner JP, Gibbons W, Oehninger S. Evaluation of outpatient hysteroscopy, saline infusion hysterosonography, and hysterosalpingography in infertile women: a prospective, randomized study. *Fertil Steril* 2000;74:1029 –34.
- Casini ML, Rossi F, Agostini R, Unfer V. Effect of the position of fibroids on fertility. *Gynecol Endocrinol* 2006;22:106–109.
- El-Toukhy T, Sunkara SK, Coomarasamy A, Grace J, Khalaf Y. Outpatient hysteroscopy and subsequent IVF cycle outcome: a systematic review and meta-analysis. *RBM Online* 2008;16:712–719.
- ESHRE Capri Workshop Group. Optimal use of infertility diagnostic tests and treatments. *Hum Reprod* 2000;15:723–32.

- Grimbizis GF, Camus M, Tarlatzis BC, Bontis JN, Devroey P. Clinical implications of uterine malformations and hysteroscopic treatment results. *Hum Reprod Update* 2001;7:161–74.
- Homer HA, Li TC & Cooke ID. The septate uterus: a review of management and reproductive outcome. *Fertil Steril* 2000; 73(1): 1-14.
- Isikoglu M, Berkkanoglu M, Senturk Z, Coetzee K, Ozgur K. Endometrial polyps smaller than 1.5 cm do not affect ICSI outcome. *Reprod Biomed Online* 2006;12:199–204.
- Lass A, Williams G, Abusheikha N, Brinsden P. The effect of endometrial polyps on outcomes of in vitro fertilization (IVF) cycles. *J Assist Reprod Genet* 1999;16:410–5.
- Lindeman H, Mohr J. CO2 hysteroscopy, diagnosis and treatment. *Am J Obstet Gynecol* 1976;124:129 –33.
- Gallinat A. *Hysteroscopy principles and practice*. Philadelphia: JB Lippincott, 1984.

Mollo A, De Franciscis P, Colacurci N, Cobellis L, Perino A, Venezia R. Hysteroscopic resection of the septum improves the pregnancy rate of women with unexplained infertility: a prospective controlled trial. *Fertil Steril*. Jun 2009;91(6):2628-31

Perez-Medina T, Bajo-Arenas J, Salazar F, Redondo T, Sanfrutos L, Alvarez P, et al. Endometrial polyps and their implication in the pregnancy rates of patients undergoing intrauterine insemination: a prospective, randomized study. *Hum Reprod* 2005;20:1632-5.

Pritts EA. Fibroids and infertility: a systematic review of the evidence. *Obstet Gynecol Surv* 2001;56:483-91.

Ragni G, Diaferia D, Vegetti W, Colombo M, Arnoldi M, Crosignani PG. Effectiveness of sonohysterography in infertile patient work-up: a comparison with transvaginal ultrasonography and hysteroscopy. *Gynecol Obstet Invest* 2005;59:184-8

Roma Dalfo A, Ubeda B, Ubeda A, et al. Diagnostic value of hysterosalpingography in the detection of intrauterine abnormalities: a comparison with hysteroscopy. *AJR* 2004;183:1405-1409.

Shokeir TA, et al. Significance of endometrial polyps detected hysteroscopically in eumenorrheic infertile women. *J Obstet Gynaecol Res*. 2004 Apr;30(2):84-9.

Spiewankiewicz B, et al. The effectiveness of hysteroscopic polypectomy in cases of female infertility. *Clin Exp Obstet Gynecol*. 2003;30(1):23-5.

Stamatellos I, et al. Pregnancy rates after hysteroscopic polypectomy depending on the size or number of the polyps. *Arch Gynecol Obstet*. 2008 May;277(5):395-9.

Yanaihara A, et al. Location of endometrial polyp and pregnancy rate in infertility patients. *Fertil Steril*. 2008 Jul;90(1):180-2.

Yu D, Wong YM, Cheong Y, Xia E, Li TC. Asherman syndrome—one century later. *Fertil Steril* 2008;89:759-779.

Wallach EE. The uterine factor in infertility. *Fertil Steril* 1972;23: 138-58.

N.O.T.E.S & The Retroperitoneum

Joseph NASSIF, MD*
Arnaud WATTIEZ, MD*

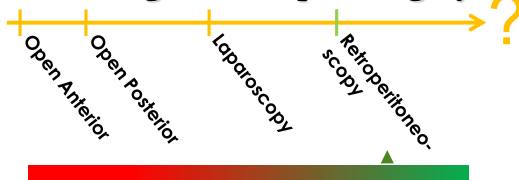
* IRCAD/EITS , Strasbourg, France

26th Annual Meeting
ESHRE – ROME 2010

Disclosure Slide

- We declare that we have no conflict of interest and no commercial relationship with any product that may be cited in the current presentation

Background: Open surgery



Darkei M. Retroperitoneoscopy. An endoscopic method for inspection and biopsy examination of the retroperitoneal space. Zentralbl Chir. 1989 Mar 22;94(12):377-83.
Mazzanti S, Sauer R, Tschopp S. Endoscopic retroperitoneal adrenalectomy. Surgery. 1995; 118(5):1671-5.
Wada MK, Paltan K, Egler FV. Posterior retroperitoneoscopy as a new minimally invasive approach for adrenalectomy: results of 30 adrenalectomies in 27 patients. World J Surg. 1996 Sep;20(7):790-94.

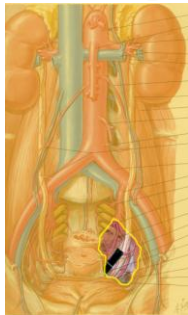Background: NOTES

- Previous experiences:
Nephrectomy: Animal, Human (Hybrid technique)
Adrenalectomy: Animal
Distal pancreas: Animal

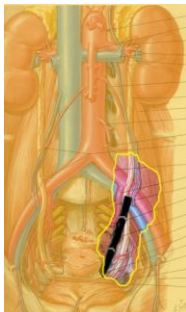→ BUT ALL BY
TRANSPERITONEAL ACCESS

Burton TH. Natural orifice transabdominal endoscopic surgery. Br J Surg. 2007 Jun;94(6):1-2.
De la Fuenten SD, Orensato EJ, Pryor AG. New developments in surgery: Natural Orifice Transluminal Endoscopic Surgery (NOTES). Arch Surg. 2007 Mar;142(3):296-7.
Ryu M, Pong CC, Pua RD, Tawakkolali A, Ratner CW, Thompson CC. Dual-port distal pancreatectomy using a prototype endoscope and endoscopic stapler: a natural orifice transabdominal endoscopic surgery (NOTES) animal study in a porcine model. Endoscopy. 2007 Oct;39(10):1387-7.
Branco AR, Branco FRe AJ, Rangel M. Hybrid transvaginal nephrectomy. Eur Urol. 2008 Jun;53(6):1260-4. Epub 2007 Nov 5.

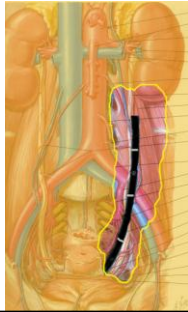NOTES retrop. access



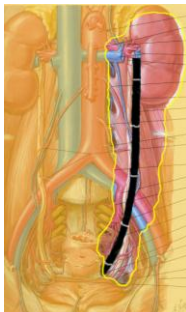NOTES retrop. access



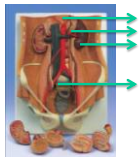
NOTES retrop. access



NOTES retrop. access



Retroperitoneum on animal model



Lymphadenectomy	Acute [3] Survival [6]
Nephrectomy	Acute[5+7+2] Survival [3+4]
Adrenalectomy	Acute [2+1]
Distal pancreatectomy	Acute [2] Survival [1]
TOTAL: 36 [14 - S]	

Human application

- Comparison with Retroperitoneoscopy:
 - Same space → Dissection feasible
 - Same technical advantages (gas dissection, retraction)
- Still pending: Access to the Gerota's space
 - development of a human cadaver model

Human Cadaver

Retroperitoneum

Background

- Pelvic and lombo-aortic lymphadenectomy is prognostic and staging for many oncological gynecologic and urologic interventions :
 - Ovarian cancer
 - Endometrial cancer
 - Cervical cancer
 - Testicular cancer
- Porcine model is excellent for lymphadenectomy

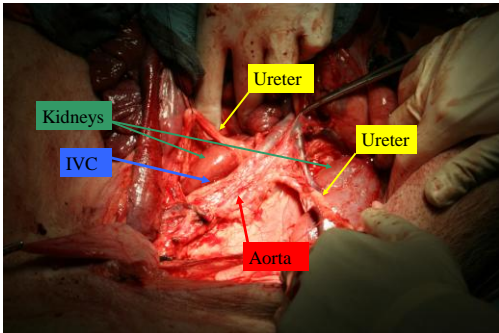
Background

- Pelvic and lombo-aortic lymphadenectomy is prognostic and/or staging for :
 - Ovarian / Endometrial / Cervical cancer
 - Testicular / Prostate cancer
- In advanced ovarian cancer systemic lymphadenectomy has no impact on survival compared with removal of macroscopic lymph nodes only
Ushijima et al, Management of retroperitoneal lymph nodes in the treatment of ovarian cancer, Int J Clin Oncol (2007) 12:181-186
- LRPLND vs Open technique : less morbidity &

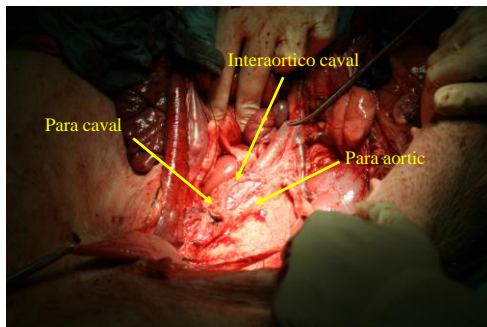
Potential benefits

- Less invasive
- No opening in peritoneum => oncological benefit
- Lymphocele / ascites
- Pain
- Sentinel node with NOTES +++

Anatomy



Anatomy



Access to Retroperitoneum video

Pelvic lymph nodes video

Lomboaortic lymphadenectomy video

Results

- 6 pigs surviving 3 weeks
- No signs of distress and good feeding habits
- Good vaginal healing

Results

- 6 pigs surviving 3 weeks
- No signs of distress and good feeding habits
- Good vaginal healing
- Second look laparoscopy
 - No adhesions
 - No abscess
 - No lymphocel

Results

- 6 pigs surviving 3 weeks
- No signs of distress and good feeding habits
- Good vaginal healing
- Second look laparoscopy
 - No adhesions
 - No abscess
 - No lymphocel
- Laparotomy + peritonectomy
 - No retroperitoneal fibrosis
 - No abscess
 - No fluid collection

Results

- 6 pigs surviving 3 weeks
- No signs of distress and good feeding habits
- Good vaginal healing
- Second look laparoscopy
 - No adhesions
 - No abscess
 - No lymphocel
- Laparotomy + peritonectomy
 - No retroperitoneal fibrosis
 - No abscess
 - No fluid collection
- Totally NOTES procedure (non hybrid)

Results

- Adhesions
- Peritoneum: Recto or Verso ?

ADVANTAGES



- Feasible
- Respect of the peritoneum integrity
- CO2 pneumodissection
- Natural retraction
- Dorsal decubitus, LS-like view
- Direct access to the vessels

LIMITATIONS / CONCERNS



Challenges: Vascular control

Endoscopic loop

LIMITATIONS / CONCERNS

videos



LIMITATIONS / CONCERNS



- Instruments: strength, bipolar, staplers
- Transvaginal... availability: 50% pop
- ~ Infection?

Conclusions

- Access: feasible & reproducible [animal, cadaver]
- Potential advantages:
 - No skin incision
 - No peritoneal incision
 - Posterior approach
- Complete bilateral exploration (multiple tumors, LN mapping)

Thank you for your attention !



NOTES:

Current animal and clinical applications state of the art

S. PERRETTA, MD

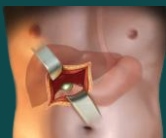University of Strasbourg, France

iread

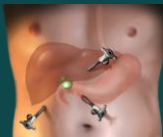« La suppression de la douleur en chirurgie est une utopie... scalpel et douleur sont des mots indissociables qui resteront toujours dans la mémoire du patient opéré »

Dr. Alfred Velpeau (1839)

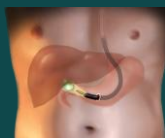
Minimal Access Surgery



Open
Cholecystectomy
1867



Laparoscopic
Cholecystectomy
1987



Transgastric
Cholecystectomy
2007

History

- Apollo group 1998

Sydney Chung, Peter Cotton, Christopher Gostout
 Robert Hawes, Anthony Kalloo, Sergey Kantsevov
 Pankaj Pasricha
- ↓
- Kalloo; 1st abstract DDW 2000
- ↓
- Kalloo; 1st paper 2004

**Flexible transgastric peritoneoscopy: a novel approach
To diagnostic and therapeutic interventions in the
Peritoneal cavity**

Gastrointest Endosc, 2004;60:114-117


What is N.O.T.E.S.™ ?

Natural Orifice Transluminal Endoscopic Surgery

White Paper 2005
ASGE & SAGES

*...The natural orifices may provide the entry point for
surgical interventions in the peritoneal cavity, **thereby**
avoiding abdominal wall incisions...*

N.O.T.E.S: Potential Advantages



- No abdominal wall incision
 - No scars
 - No wound infection
 - No incisional hernias
- Less physiologic stress?
- Faster recovery?

N.O.T.E.S: Challenges

Optimal site for peritoneal access

Organ retraction

Triangulation

Control of intra-operative complications

Tissue approximation

8

N.O.T.E.S.: History

• Apollo group 1998



• Kallio; 1st abstract DDW 2000



• Kallio; 1st paper 2004



ircad



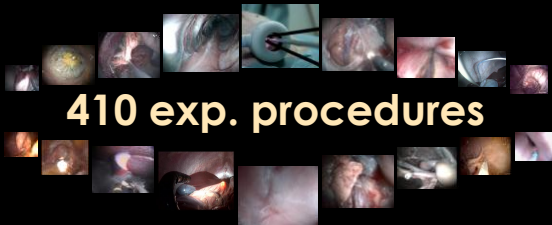ANUBIS 2004



ircad

NOTES R&D IRCAD 2005 - 2008


410 exp. procedures



ircad




N.O.T.E.S: Challenges



1. Access & closure
2. Exposure - retraction
3. Instrumentation
4. Training

N.O.T.E.S: Challenges



1. Access & closure
2. Exposure - retraction
3. Instrumentation
4. Training

Access to the peritoneal cavity

Single or Combined

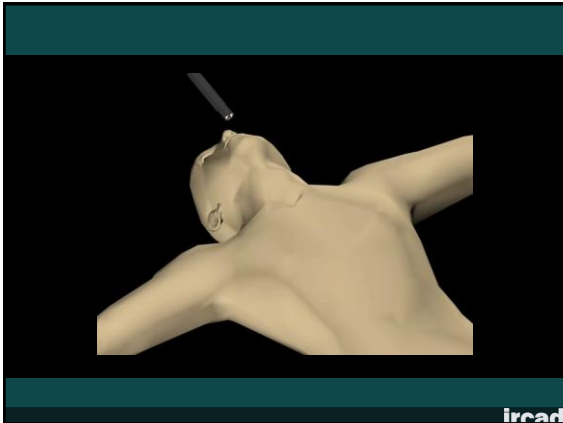
Transvaginal

Transcolonic

Transgastric

Transvesical

lread



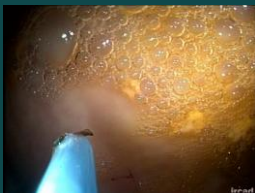
lread

Transgastric Access

1. Techniques of Gastrotomy

Free Cut

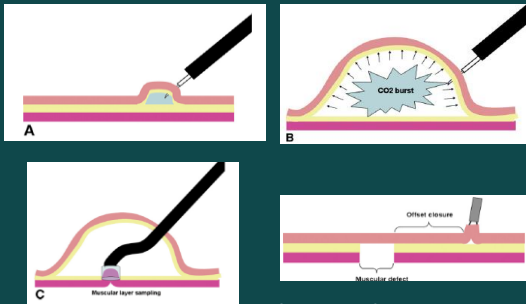
PEG + Balloon Dilatation



lread

lread

1. Techniques of Gastrotomy



Sumiyama et al. Gastrointest Endosc 2007

N.O.T.E.S: R&D

Closure of the access site

Techniques of Closure

Technology	Author	Year
Endoclips	Kalloo	2004
	Raja	2006
	Pai	2006
Suturing	Hu	2005
NDO plic.	McGee	2007
Occluder	Perretta	2007
T- Fasteners	Sumiyama	2007
Plugs	Clos	2007
G-Prox	Swanstrom	2007
Gastrotomy Tube	McGee	2008
Stapler	Meireles	2008

Transgastric Access

2. Techniques of Closure of Gastrotomy

IRCAD

1. Endoclips (Olympus, Boston...)
2. Clipped Endoloop
3. OTSC clip
4. Occluder
5. Anubiscope

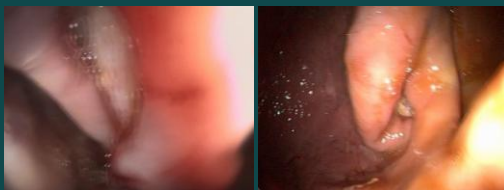
Transgastric Access

2. Techniques of Closure of Gastrotomy

1. Endoclips (Olympus, Boston...)

1 endoscope

2 endoscopes



Transgastric Access

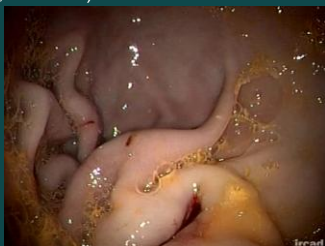2. Techniques of Closure of Gastrotomy

1. Endoclips (Olympus, Boston...)

2. Clipped Endoloop

3. OTSC clip

4. Occluder

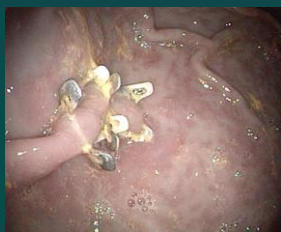

2. Techniques of Closure of Gastrotomy

1. Endoclips (Olympus, Boston...)

2. Clipped Endoloop

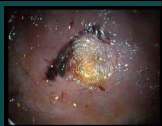3. OTSC clip



Transgastric Access

2. Techniques of Closure of Gastrotomy

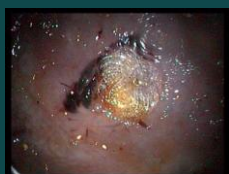1. Endoclips (Olympus, Boston...)
2. Clipped Endoloop
3. OTSC clip
4. Occluder




N.O.T.E.S: R&D

Closure of the access site

2. Techniques of Closure: survival studies



2. Techniques of Closure of Gastrotomy



Sumiyama et al Gastrointest Endosc 2007.

Courtesy of Dr. N.Soper

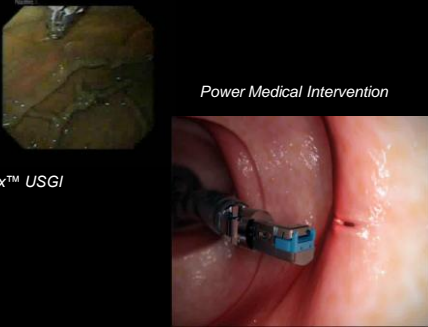
N.O.T.E.S: R&D Closure of the access site

ID: No. 1
 Date: 1/1/2005
 D. D. 10/1/05
 11/22/2005
 10:52:43

Notes

Power Medical Intervention

G-Prox™ USGI



Transgastric Access

The future



Transgastric Access

3. Peritoneal Contamination

1. Study of peritoneal contamination during bypass

Narula et al. Surg End 2007

- Transgastric access contaminates the abdominal cavity
- pathogens are clinically insignificant (species-load)
- no clinical significant infection
- Patients on PPIs do have an increased bacterial load

Transgastric Access

Specimen retrieval

How big is too big.....?



Transgastric Access

Specimen retrieval

How big is too big.....?

✓ Reasonable size : 2 cm

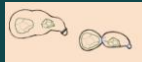✓ Reasonable force: tensile strength of the esophagus 25-27N

Thompson K, DDW 2009

Reported, unpublished complications (Latin American NOTES registry):

- Esophageal tear: mediastinitis
- Hematomas

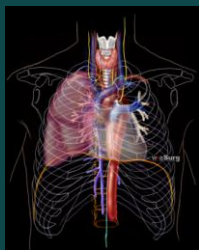✓ Gallbladder puncture and « partition »



F. Jurczak Journal de Chirurgie (2009) 146, 30—33

Access to the chest

Transesophageal Access



Transesophageal Access

Mediastinoscopy
Thoracoscopy

Lymphadenectomy
Lung biopsy

Sympathectomy

Pericardial window
Intracardiac injection

Heller myotomy

Copyright© WebSurge® HCAD® - All rights reserved

- ✓ Diagnostic procedures
- ✓ Interventional procedure
 - Within the esophagus
 - Beyond the esophagus

Transesophageal Access

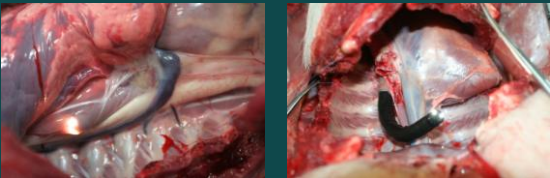
1. EUS view "beyond the wall"

➔ might enable to foresee/avoid possible complications

1. visualizing blood vessels
2. interposing structures in the way
3. find pathway in difficult location


EUS-FNA for Diagnostic / cell sampling

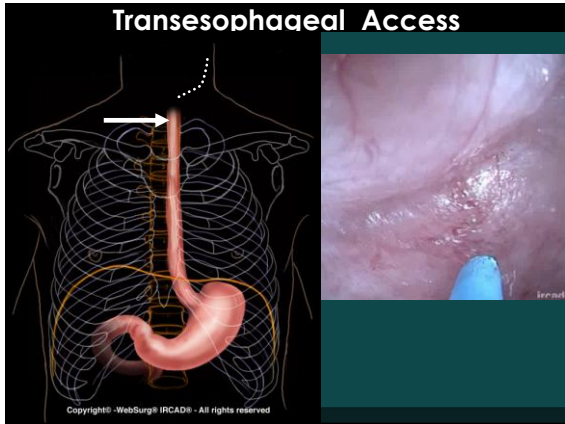
- Staging esophageal cancer
- Diagnosis/Staging lung cancer
- any mediastinal nodes
- mediastinal abscesses

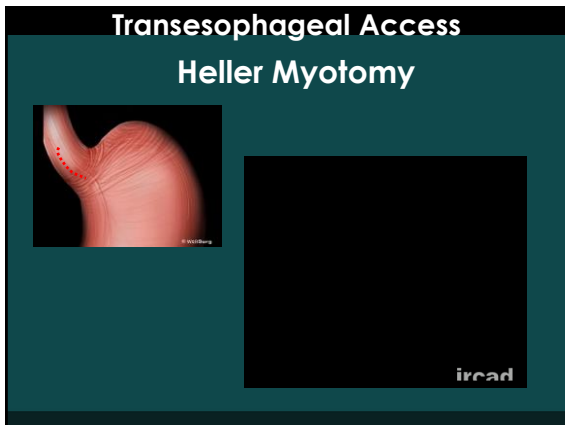


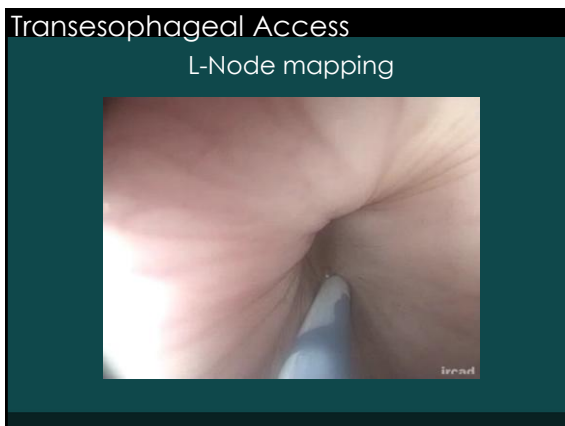
N.O.T.E.S: R&D

Trans-esophageal access

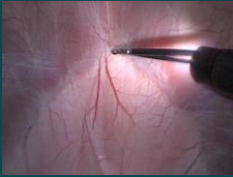







Transesophageal Access



Pulmonary biopsy

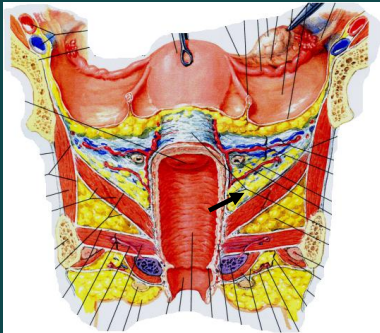
Pericardial window

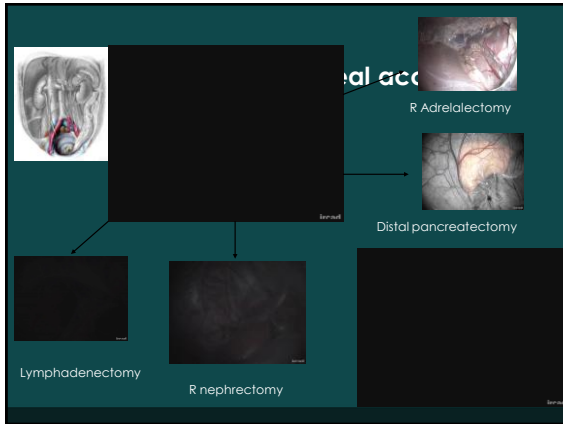


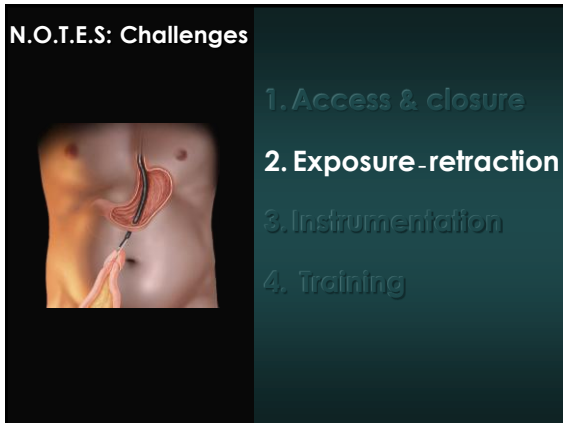
What's new

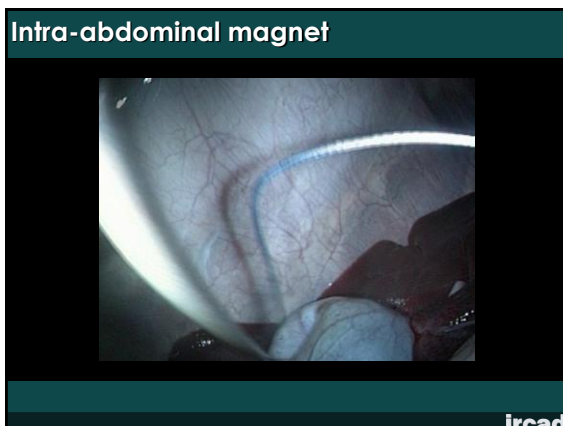


Access to retroperitoneum

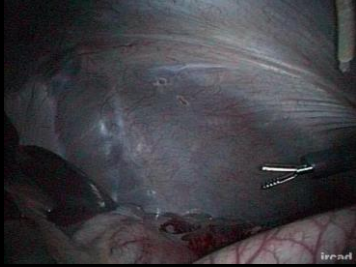



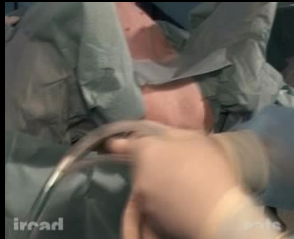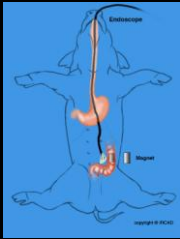




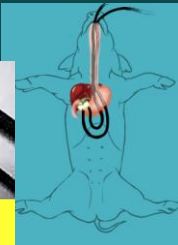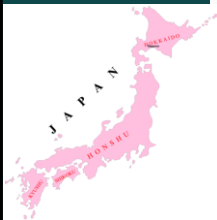Endoluminal magnet: intragastric



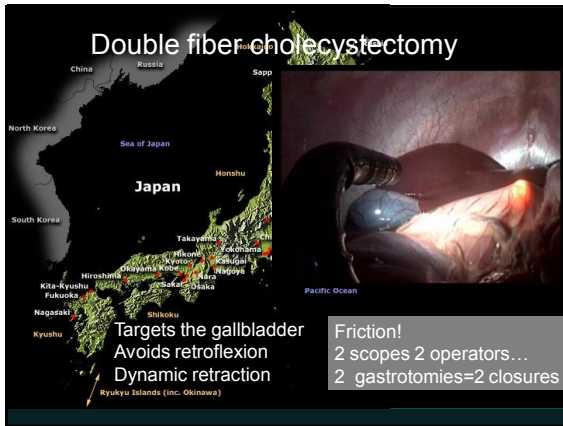Endoluminal magnet: endorectal

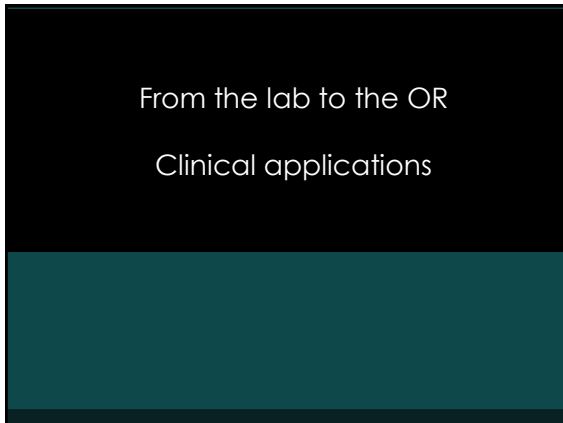


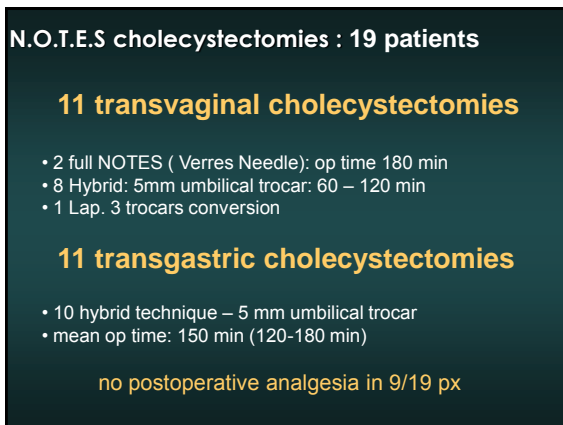
Combined transgastric approach: Double fiber Technique



M.Asakuma







Preoperative work-up

- Non complicated cholelithiasis:
 - US and Lab work
- Multidisciplinary approach
 - GYN evaluation: pelvic exam and interview
 - Contact patients GYN: discuss approach and follow-up
- QOL evaluation: SFQ 31 and GIQLI

Exclusion criteria

- Previous vaginal surgery
- Rectovaginal endometriotic nodule
- Fixed retroverted uterus
- Posterior uterine myoma
- Cervical cancer

= contraindications(4,6% in a series of 1500 infertile women)
Watrelet et al Hum. Reprod 2004

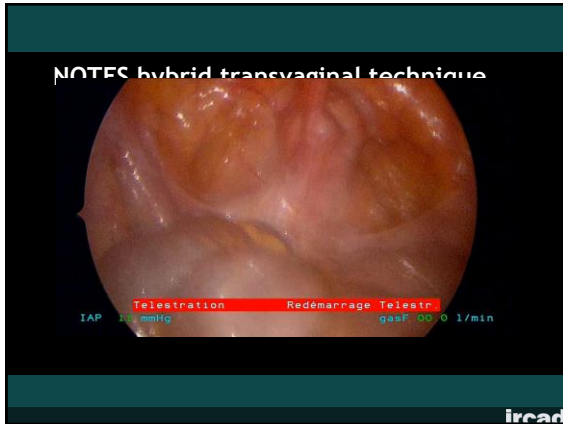
+ Nulliparous!

First transvaginal cholecystectomy (Apr. 2007)



Arch Surg 2007 142: 823-826

iread



N.O.T.E.S Cholecystectomy

11 transvaginal cholecystectomies

-April 2007 and September 2009-

2 full NOTES (Verres Needle): op time 180 min

✓ 9 Hybrid: 5mm umbilical trocar: 45 – 120 min

✓ 1 postoperative bleeding (endoclip)

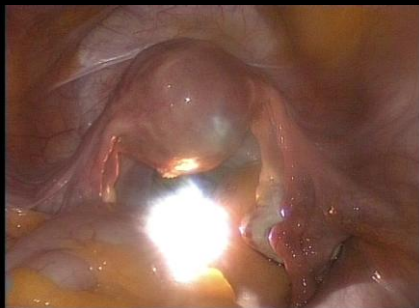Transvaginal intraperitoneal sleeve gastrectomy

Diagram illustrating the transvaginal intraperitoneal sleeve gastrectomy approach, showing the abdominal cavity and the location of the Verres needle and trocar.

Intraoperative view showing the surgical dissection and the placement of the Verres needle and trocar.

ircad

First sleeve gastrectomy (dec. 2007)



6 patients

iread

N.O.T.E.S Cholecystectomy

Results: Gyn

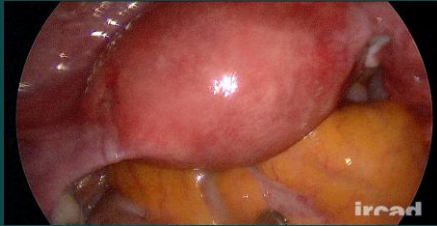
- Vaginal discharge = 0
- Bleeding at D 10 (scar fall) = 0
- Fibrotic bridge at scar location = 0
- Scar Retraction = 0
- Scar Induration = 0
- Visible scar = 0
- Pain at pelvic exam = 0
- Normal Pap smear = 9/9
- Resuming sexual activity after 5,2 +/- 3.7 weeks
- Pregnancy after intervention = 0

N.O.T.E.S Cholecystectomy

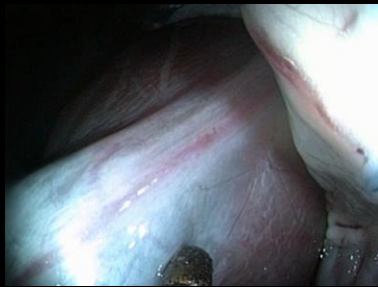
Conclusions

- Safe and short term results similar to laparoscopic cholecystectomy: Hybrid format!
- Clean portal for NOTES
- Less adhesion formation?
- Well accepted by patients
- Sexual function unchanged
- And, ...

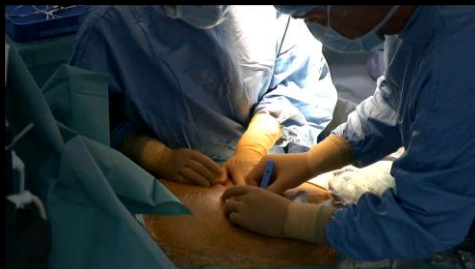Can we do it again?



Exp. Transgastric cholecystectomy



First transgastric cholecystectomy (sept. 2007)

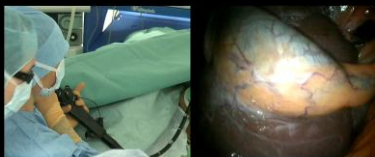


10th transgastric cholecystectomy

ircad

ircad

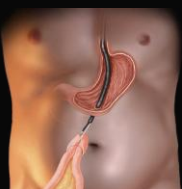Transgastric cholecystectomy



ircad

ircad

N.O.T.E.S: Challenges



1. Access & closure
2. Exposure-retraction
3. Instrumentation
4. Training

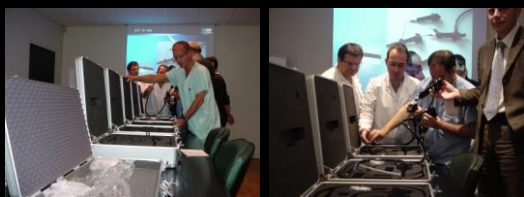N.O



- Control of bleeding
- Grasping
- Cutting and sewing

irrad

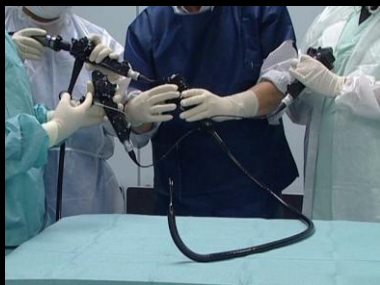First Tools



November 2005

irrad

First Tools



November 2005

irrad

Research & Developpement

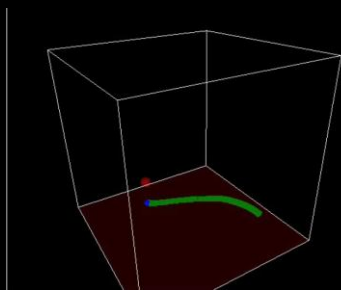
ircad

© KARL STORZ GmbH & Co. KG
Tuttlingen/Germany

October 2008

ircad

NOTES & Robotics



ircad

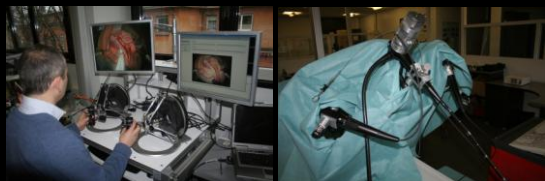NOTES & Robotics



ircad

NOTES & Robotics

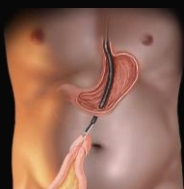Single user Master Slaves NOTES Robot



LSIIT Robotic team of Michel de Mathelin, IRCAD - Strasbourg university

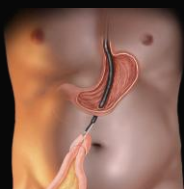ircad

N.O.T.E.S: Challenges



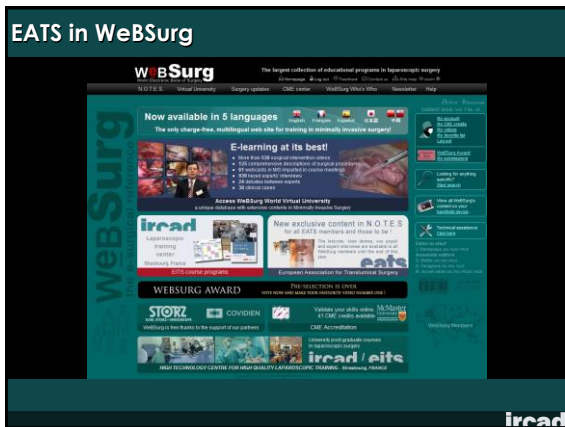1. Access & closure
2. Exposure-retraction
3. Instrumentation
4. Training

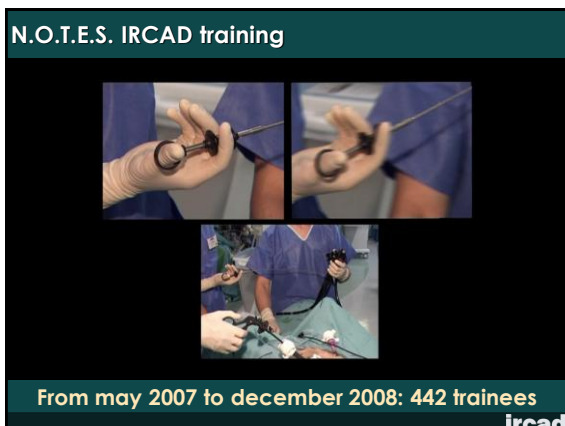
N.O.T.E.S: Challenges



1. Access & closure
2. Exposure-retraction
3. Instrumentation
4. Training





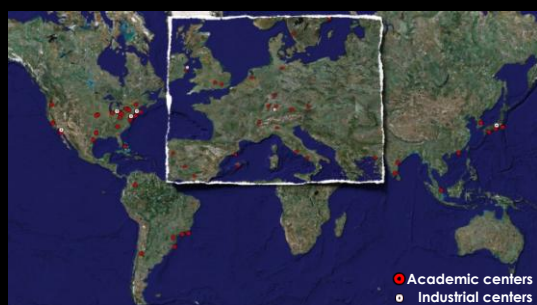

Lessons learned

Worldwide interest

lread

Worldwide interest



lread

NOTES Results

- Largely unknown
- Few published studies
- Estimates of <50 transgastric operations and >250 transvaginal procedures
- Transgastric operations double or triple OR time; transvaginal procedures ~1.5 X
- No major complications reported to date, but rumors of deaths have surfaced
- registry not yet widely used

NOTES Current Human Applications

Conclusions

1. Totally NOTES cholecystectomy - appendectomy are feasible
2. Major limitation
instrumentation – clips (patient safety) – retraction
potential for R&D
3. Current techniques : Hybrid NOTES (trocar)
4. No clinical conclusions at this point
5. Other applications under evaluation

Conclusion

The first
"Keyhole Surgery"
Course

IRCAD

ircad

Is there a place for N.O.T.E.S. in the gynecological surgical palette ?

Joseph NASSIF, MD*
Arnaud WATTIEZ, MD*

* IRCAD/EITS, Strasbourg, France

26th Annual Meeting
ESHRE – ROME 2010

Disclosure Slide

- We declare that we have no conflict of interest and no commercial relationship with any product that may be cited in the current presentation

Animal studies publication

- Transgastric peritoneoscopy, liver biopsy
Kalloo et al
- Transgastric tubal ligation *Jaganath et al*
- Endoscopic gastrojejunostomy *Kantsevov et al*
- Transgastric cholecystectomy *Park et al*
- Transgastric oophoro/salpingectomy *Wagh et al*
- Transgastric Partial hysterectomy *Merrifield et al*
- Transgastric spenectomy *Kantseov et al*
- Transcolonic cholecystectomy *Pai et al*

Human application publications

- *Transgastric appendectomy* (India 2002)
- *Transgastric Peritoneoscopy* (Ohio State University 2006)
- *Transvaginal cholecystectomy* with laparoscopic assistance (New York 2007)
- *Transvaginal cholecystectomy (unassisted)* (France IRCAD 2007)
- *Transgastric cholecystectomy* (Oregon 2008)
- *Transvaginal appendectomy* (India 2008)

Intern Journal of Surgery 6 (2008)

Today's challenges

- Optimal access
- Retraction / exposure
- Instruments
- Lack of triangulation
- Closure

Today's challenges

- Optimal access
- Retraction / exposure
- Instruments
- Lack of triangulation
- Closure

- Need for a specialized training or specialty

NOTES & Gynecology

NOTES in gynecology

- Fertiloscopy

- Transvaginal laparocopy

Retroversion

video

View of the pelvis

N.O.T.E.S , Gynecology &
Retroperitoneum

Malignancy Staging

- 50 years old
- Suspicion of peritoneal carcinomatosis
- Transvaginal NOTES
- diagnostic staging
- 16 biopsies : liver, diaphragm, ovaries, and peritoneum were successfully performed
- Operative time = 105 min
- vaginal access and closure were obtained in 15 min
- dismissed 48 hours

Zorrón R, Soldan M, Filgueiras M, Maggioni LC, Pombo L, Oliveira AL. NOTES Transvaginal for Cancer Diagnostic Staging: Preliminary Clinical Application. Surg Innov. 2008;16:6.

Acceptability

How do gynecologists feel about transvaginal NOTES ?

- Questionnaire
- 69.2 % ethical
- 28.8 % would recommend NOTES to their patients
- NOTES-associated complications
 - 73.1 % infection
 - 61.5 % visceral lesions
 - 44.2 % infertility
 - 34.6 % adhesions
- Long-term concerns : dyspareunia and infertility

Thele F, Zygmunt M, Glitsch A, Heidecke CD, Schreiber A How do gynecologists feel about transvaginal NOTES surgery ? Endoscopy. 2008 Jul;40(7):576-80.

Patients' point of view

- Would patients accept to go through
 - the vagina to perform non gynecological procedures ?
 - the stomach to do gynecological procedure ?

Potential gynecological applications

- Pelviscopy +/- Prolapse surgery
- Reproductive surgery : ovaries, fallopian tubes, Douglas pouch
- Ovarian cysts
- Ectopic pregnancy
- Tubal reversal
- Gynecological malignancy staging (zorron et al)
- Sentinel lymph node
- Sterility requirements => NOTES makes the OR every where !!

Conclusion

We can do anything, but ...

What do we want ?

Questions ???



Mark your calendar for the upcoming ESHRE campus workshops!

- **Basic Genetics for ART Practitioners**
organised by the SIG Reproductive Genetics
16 April 2010 - Porto, Portugal
- **Array technologies to apprehend developmental competence and endometrial receptivity: limits and possibilities**
organised by the Task Force Basic Science in Reproduction
22 April 2010 - Brussels, Belgium
- **The management of infertility – training workshop for junior doctors, paramedicals and embryologists**
organised by the SIG Reproductive Endocrinology, SIG Embryology and the Paramedical Group
26-27 May 2010 - Kiev, Ukraine
- **Preimplantation genetic diagnosis: a celebration of 20 years**
organised by the SIG Reproductive Genetics
1 July 2010 - Rome, Italy
- **EIM 10 years' celebration meeting**
organised by the European IVF Monitoring Consortium
11 September 2010 - Munich, Germany
- **The determinants of a successful pregnancy**
organised by the SIGS Reproductive Surgery, Early Pregnancy and Reproductive Endocrinology
24-25 September 2010 - Dubrovnik, Croatia
- **Basic training workshop for paramedics working in reproductive health**
organised by the Paramedical Group
6-8 October 2010 - Valencia, Spain
- **Forgotten knowledge about gamete physiology and its impact on embryo quality**
organised by the SIG Embryology
9-10 October 2010 - Lisbon, Portugal

www.eshre.eu
(see "Calendar")

Contact us at info@eshre.eu



Keep an eye on our calendar section for more information on

Upcoming events

- **Female and male surgery in human reproductive medicine**
8-9 October 2010 - Treviso, Italy
- **Promoting excellence in clinical research: from idea to publication**
5-6 November 2010 - Thessaloniki, Greece
- **"Update on pluripotent stem cells (hESC and iPS)" and hands on course on "Derivation and culture of pluripotent stem cells"**
8-12 November 2010 - Valencia, Spain
- **Women's health aspects of PCOS (excluding infertility)**
18 November 2010 - Amsterdam, The Netherlands
- **Endoscopy in reproductive medicine**
24-26 November 2010 - Leuven, Belgium
- **Fertility and Cancer**
25-26 November 2010 - Bologna, Italy
- **The maternal-embryonic interface**
2-3 December 2010 - Valencia, Spain
- **GnHR agonist for triggering of final oocyte maturation – time for a paradigm shift**
3 December 2010 - Madrid, Spain
- **Raising competence in psychosocial care**
3-4 December 2010 - Amsterdam, The Netherlands

www.eshre.eu
(see "Calendar")

Contact us at info@eshre.eu



NOTES

<h2>NOTES</h2>

NOTES

NOTES

<h2>NOTES</h2>

NOTES

NOTES

<h2>NOTES</h2>
