

Evidence for surgical approaches to enhancing fertility for congenital anomalies

Marco Gergolet, MD, MSc

S.I.S.ME.R., Reproductive Medicine Unit, Bologna, Italy

S.I.F.E.S. Slovene Institute for Fertility and Endoscopic Surgery, Nova Gorica, Slovenia



Congenital uterine anomalies

Prevalence

A critical analysis of studies from 1950 to 2007, done with different diagnostic tools :

- Most accurate diagnostic procedures:
 - hysteroscopy + laparoscopy
 - sonohysterography (SHG)
 - 3D ultrasound
- Less accurate tools:
 - 2D US, and HSG

The study found a 6.7% prevalence of congenital uterine anomalies in the general population, 7.3% in the infertile population and 16.7% in the RM population.

The arcuate uterus was the commonest anomaly found in the general and RM population.

Septate uterus was the commonest anomaly found in the infertile population



Prevalence of congenital uterine malformations

General population

Author	Method	Anomalies (%)
Raga 1997	HSG, HSC	3.8
Acién 1997	Vag. US, HSG	4.6*, 7.8**, 16.7***
Jurković 1997	3D US	5.4
Maneschi 1995	HSC	10
Nasri 1990	US	2.7

*:Previous term pregnancies, **: previous pregnancies and some miscarriage, *** nulligravidae



Prevalence of congenital uterine malformations

Infertile population

Author	Method	Incidence %
Tulandi 1980	HSG	1.0
Sorensen 1981	HSG	23.9
Raga 1996	HSG, Vag. US, 3D US	26.2
Acién 1997	HSG, Vag. US	16.0



Prevalence of congenital uterine malformations

RM population

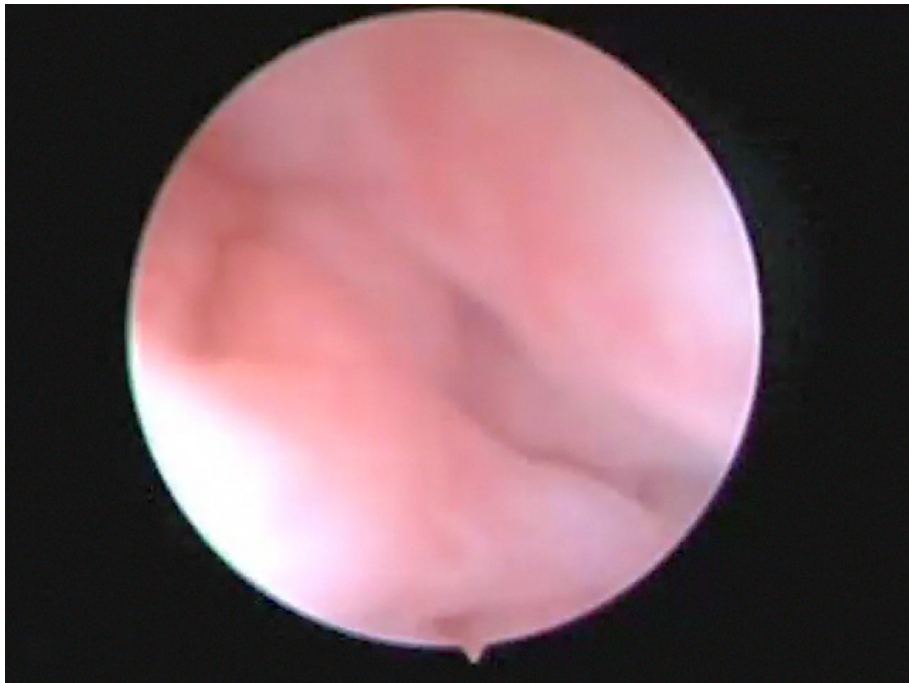

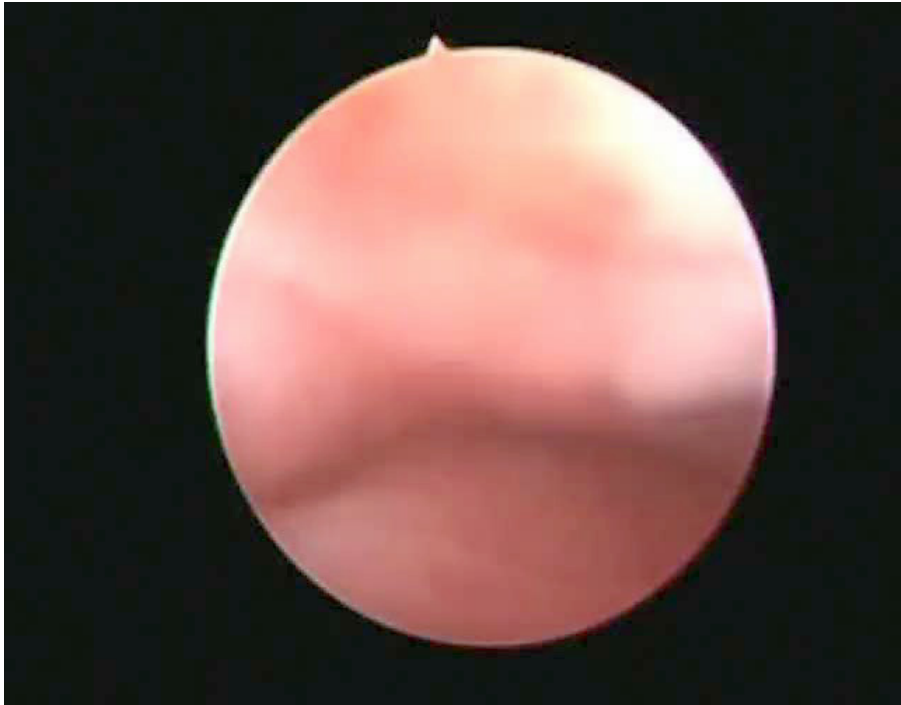
Author	Method	Incidence %
Clifford 1994	HSG, Vag US	1.8
Jurković 1995	HSG, Vag. US, 3D US	19.7
Raga 1997	HSG, HSC, LAP	6.3
Acién 1997	HSG, Vag. US	25.4

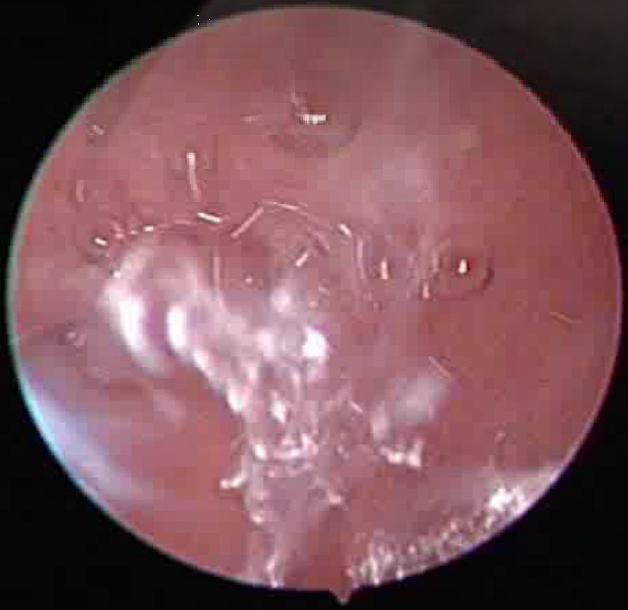
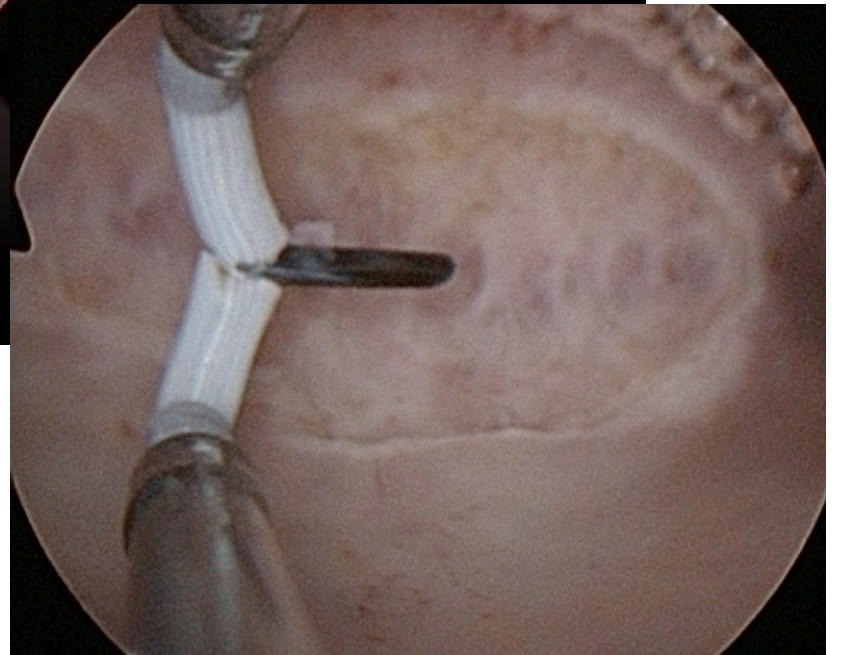
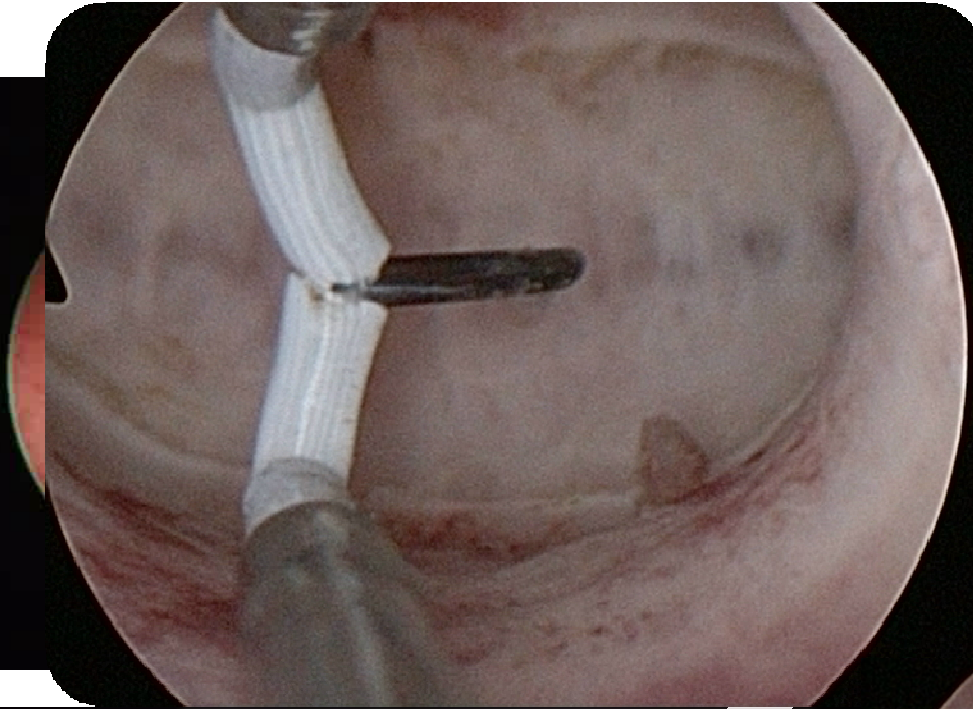


Prevalence of different types of uterine malformations

Author	Method	Arcuate %	Septate %
Exalto 1978	US, Lap	4	40
Acién 1996	Vag US, HSG	27.1	17.1
Raga 1997	HSG, HSC	32.8	33.6
Vercellini 1999	HSC	8.1	54.2







AFS Classification

Class I: segmental agenesis and variable degrees of uterovaginal hypoplasia.

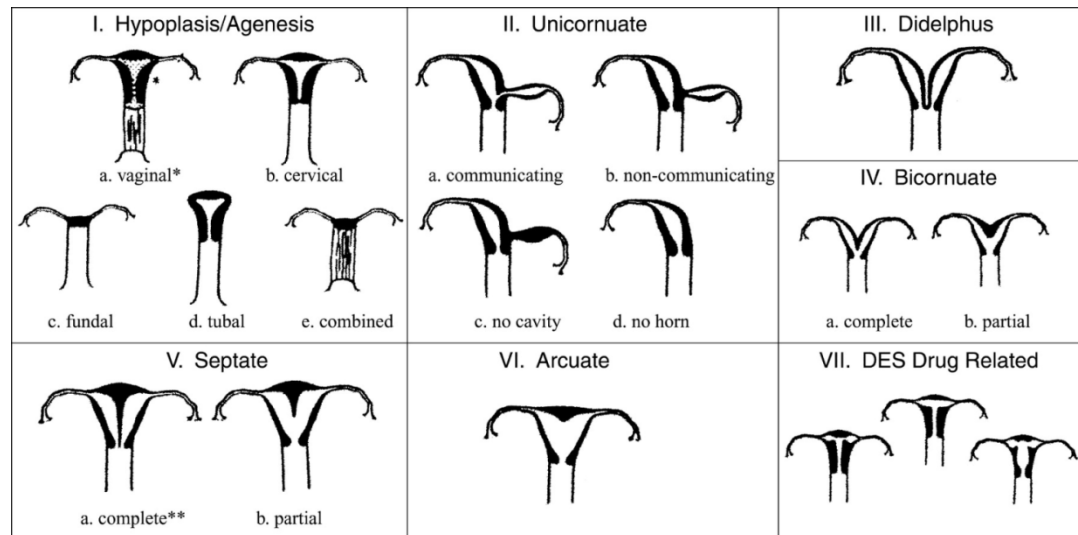
Class II: unicornuate uteri (partia or complete unilateral hypoplasia).

Class III: uterus didelphys (duplication of the uterus results from complete nonfusion of the muellerian ducts).


Class IV: bicornuate uteri with incomplete fusion of the superior segments of the uterovaginal canal.

Class V: Septate uterus, the external shape of the uterus is a single unit. (distinct from the bicornuate uterus which can be seen branching into two distinct horns when viewed from the outside).

Class VI: Arcuate uterus. The uterus is essentially normal in shape with a small, midline indentation in the fundus which results from failure to completely dissolve the median septum



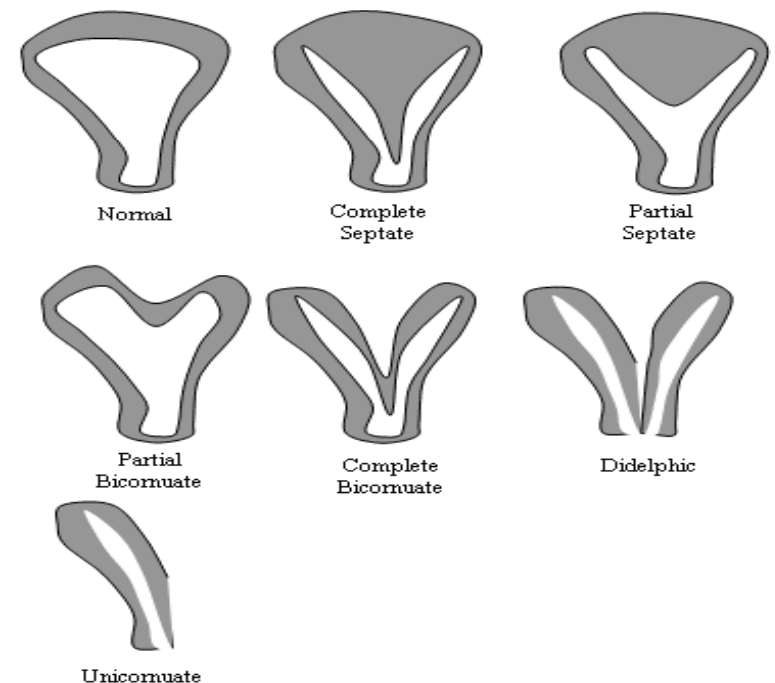
The American Fertility Society 1988



TELINDE'S OPERATIVE GYNECOLOGY MODIFIED CLASSIFICATION

(BASED ON EMBRIOLOGIC CONSIDERATION)

**This classification
consider only complete
septum or partial. The
term “arcuate uterus”
has been abandoned,
considered to be a
radiologic diagnosis**



TELINDE'S OPERATIVE GYNECOLOGY MODIFIED CLASSIFICATION

(BASED ON EMBRIOLOGIC CONSIDERATION)

Class I: Dysgenesis of Mullerian Ducts: includes agenesis of uterus and vagina (Mayer –Rokitansky-Kuester- Hauser syndrome)

Class II: Disorders of the Vertical Fusion of the Mullerian Ducts: transverse vaginal septum, cervical agenesis or dysgenesis

Class III: Disorders of the Lateral Fusion of the Mullerian Ducts: can be symmetric – unobstructed or asymmetric - obstructed. Obstructive forms associated with absence of ipsilateral kidney. Bilateral obstruction associated with bilateral kidney agenesis- nonviability of the embryo.

Three asymmetric obstructions

Unicornuate uterus, Unilateral obstruction of a cavity of double uterus, Unilateral vaginal obstruction

Five symmetric unobstructed disorders

Didelphic ut., Septate ut., Bicornuate ut., T shaped and unicornuate with rudimentary horn

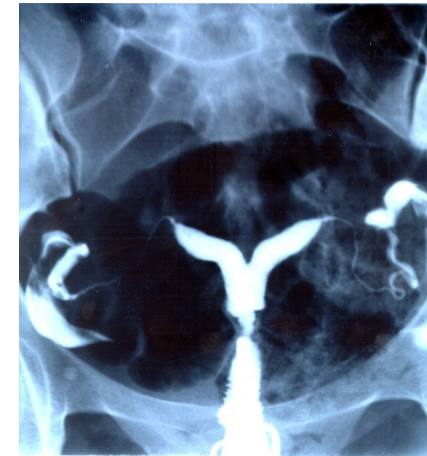Class IV: Unusual Configuration of Vertical - Lateral Fusion Defects: unusual configuration of abnormalities

WHICH IS THE BEST DIAGNOSTIC TOOL?



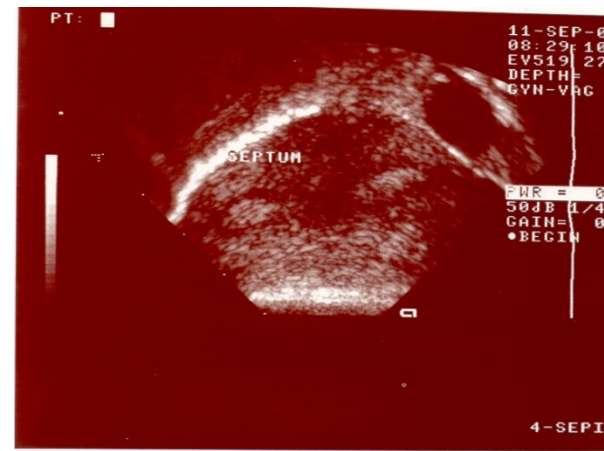
HSG: Characterization of uterine anomalies can be difficult, however, especially regard to differentiation of a septate from a bicornuate uterus

(Pellerito 1992)



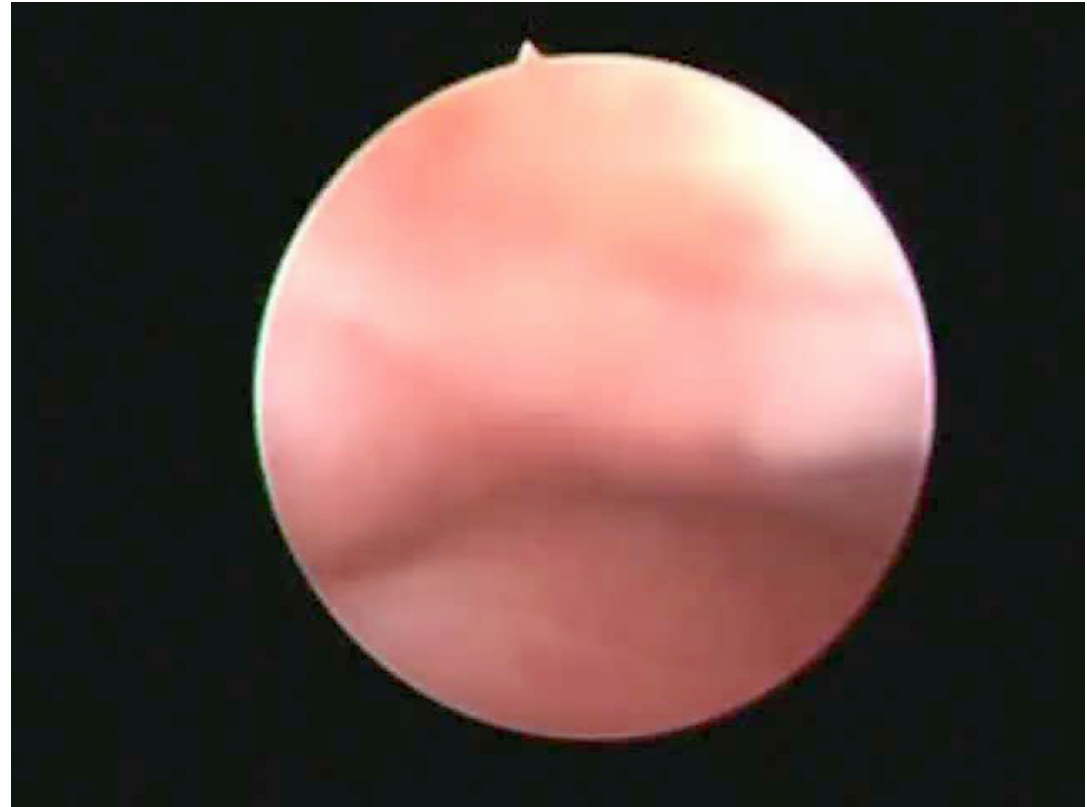Vaginal US: reported accuracy of approximately 90%–92%

(Pellerito 1992)



Diagnostic “office” hysteroscopy

- No speculum and tenaculum
- Visual confirmation of US findings
- Elective in case of uncertain ultrasound
- High compliance of patients. No need of anesthesia or analgesia.



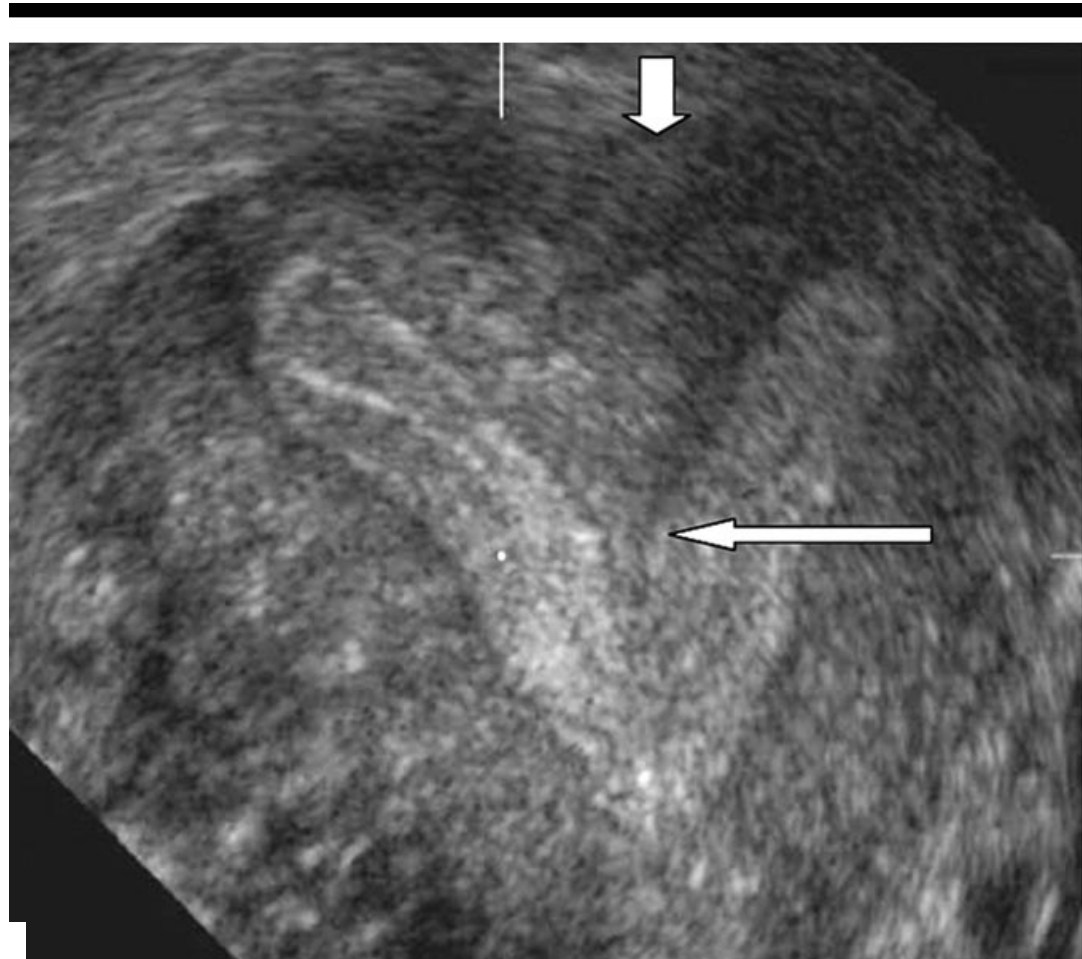
3D US

3D ultrasound is a reproducible method for the diagnosis of congenital uterine anomalies and for the measurement of uterine cavity dimensions.

(Salim et al. 2003)

In experienced hands, a sensitivity of 93% and a specificity of 100% have been achieved

(Kupešić and Kurjak 2000)



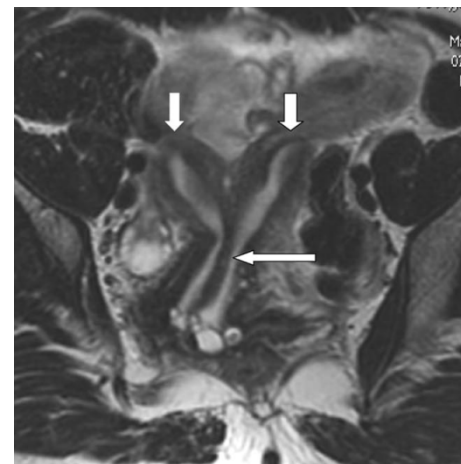
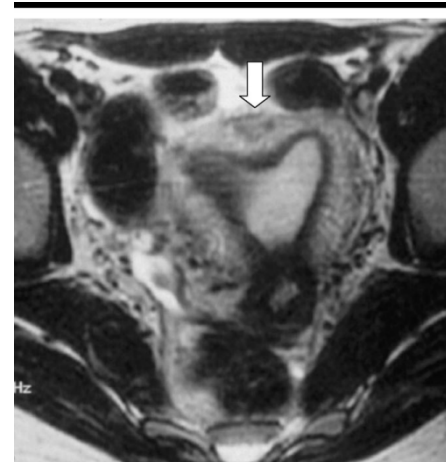
MRI

Magnetic resonance (MR) imaging has a reported accuracy of up to 100% in the evaluation of muellerian duct anomalies

(Fedele et al. 1989)

Complex anomalies and secondary diagnoses such as endometriosis can often be optimally characterized noninvasively.

(Troiano and McCarty 2004)



WHEN IS IT NECESSARY TO TREAT?



When is necessary to treat?

Pregnancy outcome in untreated patients

Author	Miscarriage	Preterm d.
Fayez 1986	90.5 %	9.5 %
Perino 1987	88.9 %	11.1 %
Daly 1989	86.7 %	8.7 %
Grimbizis 1998	31.7 %	14.5 %

Pregnancy outcome after metroplasty

Author	Miscarriage	Preterm d.
Perino 1987	9.1 %	0 %
Daly 1989	20.2 %	6.0 %
Fedele 1993	15.2 %	15.2 %
Grimbizis 1998	25.0 %	4.5 %




Author	N. cases	Conclusions
Heinonen et al 2000	17	Women with uterine anomalies who underwent ART had low implantation rates
Pabuçcu et al 2004	61	11% spontaneous misc. after metroplasty (9 cerclage)
Dendrinios et al. 2005	411	Treatment significantly reduced the miscarriage rate
Pace et al.2006	40	75 % spontaneous pregnancy achieved
Kormanyos et al. 2006	94	Removal even of small residual septa > 1 cm after metroplasty
Ban & Tomažević et al 2007	31	Resection of <i>small</i> uterine septa, improves implantation rate in IVF cycles.



MATERIALS AND METHODS

- 159 couples have been carried out because of unexplained primary infertility. 112 women with septate or arcuate uterus underwent hysteroscopic metroplasty.
- Patients were divided according to the uterine indentation. Since no definition in literature clearly defines the cut off value between septate and arcuate uterus, patients with a uterine indentation of 1,5 cm or more were arbitrarily included in the subseptate uterus group, whereas those with an indentation smaller than 1,5 cm were included in the arcuate uterus group.
- The duration of infertility and the pregnancy outcome after metroplasty were compared between the two groups.

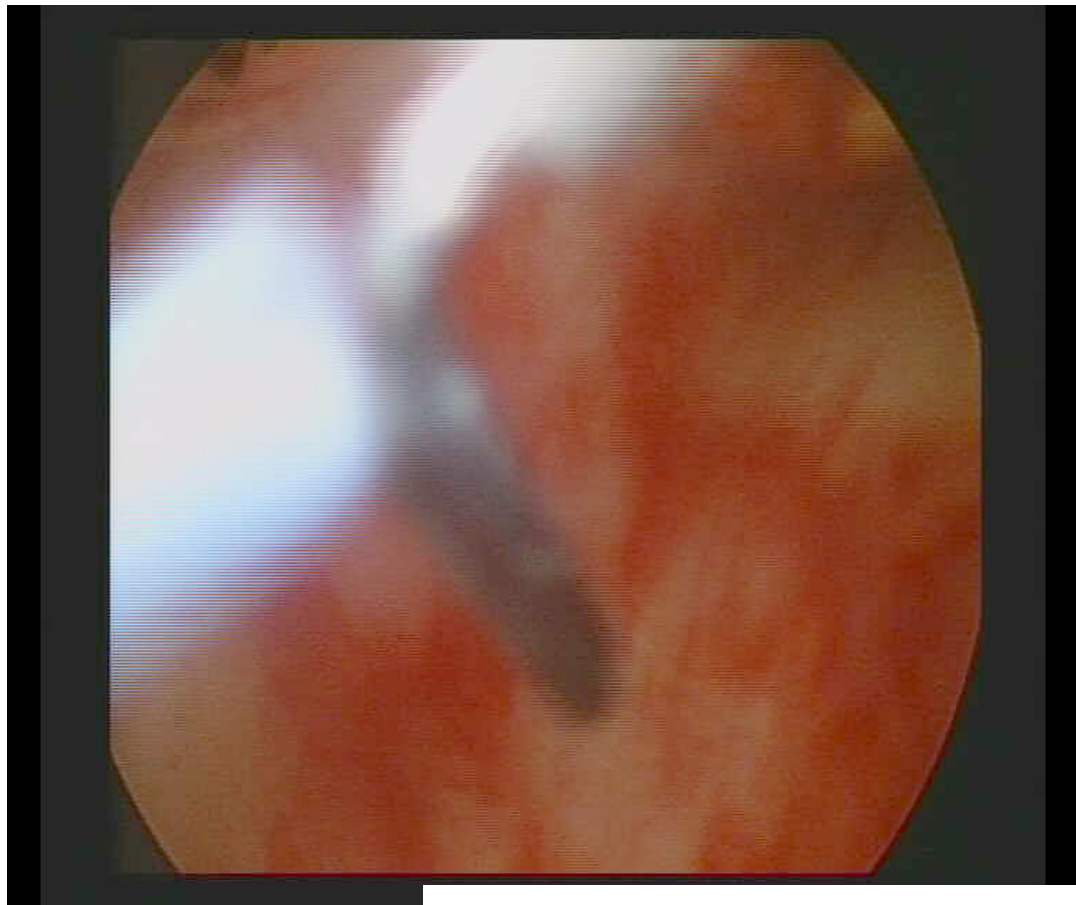


Preparation of endometrium:
Contraceptive pill till 10 days
before metroplasty
(synchronization)

8 mm monopolar operative
hysteroscope with 1,5 % glicine or 5
% glucose solution as distension
medium
or a bipolar resectoscope and
saline solution as distension
medium.


No postoperative complications

Day surgery




STATISTICS

- Kolmogorov - Smirnov test showed an abnormal distribution of the variables “months of infertility before surgery” and “months of infertility after surgery”. Due to this abnormal distribution the Wilcoxon Mann Whitney non-parametric test was used for analyzing those variables. Differences between groups were analyzed by the Pearson’s χ^2 test.

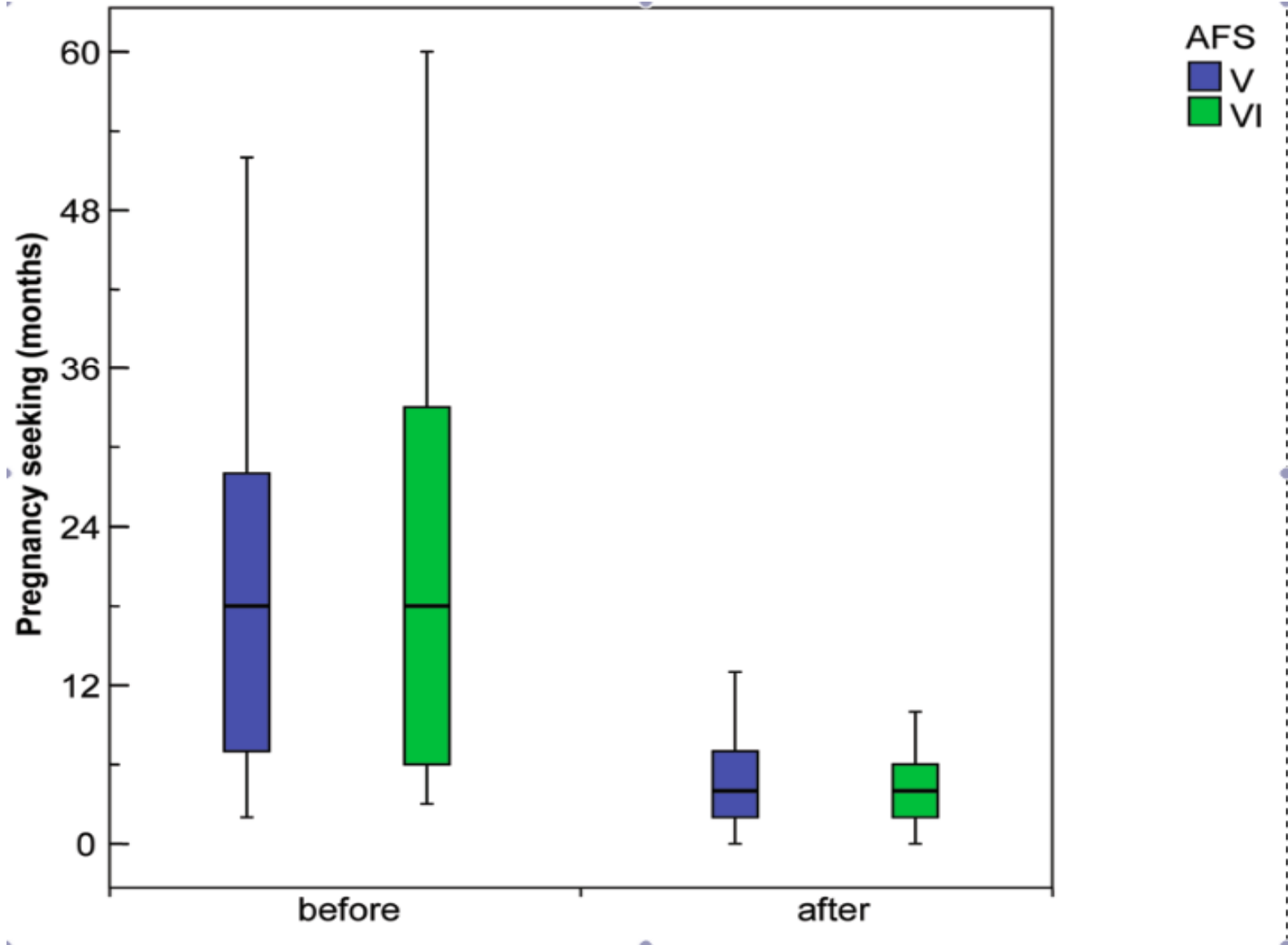


RESULTS 1

- The average age of patients in the subseptate uterus group was 31,4 years vs. 31,43 years in the arcuate uterus group (n.s.), body mass index (BMI) was 20,56 vs. 20, 89 (n.s.).



RESULTS




RESULTS

- The average age of women that conceived after metroplasty (118 women) was 31.4 ± 4.5 , the average age of those who did not conceive (61 women) was 31.43 ± 4.3 , (n.s.),
- BMI was 20.56 ± 3.0 vs. 20.89 ± 2.8 (n.s.).
- 15 abortions (10.6 %) and 2 ectopic pregnancies (1.4 %) were recorded.

CONCLUSIONS

- No differences have been found between women with subseptate uterus and those with arcuate uterus, either in the infertility time before metroplasty or in the outcome after metroplasty..




	Larger septum (Group 1) n.= 204		Smaller septum (Group 2) n.= 84	
Outcome	Before metroplasty	After metroplasty	Before metroplasty	After metroplasty
Pregnancy seeking Months (median and range)	18 (2-120)	4.9 (0-40)	18 (3-108)	4.4 (1-25)
Pregnancies	157	150 (137 women)	52	59 (55 women)
Deliveries	32 (20.4 %) a	121 (80.7 %) b	6 (11.5 %) c	51 (86.4 %)d
Miscarriages	118 (75.2%)	25 (16.7 %)	39 (75 %)	8 (13.6 %)
Ectopic	7 (4.5%)	4 (2.7 %)	7 (13.4 %)	0

Statistics

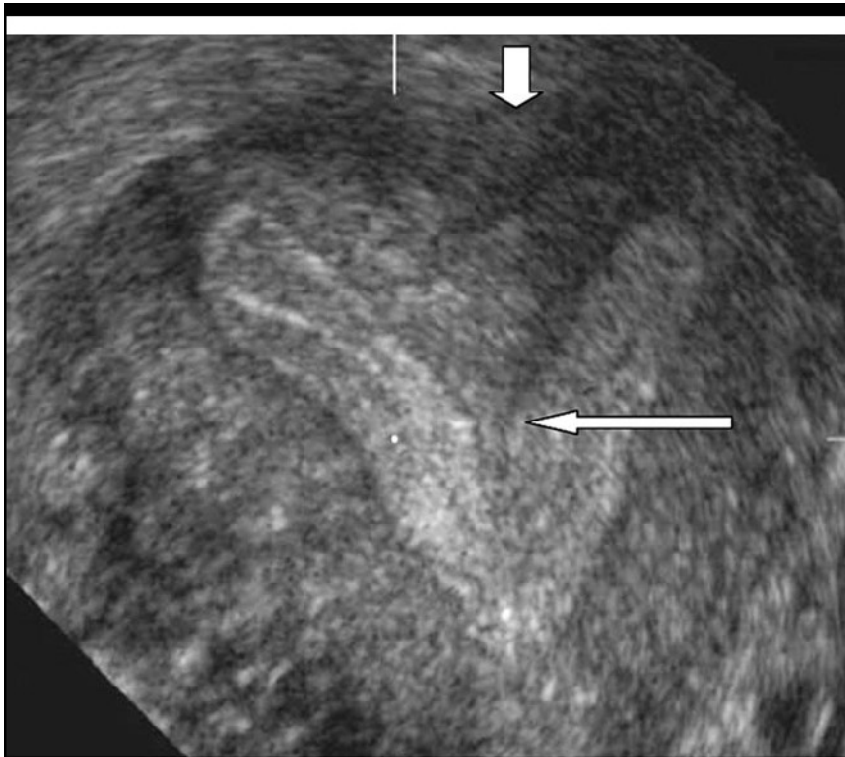	Group 1, before vs. after metroplasty	Group 2, before vs. after metroplasty	Before metroplasty, Group 1 vs. Group 2	After metroplasty, Group 1 vs. Group 2
Pregnancy seeking duration (Mann Whitney test)	p < 0.001	p < 0.001	n.s.	n.s.
Pregnancy failure rate (χ^2 test)	p < 0.001	p < 0.001	n.s.	n.s.

WHY SEEMS TO BE INDIPENDENT FROM THE SIZE?



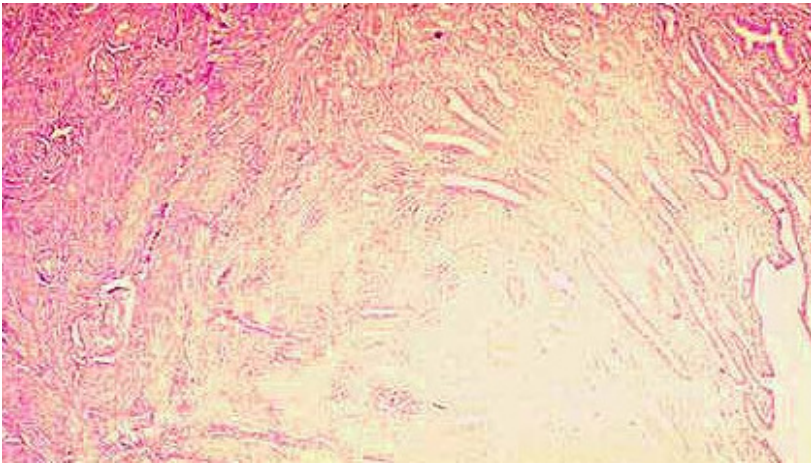
MRI ULTRASTRUCTURE

- MRI intensity similar to the myometrium (Carrington et al 1990)



ka et al. 2003

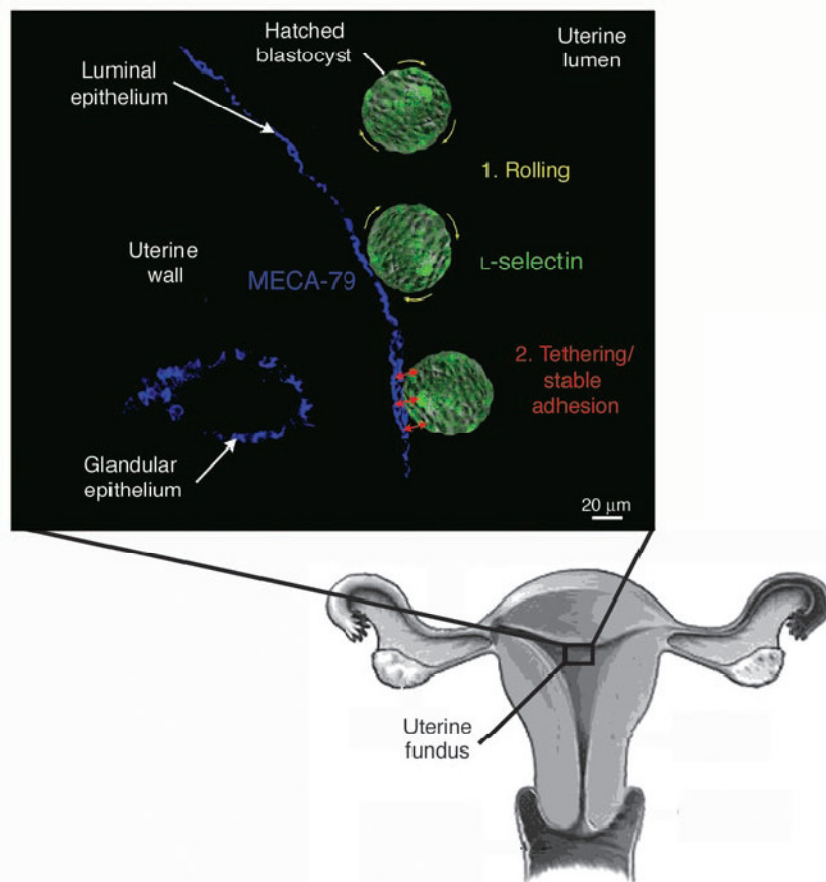
ENDOMETRIUM COVERING SEPTUM




- Fedele described a morphological alteration of mucosa covering the septum (Fedele et al. 1996).



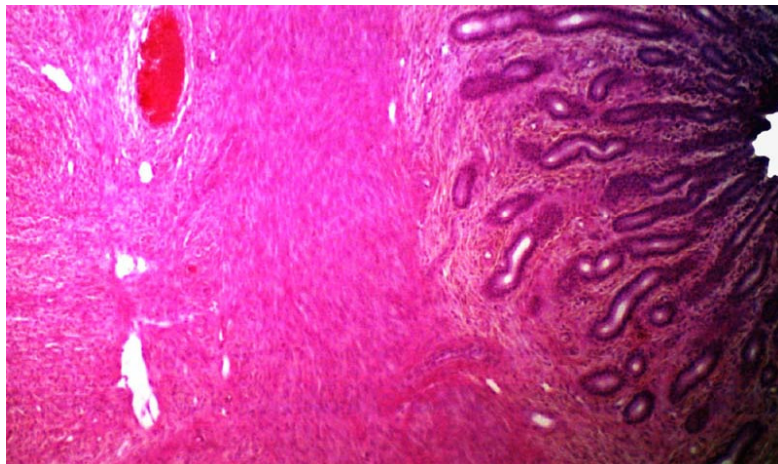
ROLLING AND TETHERING



The mechanism of the trophoblast invasion has analogies with the rolling and tethering of leucocytes on blood vessels. (Red-Horse et al. 2004). Could be that septum covering endometrium cannot express ligands such MECA 79 recognized antibodies that recognize L selectin expressed on blastocyst surface (Red-Horse et al. 2004)



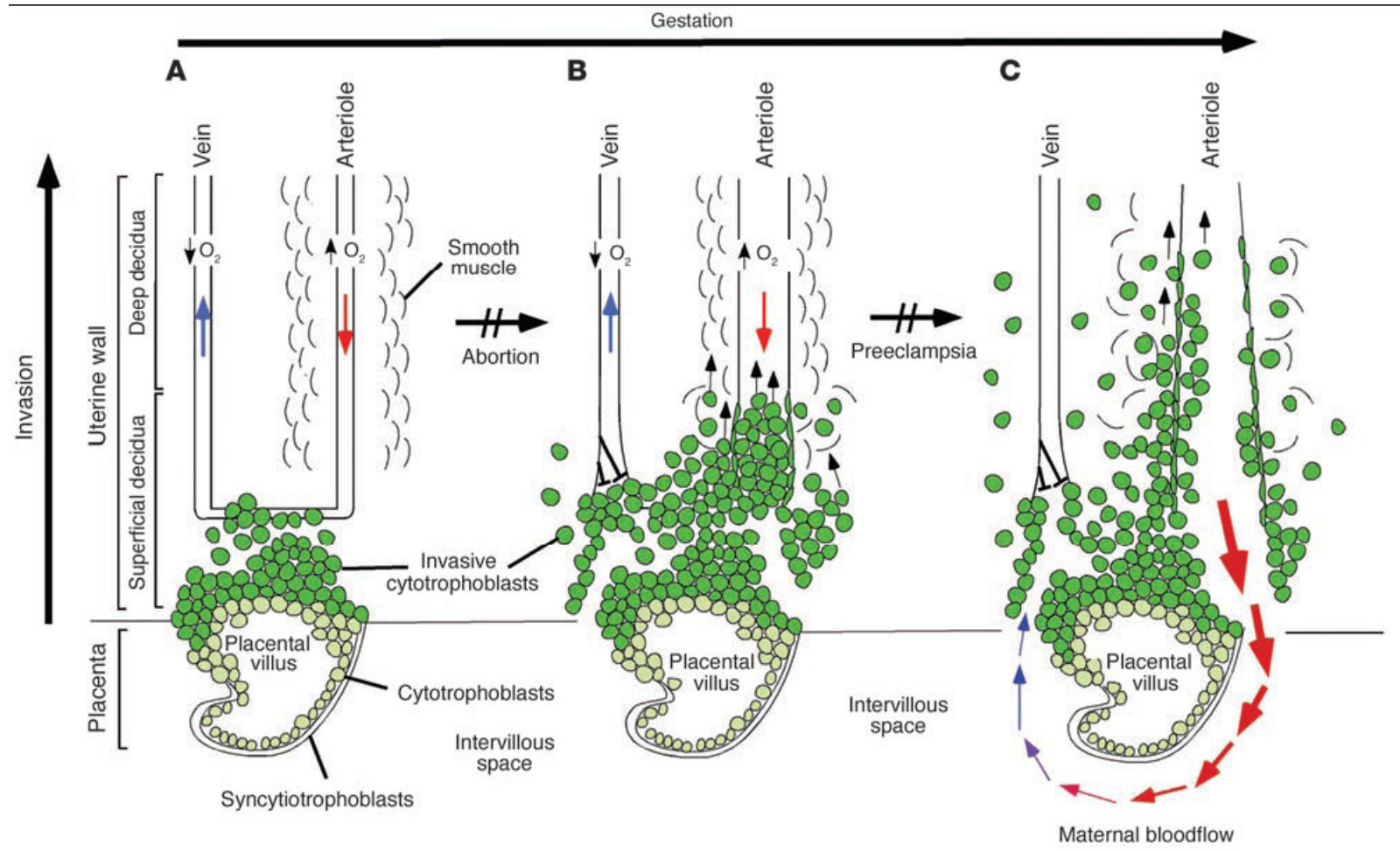
VASCULARIZATION



- Increased miscarriage rate could be consequence of a disrupted vascular architecture within septa (Fayez et al 1986)



INVASION OF UTERUS



CONCLUSION

No differences have been found between women with large septa and those with arcuate uterus either in the obstetric history before metroplasty or in the outcome after metroplasty. Further studies are needed to assess why the mechanisms that lead to miscarriage seem to be independent from the size of septum.

