

Impact of pregnancy on endometriosis

Yutaka Osuga

January 28, 2017

Holiday Inn Sofia, Sofia, Bulgaria

disclosure

I have nothing to disclose on this presentation.

Contents

Changes of endometriosis during pregnancy

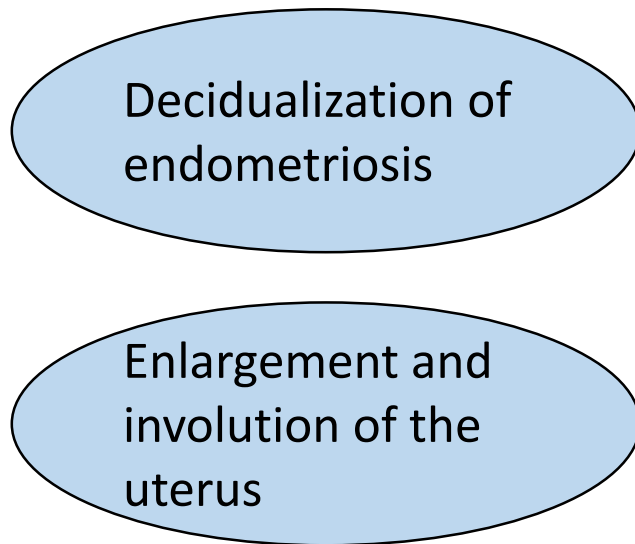
- Pregnancy and endometriosis (basic concepts)
- Ovarian endometrioma – decidualization
- Extra-ovarian endometriosis – decidualization

Complications

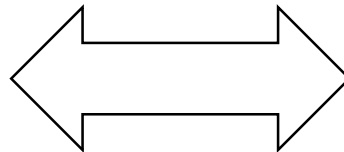
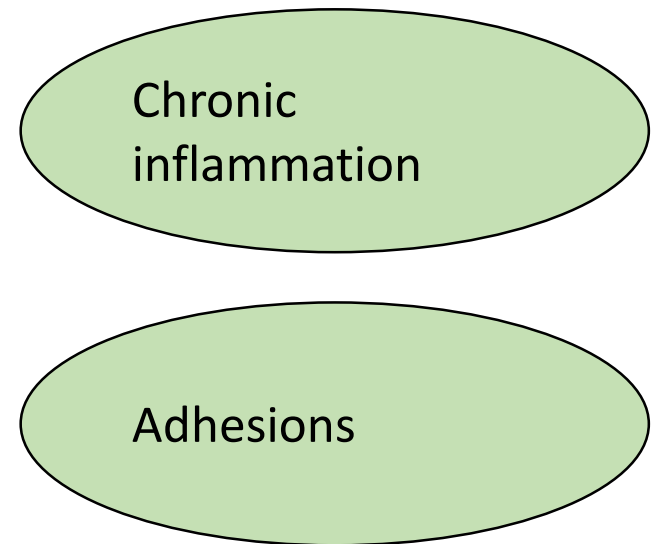
- Ovarian endometrioma – abscess, rupture
- Intestinal perforation, appendicitis, pneumothorax
- Spontaneous Hemoperitoneum in Pregnancy (SHiP)
- Uterine rupture

Pregnancy and endometriosis

Pregnancy-associated events



Endometriosis-associated events



Decidualization of endometriosis

- Endometriosis is characterized by progesterone resistance.
- Endometriotic tissues are refractory to be decidualized under menstrual cycles.
- Due to high serum levels of progesterone, endometriotic tissues are susceptible to decidualize during pregnancy.
- Decidualized endometriosis is characterized by typical sonographic, histological and molecular patterns.

Ovarian endometriosis in pregnancy

0.05–0.5%

Change of the size of ovarian endometrioma in pregnancy

- 52% decreased
- 28% unchanged
- 20% increased

among 25 ovarian endometriotic lesions observed during pregnancy in 24 women (one case had two lesions)

(Ueda Y, et al. Fertil Steril. 2010;94:78-84)

- 46% no cyst could be detected
(the initial mean \pm SD diameter: 15 \pm 5mm)
- 13% decreased
- 33% unchanged
- 8 % increased

among 24 women carrying 40 endometriomas

(Benaglia L, et al. Gynecol Endocrinol. 2013;29:863-6)

Change of the properties of ovarian endometrioma in pregnancy

- 12% (3 cases) decidualization
- 4% (1 case) abscess
- 4% (1 case) rupture

among 25 ovarian endometriotic lesions observed during pregnancy in 24 women (one case had two lesions)

(Ueda Y, et al. Fertil Steril. 2010;94:78-84)

- 0% decidualization

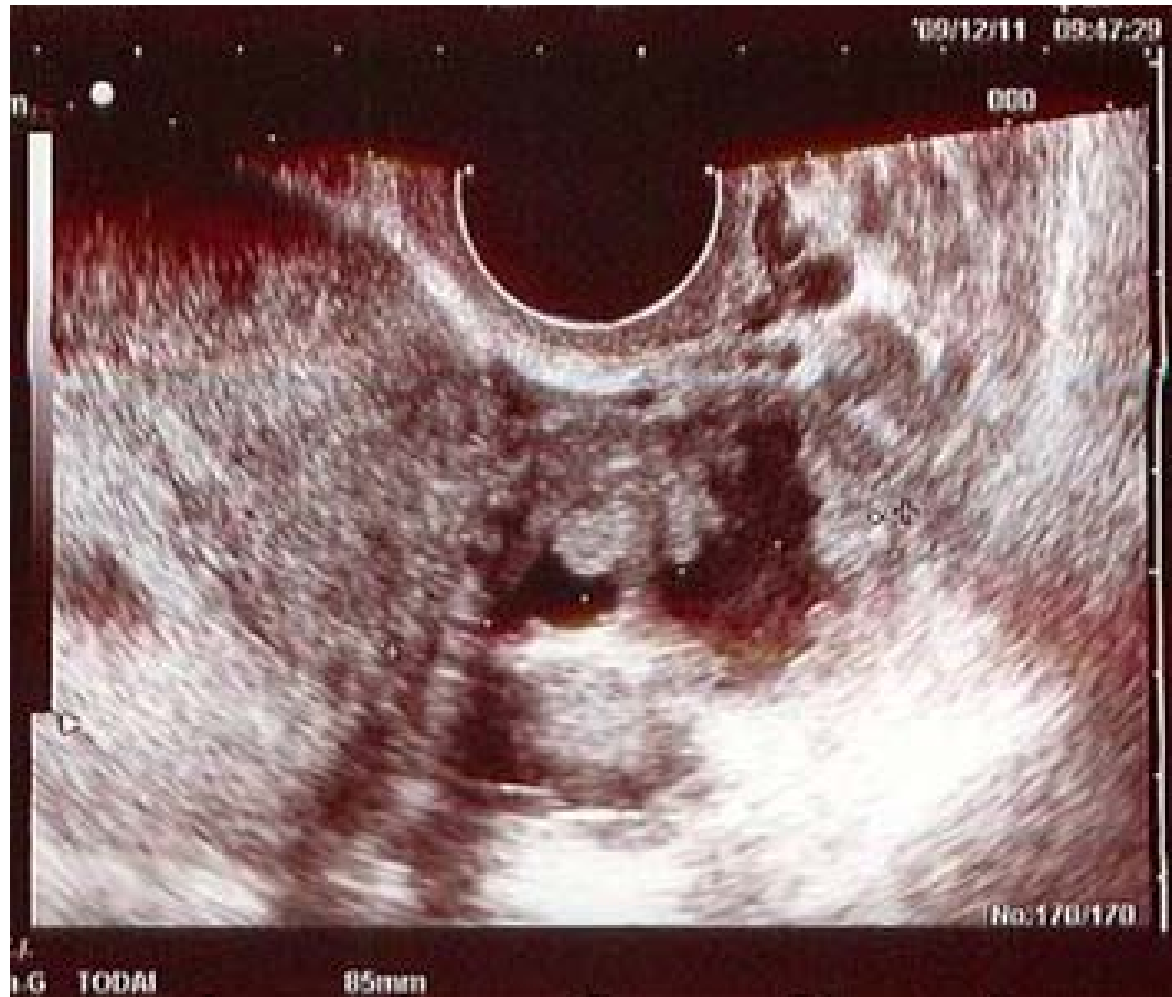among 24 women carrying 40 endometriomas

(Benaglia L, et al. Gynecol Endocrinol. 2013;29:863-6)

Case

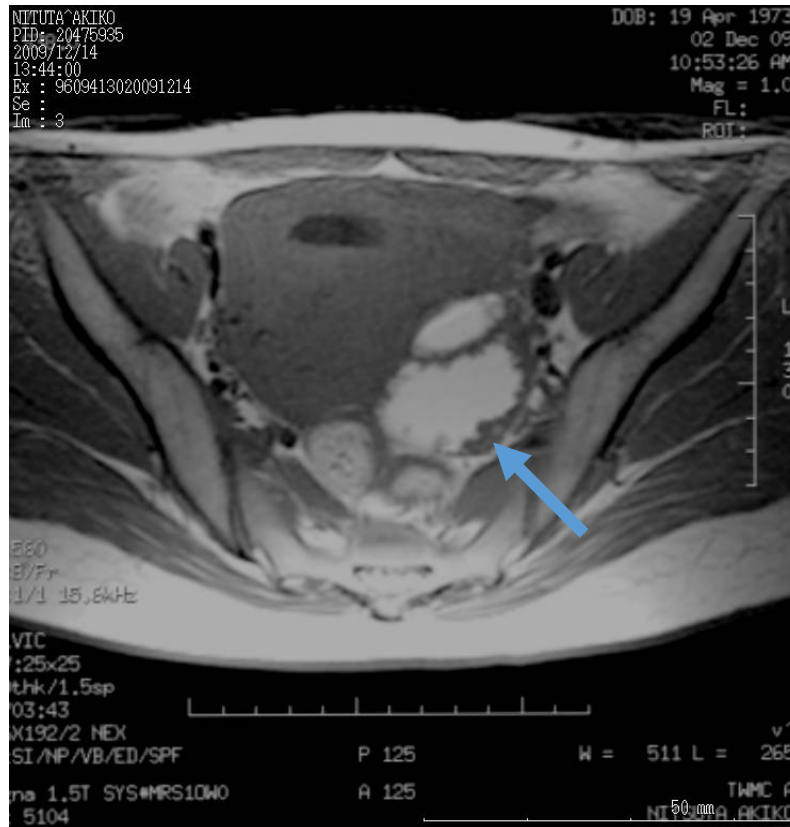
- 36 y.o. G0P0
- 2cm endometrioma detected just before pregnancy
- At 7w preg., 6cm endometrioma with solid part protruding into the cavity

Ultrasound image of decidualized endometrioma (preg. 9w)

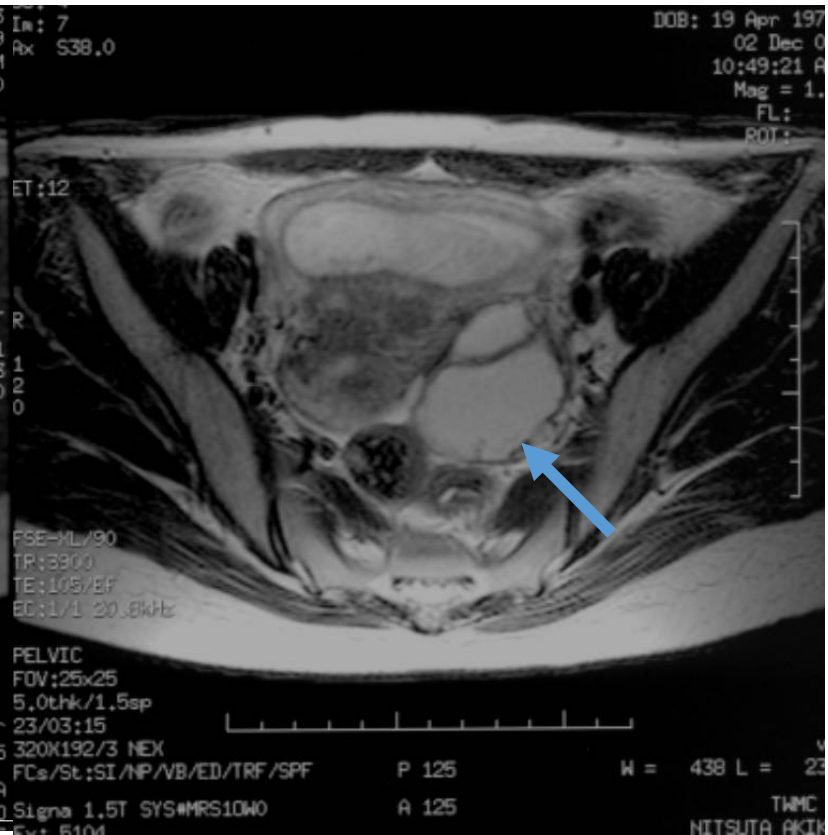


MRI of decidualized endometrioma (preg. 9w)

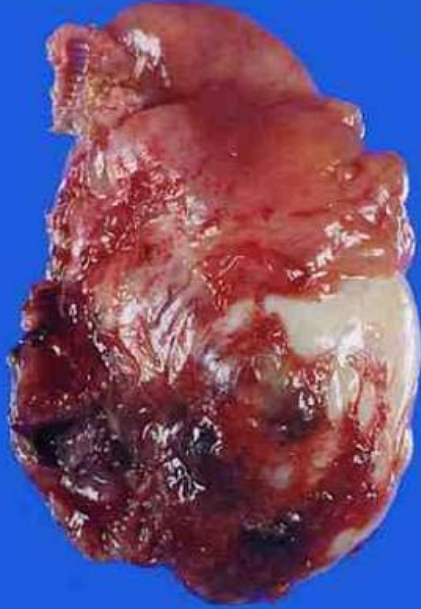T1WI



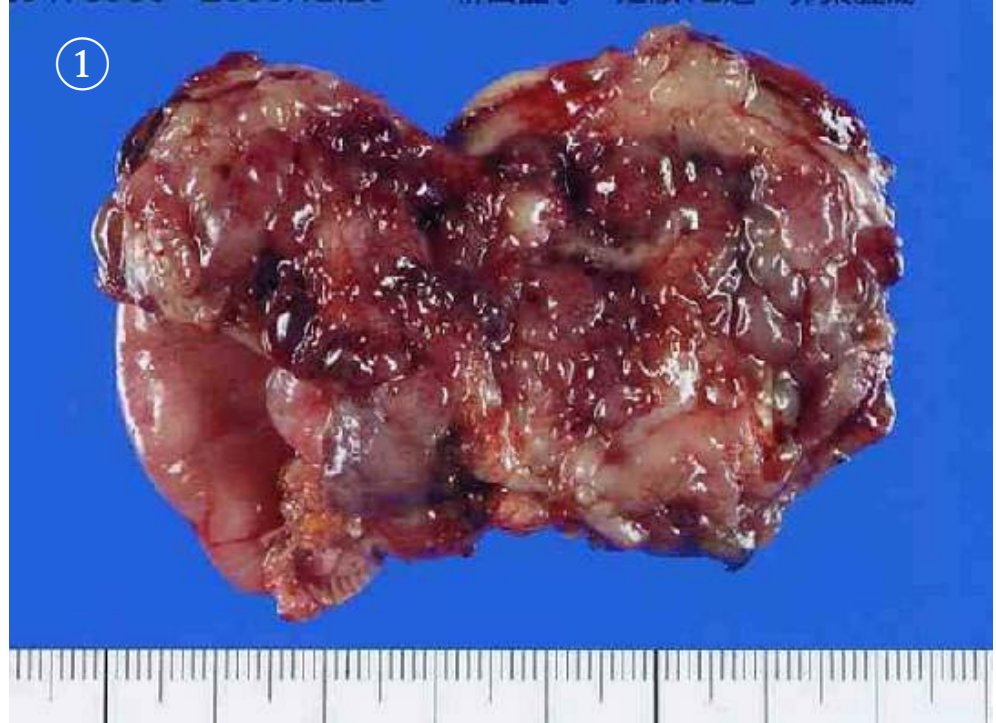
T2WI



gross findings

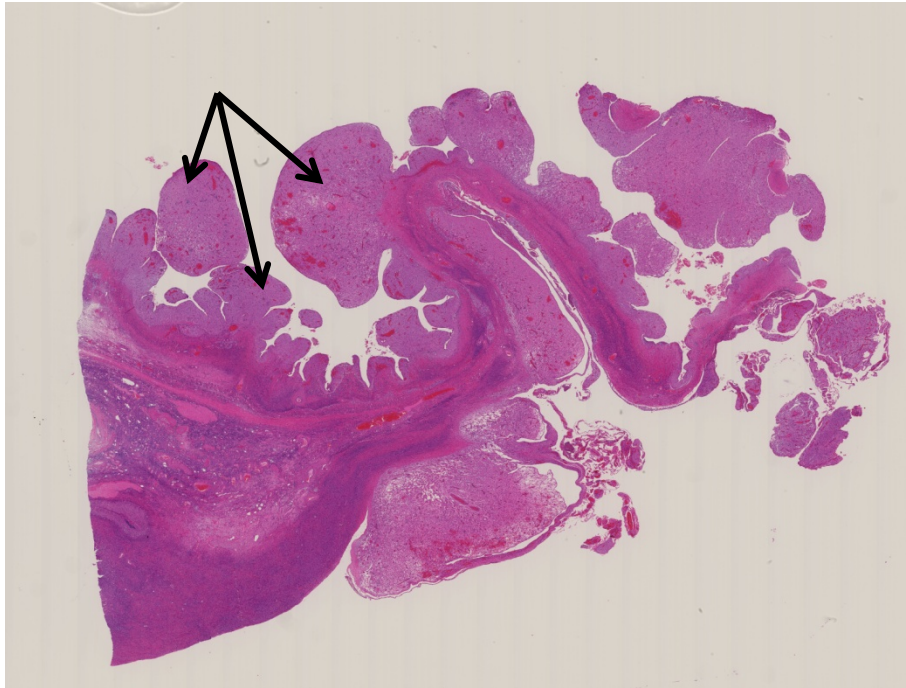


Outer surface

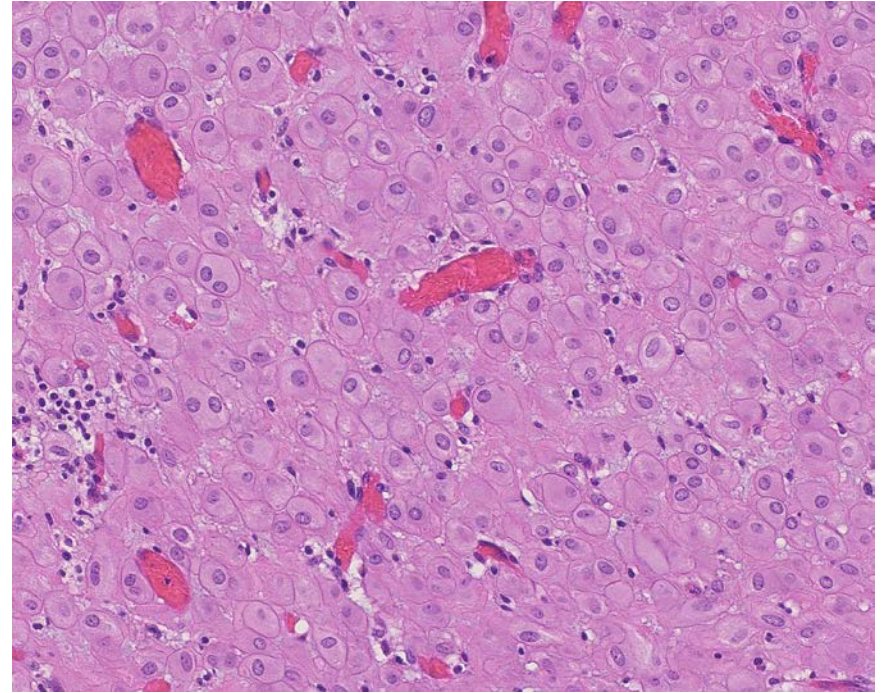


Inner surface

microscopic findings



low magnification



high magnification

Decidualization of ovarian endometrioma

- 17 studies, reporting a total of 60 cases, of ovarian decidualized endometriomas in pregnancy has been reported.

Leone Roberti Maggiore U, et al. Hum Reprod Update. 22:70-103. 2016

- Decidualized endometrioma may in some cases resemble malignant ovarian tumors.
- Malignant ovarian tumors among ovarian masses in pregnancy is ~1%.

Bromley B, et al. J Ultrasound Med. 16:447-452; Leiserowitz GS, et al. Gynecol Oncol. 101:315-321. 2006

Sonographic findings of endometrioma during pregnancy

95%

- A typical sonographic appearance: a round shaped cystic aspect, regular margins, homogeneous low echogenic fluid content, scattered internal echoes and absence of papillae.

5%

- An atypical aspect: anechoic content, solid appearance, and presence of punctuate echogenic foci within the cystic wall.

(Patel MD, et al. Radiology. 210:739-745. 1999; Barbieri M, et al. Hum Reprod. 24:1818-1824. 2009)

Decidualization of ovarian endometrioma

- sonographic findings -

- Typically, a decidualized endometrioma appears as a cystic mass containing rounded vascularized papillary projections with smooth contour and with a ground glass or low-level echogenicity cystic content.
- The majority of cases shows an increased blood flow at color Doppler sonography.
- Contrary to malignant tumors, the presence of septations is uncommon and their absence could be considered a reassuring sign.
- Free pelvic fluid is usually absent.
- The absence of growth in these patients, followed up with serial sonographic evaluations, might be considered another reassuring sign.

Decidualization of ovarian endometrioma

- MRI findings -

- On T2-weighted images, prominent hyperintense mural nodules is highly suggestive for decidualization.

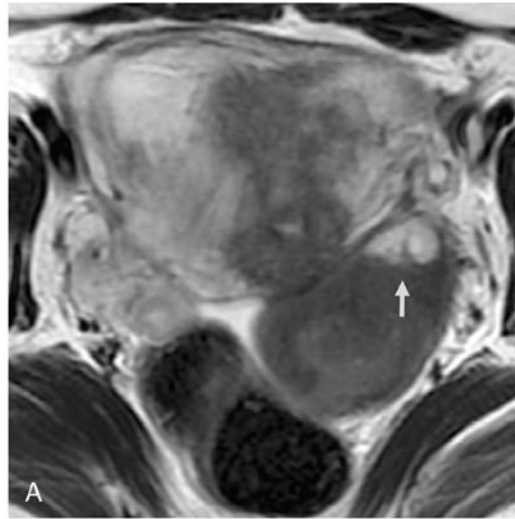
(Takeuchi M, et al. J Comput Assist Tomogr. 32: 353-5. 2008)

- The apparent diffusion coefficient (ADC) is significantly higher for decidualized endometrial tissues as compared with malignant ovarian tumors, probably due to the edematous vascularized nature of endometrial tissue with abundant cytoplasm of stromal cells.

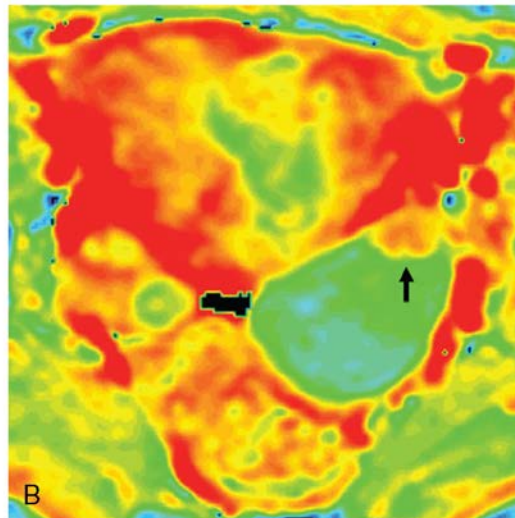
(Takeuchi M, et al. J Comput Assist Tomogr. 32: 353-5. 2008;
Morisawa N, et al. J Comput Assist Tomogr. 38: 879-84. 2014)

A 32-year-old pregnant woman with left ovarian decidualized endometrioma.

T2-weighted image



ADC map



Treatment

- An actual dilemma between expectant management and surgical intervention.
- Decision should be made by balancing the level of malignant suspicion, gestational age, and fetal and maternal risks.
- Pregnancy outcome in the patients who underwent surgery has been reported to be uneventful in nearly all of the cases.
- In all the reported cases, all patients underwent laparotomy for surgery.

Leone Roberti Maggiore U, et al. Hum Reprod Update. 22: 70-103. 2016

- Surgery-related risks are reported to increase after 23 weeks' gestation.

Whitecar MP, et al. Am J Obstet Gynecol. 181: 19-24. 1999

Usui R, et al. J Obstet Gynaecol Res. 26: 89-93. 2000

Decidualized endometriosis in extra-ovarian sites - cutaneous endometriosis -

- 7 cases reported (4 cases at Cesarean scar, 2 at umbilicus, and 1 at vulva).
- The lesion was excised in most of the cases.
- The lesion can potentially be mistaken for malignancy.
- A history of cyclical pain, the typical lesion enlargement occurring during pregnancy, the shape of the nodules with smooth rounded borders and their non-infiltrative nature may help for the diagnosis.

Decidualized endometriosis in extra-ovarian sites - the bladder -

- 5 cases reported (biopsy in 4 cases and partial cystectomy in 1 case)
- Decidualization of the lesion can cause its rapid growth, simulating a bladder tumor.
- Differential diagnoses include benign bladder polyp, bladder leiomyoma, bladder cancer and placenta percreta.

Complications of a pre-existing endometriosis during pregnancy - mechanisms -

- Adhesions (due to endometriosis itself or surgery)
 - ⇒ traction on surrounding structures
- Endometriosis-associated chronic inflammation
 - ⇒ tissue destruction and tissue weakness
- Decidualization
 - ⇒ edema, vascular remodeling and angiogenesis

Ovarian endometrioma

- abscess -

- Only three cases have been reported.
- Symptoms of an infected endometrioma are those of an acute abdomen, i.e., lower abdominal pain, high fever, vomiting, and elevated white blood cell count.
- Pain on pressure at endometrioma by manual exam may help diagnosis.
- The treatment of a tubo-ovarian abscess includes peritoneal washing followed by cyst drainage, cystectomy, or salpingo-oophorectomy.

Ovarian endometrioma

- rupture -

- 14 cases
- Age: 32 ± 6.4 years (mean \pm SD; range, 44–25 years).
- 13 singleton pregnancies, 1 twin pregnancy
- 14% in the first trimester, 36% in the second trimester, and 43% in the third trimester
- Lower abdominal pain was reported by all the patients, with no side dominance and with clinical features of acute abdomen.

Ovarian endometrioma

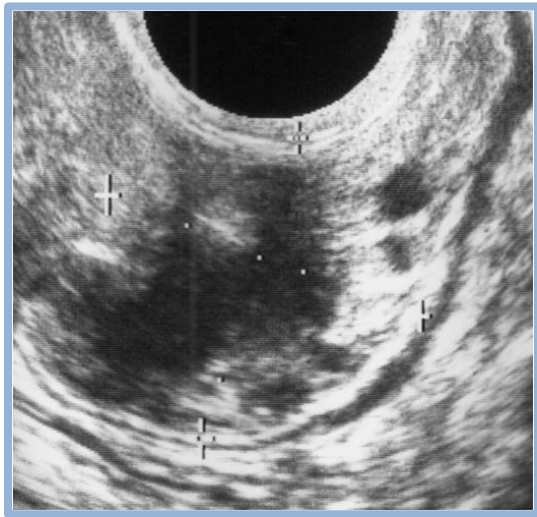
- rupture -

(cont'd)

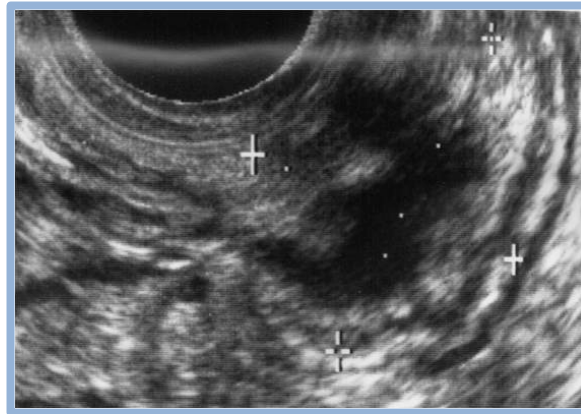
- 93% (13/14) underwent surgery during pregnancy:
 - unilateral salpingo-oophorectomy (4/13)
 - unilateral or bilateral cystectomy (6/13)
 - cyst drainage (1/13)
 - hysterectomy and salpingo-oophorectomy after Cesarean delivery (2/13)
- 69% decidualized endometriosis was confirmed by histological examination
- 12 cases of live birth, one intrauterine death at 37 weeks' gestation and one termination of pregnancy.

Case

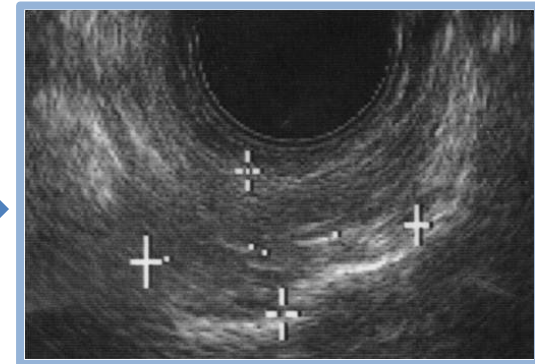
- Rectal endometriosis decreased during pregnancy.



First visit
Hematochezia
dyschezia



After two month
GnRHa treatment



After childbirth

Pregnancy

Intestinal perforation

- 16 cases of bowel perforation (13 during pregnancy, 3 in the post-partum period)
- ileum (n = 1), appendix (4), cecum (1), sigmoid colon (8) and rectum (2).
- mostly in the third trimester (30 ± 6.3 weeks).
- clinical and laboratory signs of peritonitis in 13 patients (81%).
- decidualized endometriosis involving the entire intestinal wall in 14 cases (88%).
- 100% live births

Appendicitis

- 7 cases of appendiceal endometriosis presenting as acute appendicitis during pregnancy
- gestational age at diagnosis: 20 ± 9.8 weeks
- the most frequent presenting symptoms: nausea (29%), vomiting (43%) and abdominal pain (86%).
- In all cases reported in the literature, the patients underwent appendectomy during pregnancy.

Pneumothorax

- 4 cases
- gestational age at diagnosis: 8, 18, 24 and 28 weeks.
- shortness of breath in all four cases and also with chest pain in two cases.
- catamenial pneumothorax before pregnancy in two cases
- management: 3 thoracotomies, 1 thoracoscopy

Schoenfeld A, et al. Obstet Gynecol Surv. 41:20-24. 1986

Flieder DB, et al. Hum Pathol. 29:1495-1503. 1998

Yoshioka H, et al. Jpn J Thorac Cardiovasc Surg. 53:280-282. 2005

Kim YD, et al. Thorac Cardiovasc Surg. 58:429-430. 2010

Case

29 y.o. G2P0

diagnosed with endometriosis at 20 y.o.

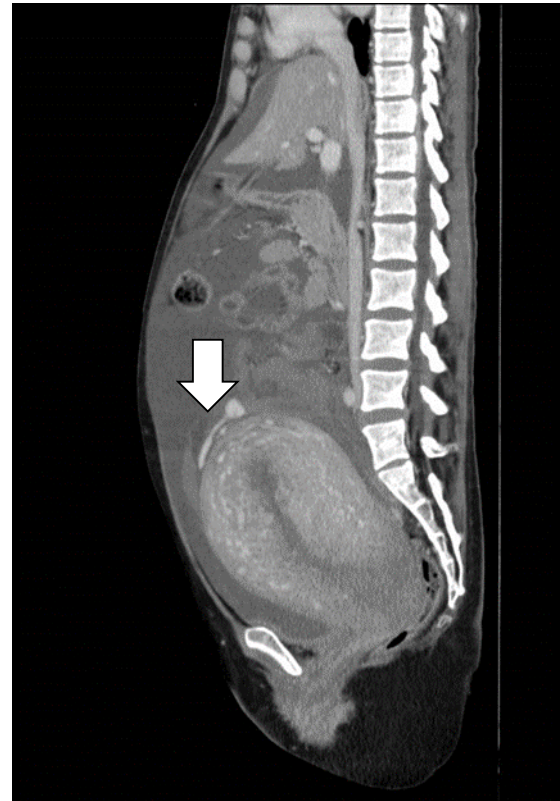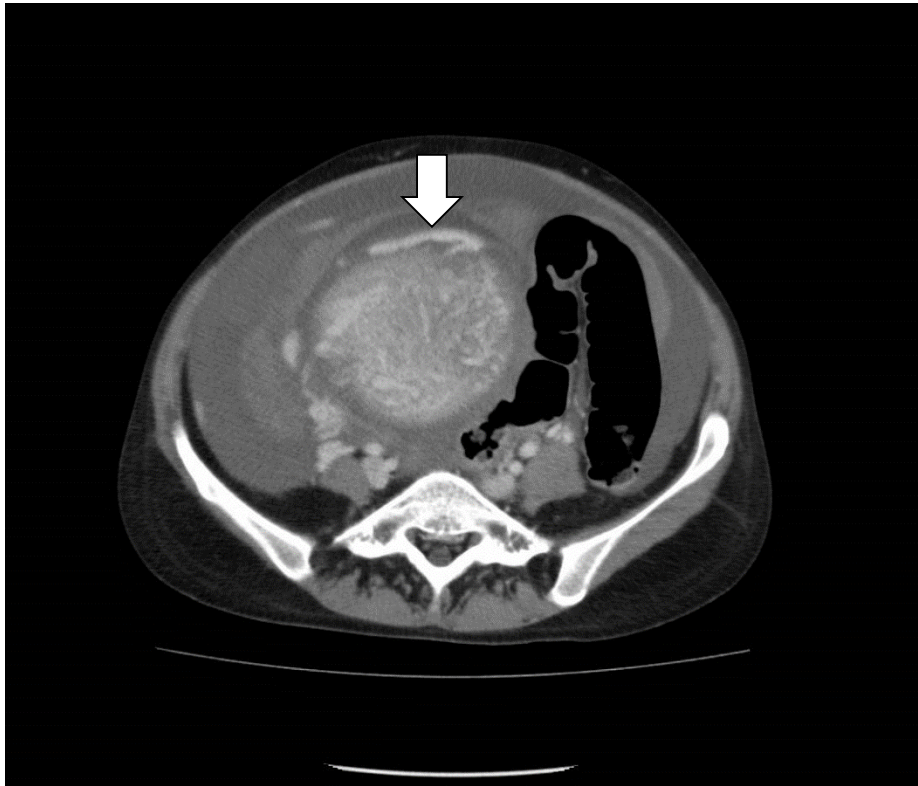
36w2d smooth vaginal delivery (pregnancy with IVF-ET)

Shock 90 min after delivery (sBP 60 mmHg, PR 120/min)

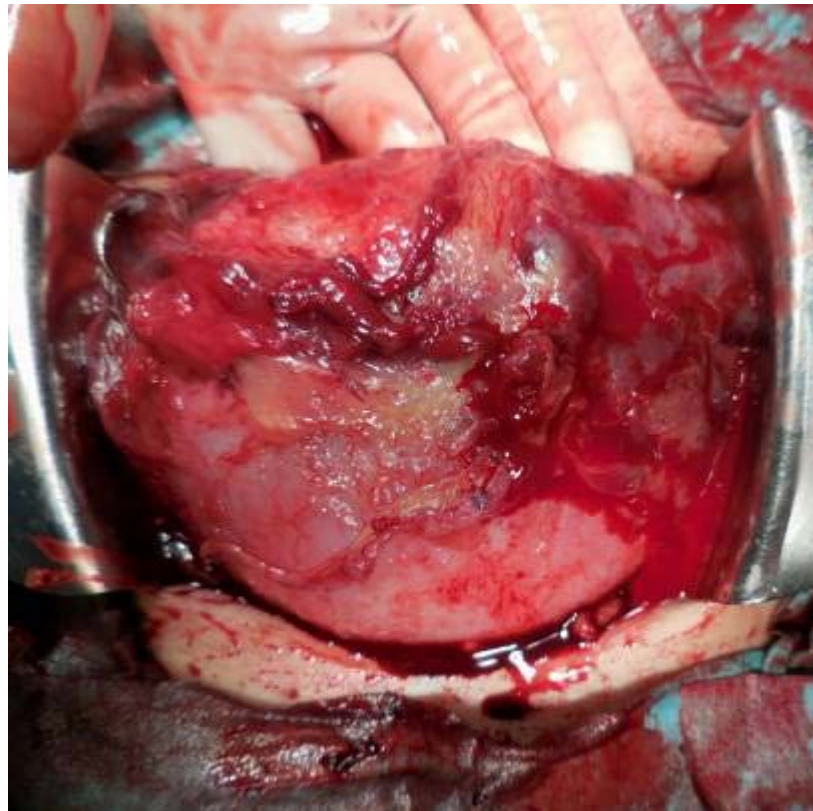
Hb3.7g/dl (after fluid resuscitation)

blood transfusion

contrast-enhanced CT



Fundus of the uterus



Spontaneous Hemoperitoneum in Pregnancy (SHiP) - prevalence -

0.38% (3/800)

in the endometriosis clinic at the University of Tel Aviv

Katorza E, et al. Am J Obstet Gynecol. 197:501.e501-504. 2007

0.35% (2/573)

Zhang Y, et al. Fertil Steril. 92:395.e313-396. 2009

Spontaneous Hemoperitoneum in Pregnancy (SHiP)

- review -

- 20 cases of endometriosis-related SHiP (in 16 publications)
- Most cases in the third trimester (28.7 ± 4.3 wks, mean \pm SD) and 4 cases (20%) in the post-partum period
- Symptom: sudden onset of abdominal pain with different localizations (95%)
- Sign: hypovolemic shock (70%)

Spontaneous Hemoperitoneum in Pregnancy (SHiP)

- diagnosis and different diagnosis -

- In 40% of the cases, the presumed preoperative diagnosis was placenta abruption with concealed hemorrhage (75%) and a uterine rupture (25%).
- In most cases, the diagnosis of ruptured utero-ovarian vessel was established at explorative laparotomy that was carried out in the 90%.

Spontaneous Hemoperitoneum in Pregnancy (SHiP)

- outcome -

- bleeding site: 70% at the uterus, 15% at the parametrium with its arteries and veins, and 5% at the uterosacral ligament.
- No maternal death
- Perinatal mortality rate: 36% (7 cases of intrauterine death and 1 neonatal death)
- Histological examination was performed in 45% of cases, in which decidualization was diagnosed in 67% .

Uterine rupture

- 3 cases
- Previous endometriosis surgery in all cases. (excision of a rectovaginal nodule, bilateral ovarian cystectomy, and excision of cervical endometriosis)
- The rupture was localized on the posterior wall of the uterus at the lower segment level in all cases.
- In all cases healthy babies were born, and no maternal death was reported.

Van De Putte I, et al. Br J Obstet Gynaecol. 106:608-609. 1999
Sholapurkar SL, et al. Aust N Z J Obstet Gynaecol. 45:256-258. 2005
Chen ZH, et al. Taiwan J Obstet Gynecol. 50:95-97. 2011

Conclusion

Pregnancy has various impacts in women with endometriosis.

Although the incidence is low, endometriosis-related emergent events during pregnancy would be serious but can be managed well with knowledge about the impact of pregnancy on endometriosis.

3RD CONGRESS OF THE SOCIETY OF ENDOMETRIOSIS AND UTERINE DISORDERS

SEUD
CONGRESS
2017

**FIBROIDS
& UTERINE
BLEEDING:**
UNLOCKING THE ISSUES

2017
APRIL 6, 7, 8
SINGAPORE

Location

**SUNTEC Convention
& Exhibition Centre, Singapore**

Congress President

**Pr Yoke Fai Fong,
Singapore**

SEUD President

**Pr Charles Chapron,
France**



Society of Endometriosis and Uterine Disorders

WWW.SEUD.ORG