

Medical and surgical therapy in treating adenomyosis



Professor Charles Chapron, *M.D.*,
Doctor Anne-Elodie Millischer, *M.D.*,
Professor Dominique de Ziegler, *M.D.*,

University Paris Descartes,
Department of Obstetrics and Gynecology II and
Reproductive Medicine (Pr Chapron),
Cochin University Hospital, Paris, France

Adenomyosis: Definition

Two distinct forms:

- **Diffuse Adosis:** The invasion of endometrial glands and/or stroma within the myometrium
- **Focal Adosis:** Adenomyomata: circumscribed tumors made up of endometrium and muscle tissue

Adenomyosis: Prevalence

Wide variations:

< 20%

> 50%

Adenomyosis: Risk factors

- Menstrual and reproductive factors
- Health habits
- Surgical trauma

Adenomyosis: Diagnosis

- Hysterosalpingography
- Hysteroscopy
- Transvaginal ultrasonography
- Magnetic resonance imaging
- Myometrial biopsy

Adenomyosis: Therapy choices

- Medical treatments
- Surgical treatments

Adenomyosis: Therapy choices

- Medical treatments

- Surgical treatments

Adenomyosis: Medical treatments

- Levonorgestrel intrauterine system (LNG-IUD)

- Danazol – loaded intrauterine devices

- Gn-RH agonists

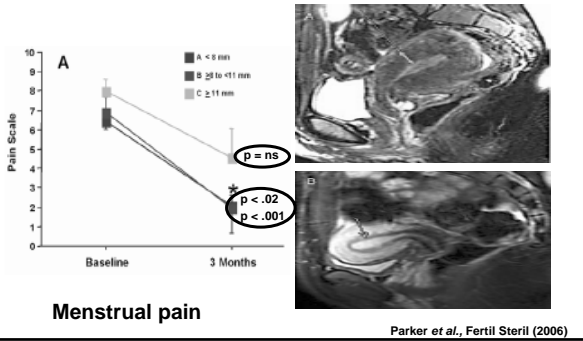
- Aromatase inhibitors

Adenomyosis: Therapy choices

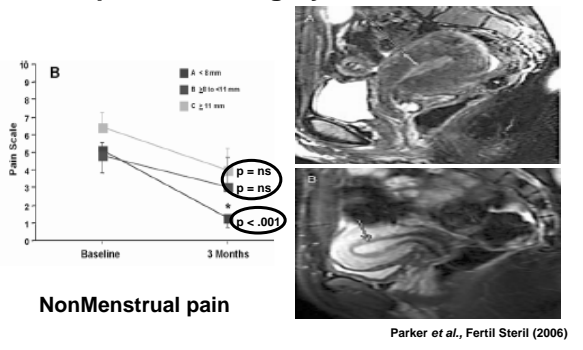
- Medical treatments

- Surgical treatments

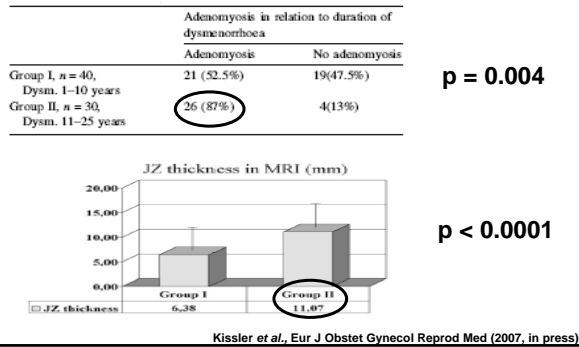
Pelvic pain after surgery for endometriosis

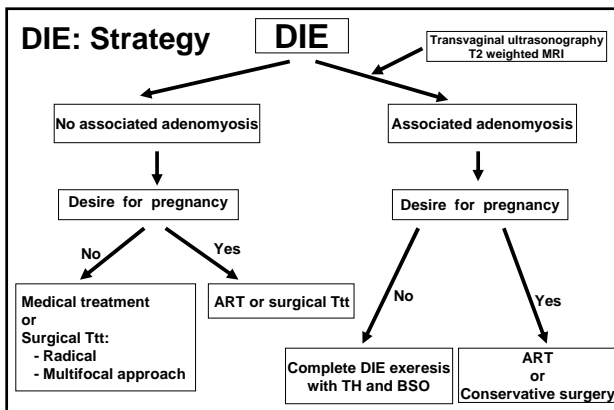


Pelvic pain after surgery for endometriosis



Duration of DM and extent of Adenomyosis







Take home messages



Associated adenomyosis:

Preoperative diagnosis: T2 weighted MRI

Strategy:
 No desire for pregnancy: Associated HT
 Infertility: ART or conservative surgery
