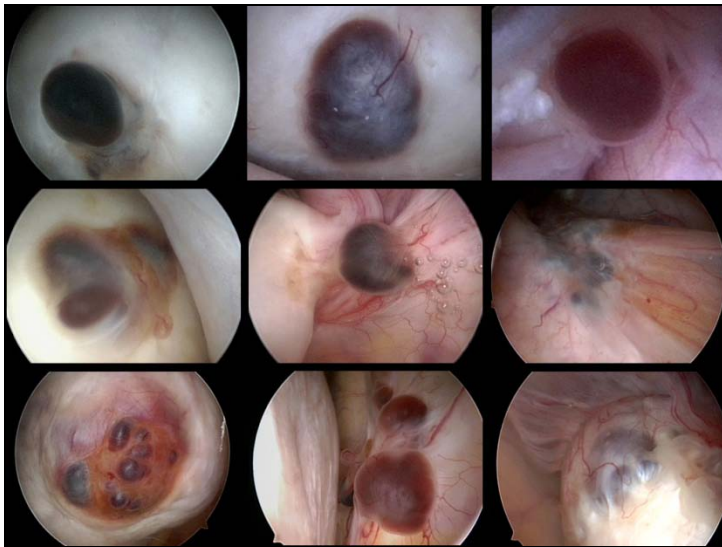

Transvaginal laparoscopy:
diagnosis and operative treatment of subtle
endometriotic lesions and adhesions.



Stephan Gordts

Edinburgh, 5 – 6 February 2013



L.I.F.E.

Leuven Institute for Fertility & Embryology

DISCLOSURE

Consultant

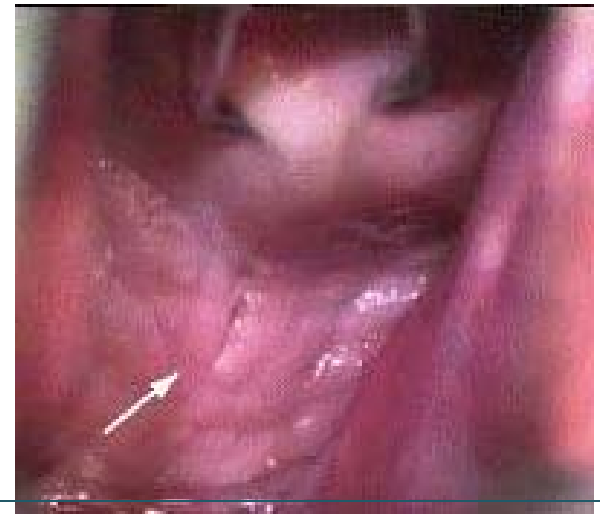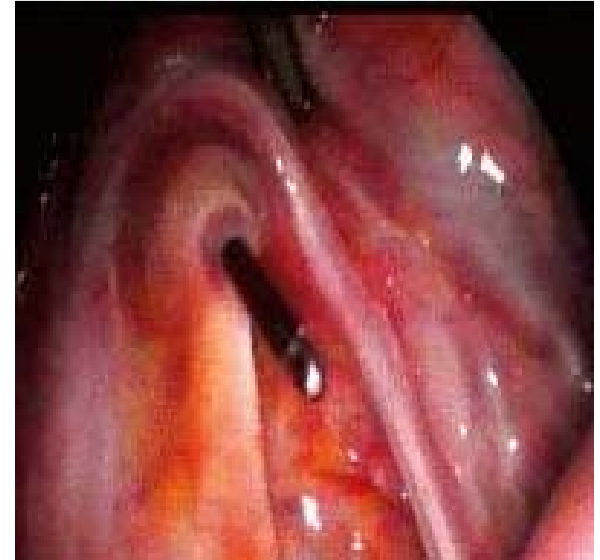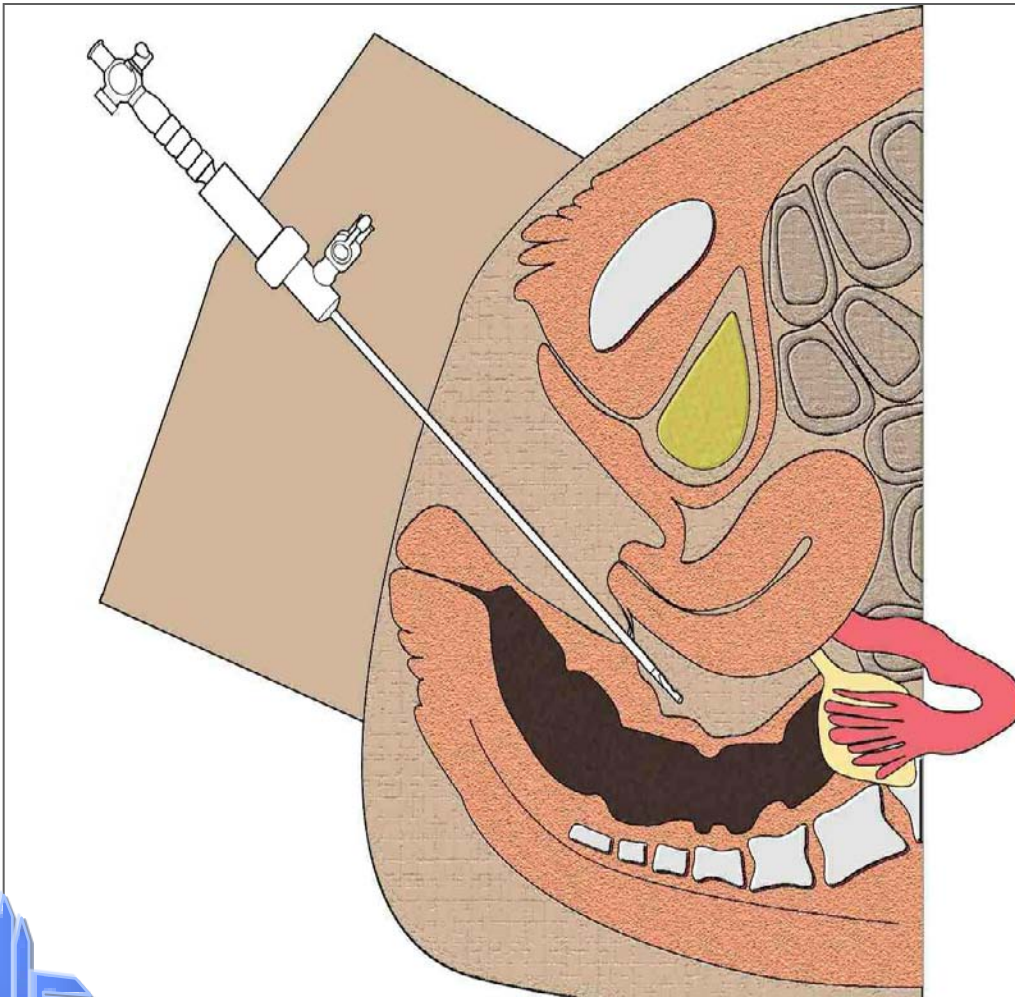
Karl Storz, Germany



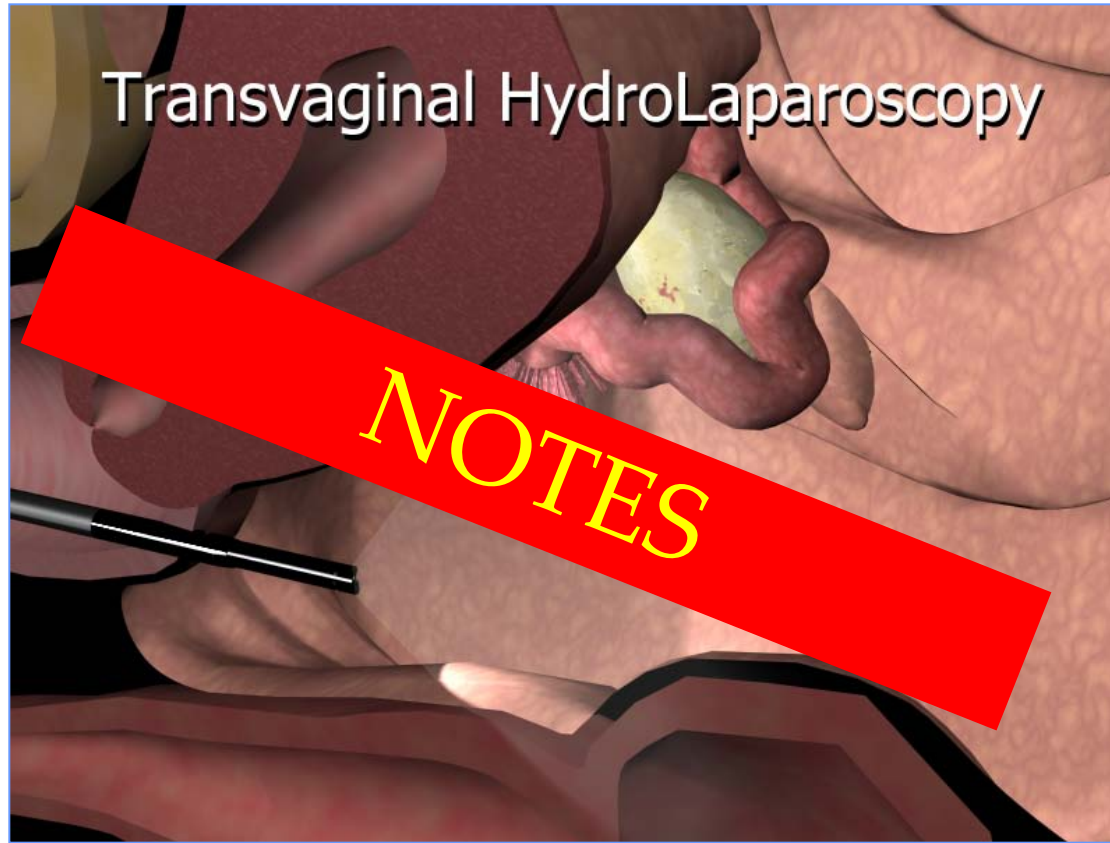
L.I.F.E.

Leuven Institute for Fertility & Embryology

TECHNIQUE



Transvaginal Endoscopy



L.I.F.E.

Leuven Institute for Fertility & Embryology

TRANSVAGINAL ENDOSCOPIC

EXPLORATION

Minimal invasive
Accuracy
Ambulatory setting

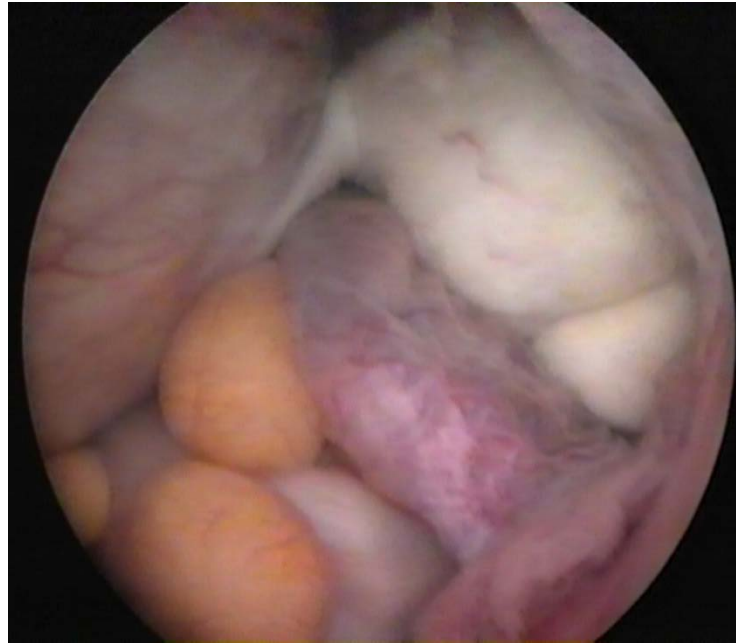
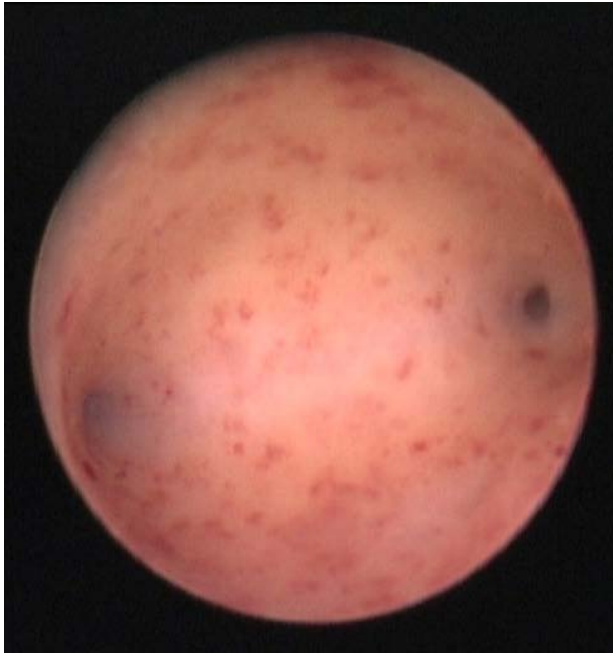
Implantation function
Pick-up and transport



L.I.F.E.

Leuven Institute for Fertility & Embryology

Mini endoscopes for minimal invasive approach



Hopkins, 30°, 2.9 mm



L.I.F.E.

Leuven Institute for Fertility & Embryology



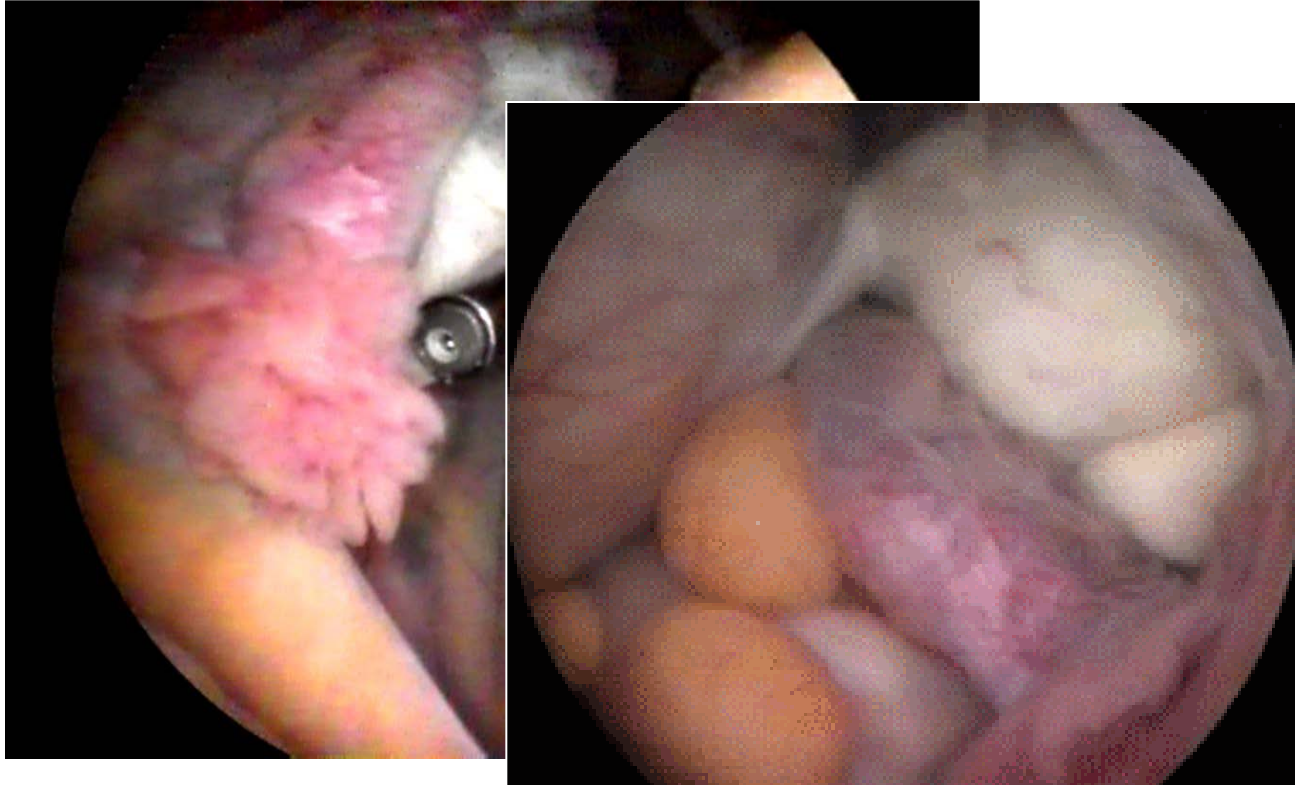
Instrumentation



STORZ
KARL STORZ — ENDOSKOPE



TRANSVAGINAL LAPAROSCOPY

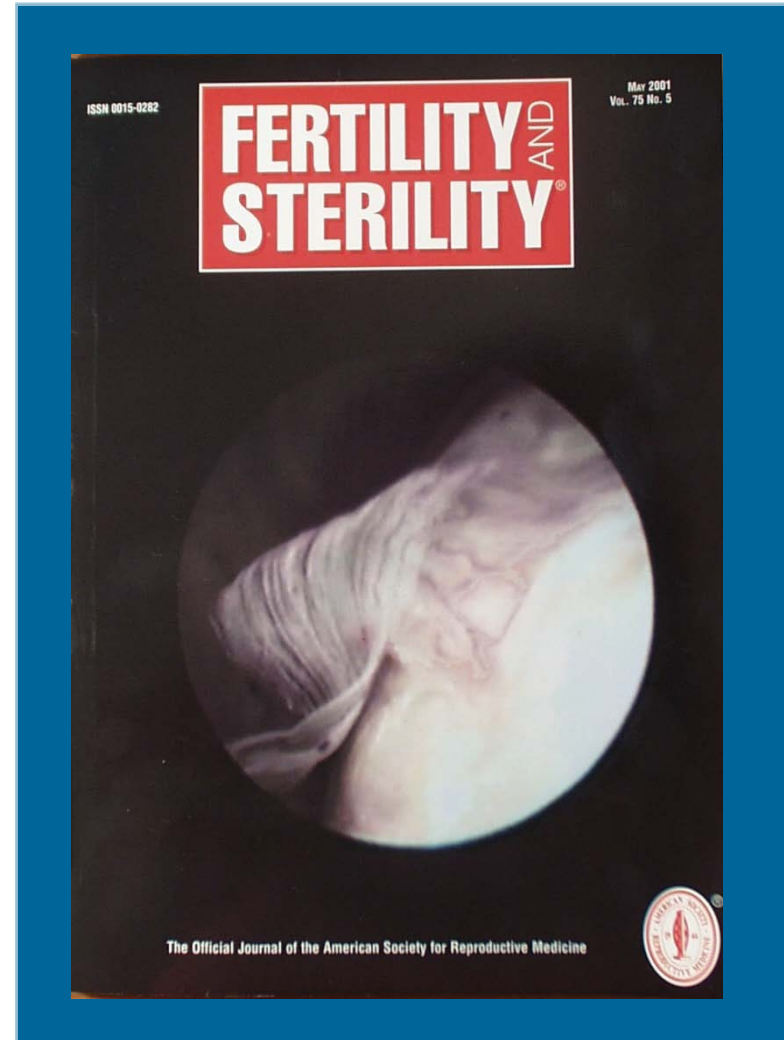
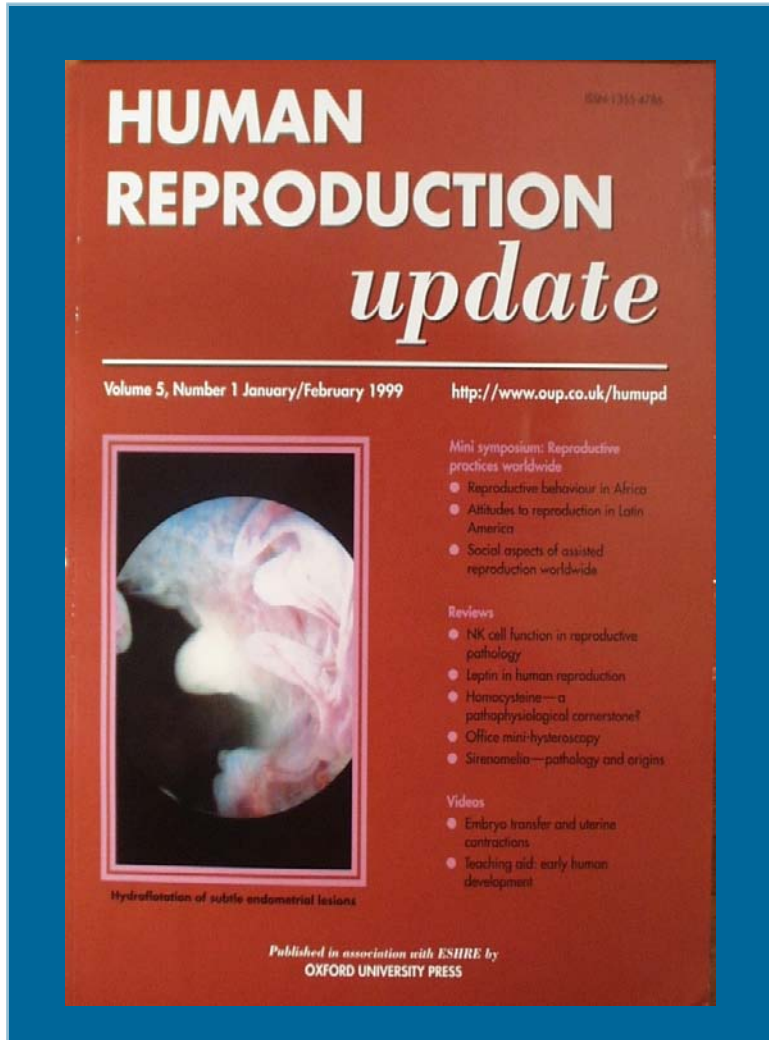


L.I.F.E.


Leuven Institute for Fertility & Embryology

TVE

Watery distension medium



TRANSVAGINAL LAPAROSCOPY



L.I.F.E.

Leuven Institute for Fertility & Embryology

TRANSVAGINAL LAPAROSCOPY

Bowel injuries and infections using a transvaginal access for pelviscopy

		Nb	Perf
		Inf	
Riva (1960)	2850	11	0
Diamond (1978)	4000	5	1
Gordts (2001)	3667	24	0
Current review	2843	10	0
Total	13360	50	1
			0.37%
		0.007%	

TRANSVAGINAL LAPAROSCOPY

Accuracy



L.I.F.E.

Leuven Institute for Fertility & Embryology

TRANSVAGINAL LAPAROSCOPY DIAGNOSTIC ACCURACY

Subtle (endometriotic) ovarian adhesions

		mild endometriosis	unexplained infertility
S. laparoscopy	40%		0%
Transv. laparoscopy		70%	45%



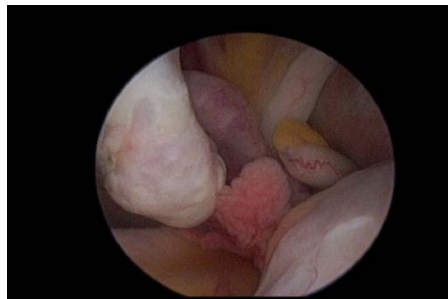L.I.F.E.

Leuven Institute for Fertility & Embryology

Advantages of transvaginal access

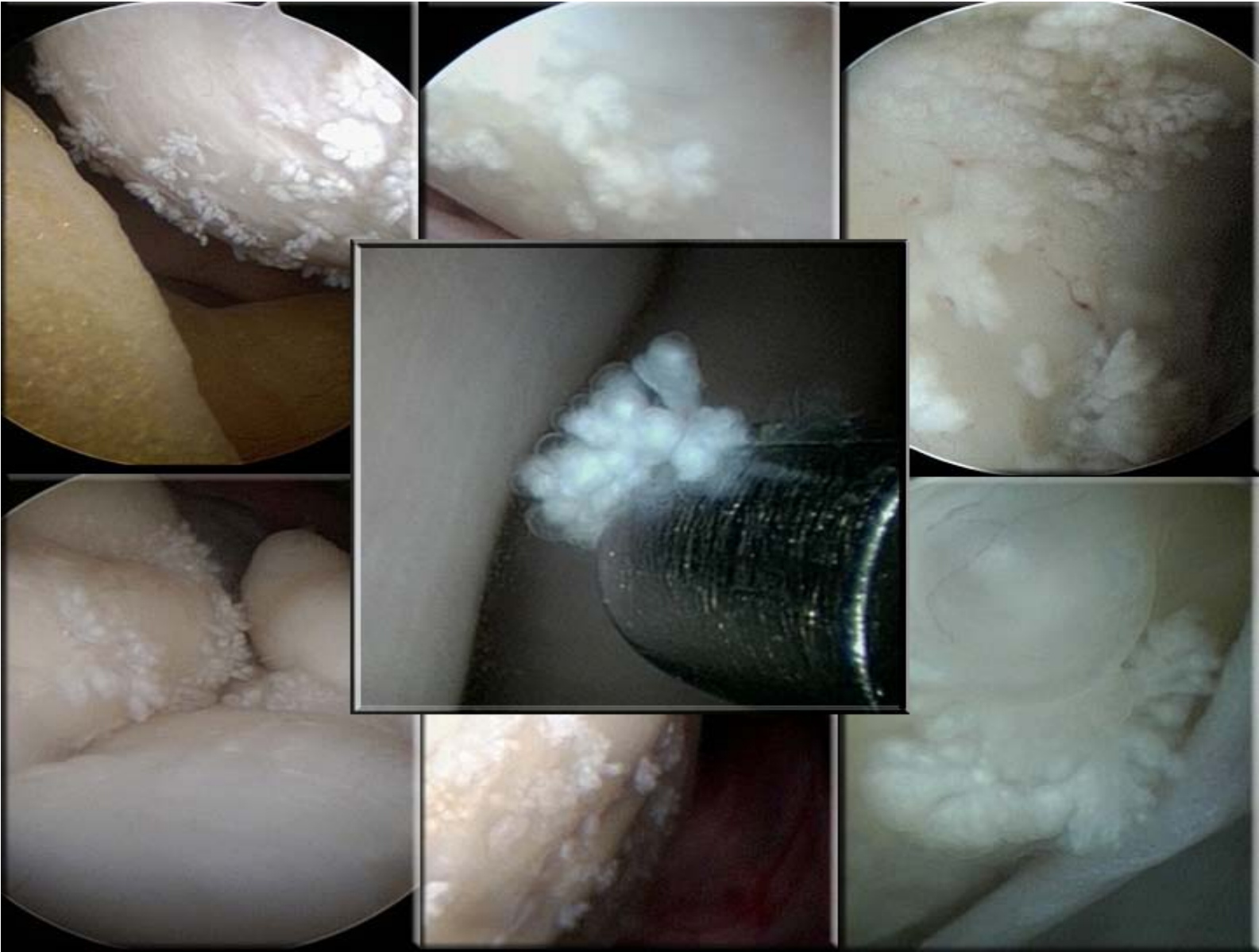Minimal invasive: low morbidity
easy access (obese patients)
no scars
high patient satisfaction

Technical advantages:



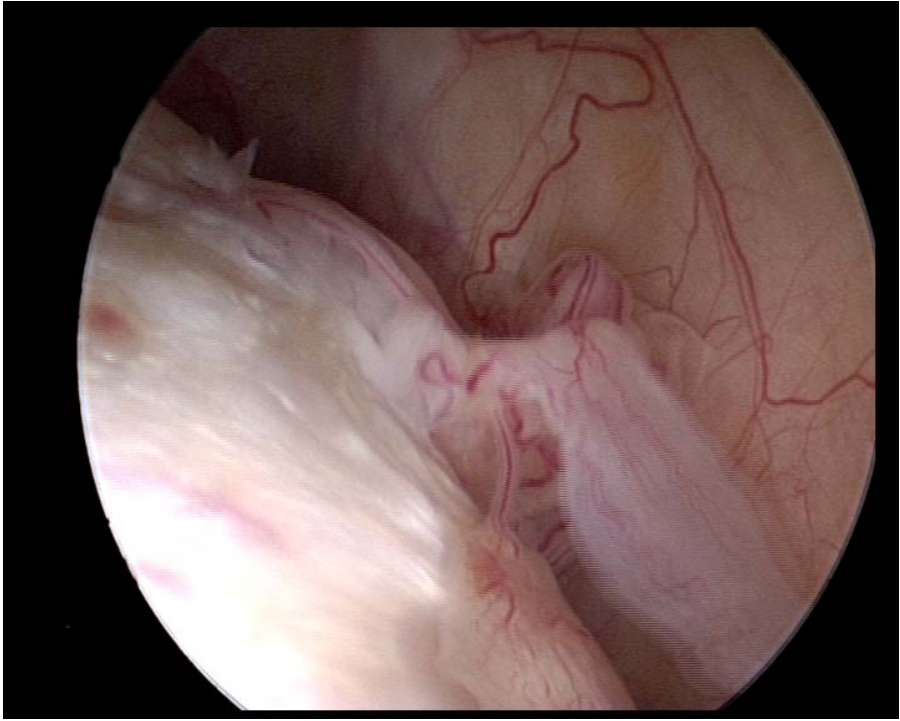
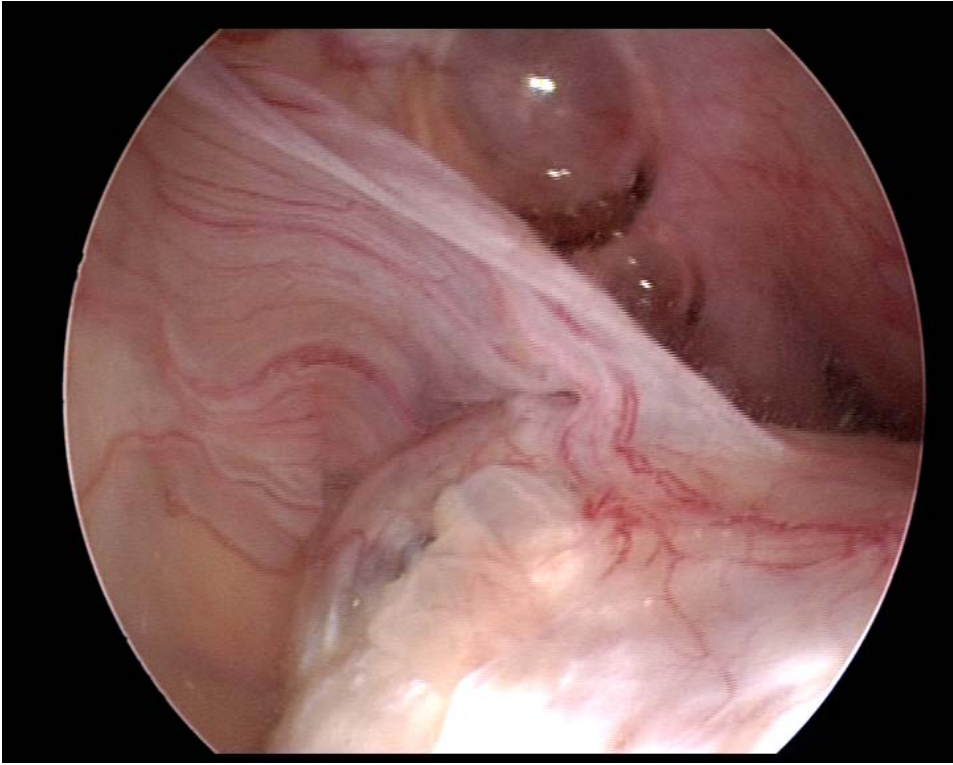
ovaries easy accessible
under water surgery (less adhesion formation)
clear visualisation
low risk profile





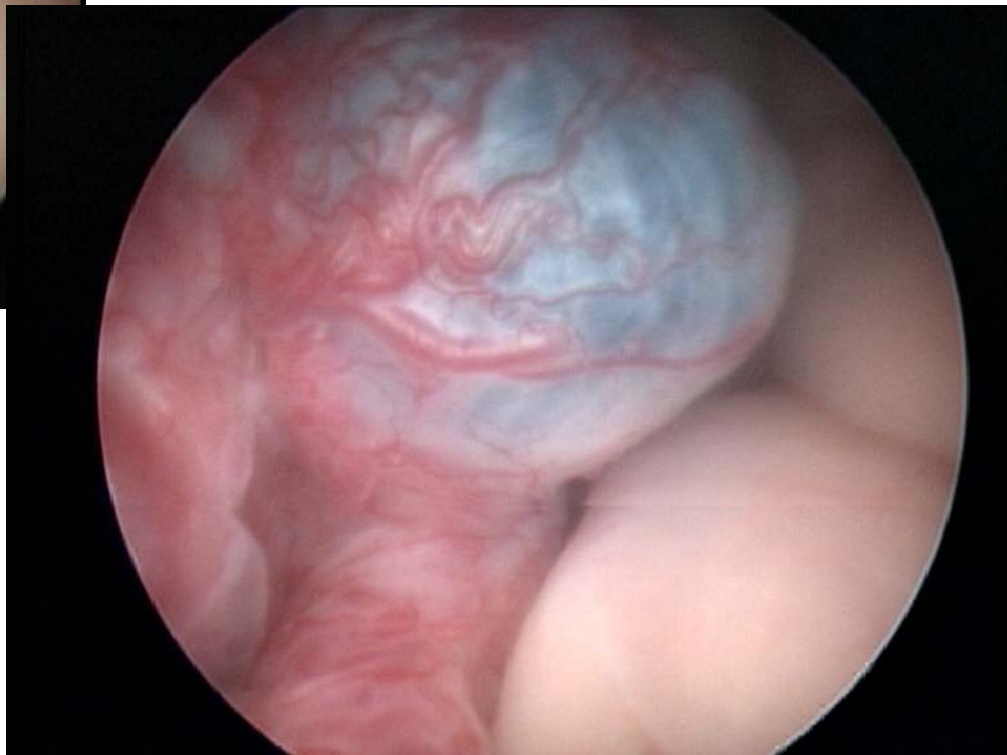
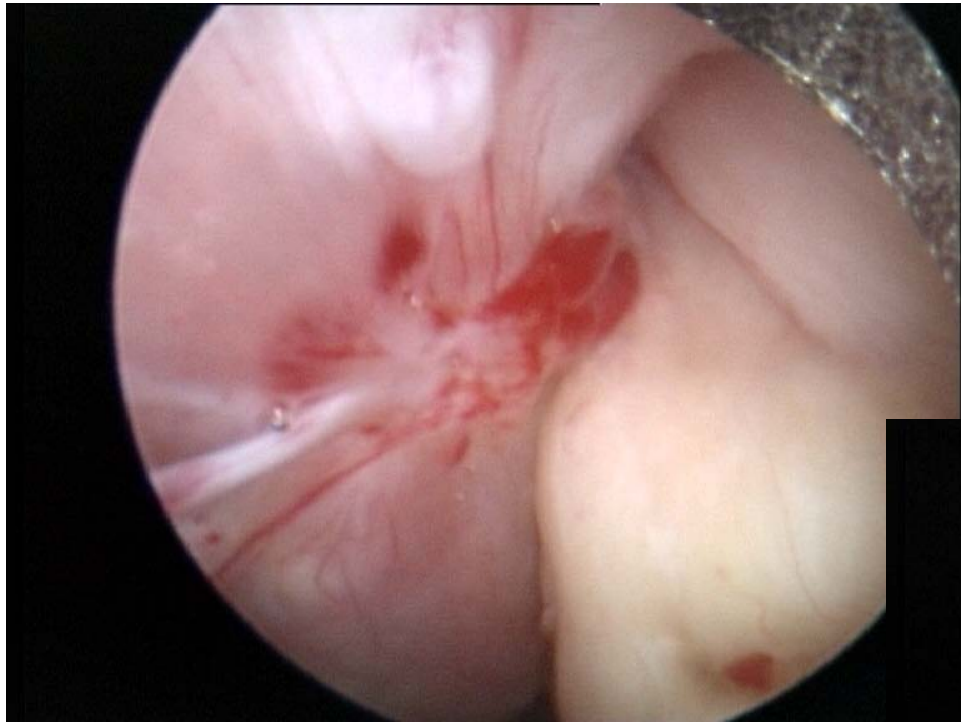
L.I.F.E.

Leuven Institute for Fertility & Embryology



L.I.F.E.

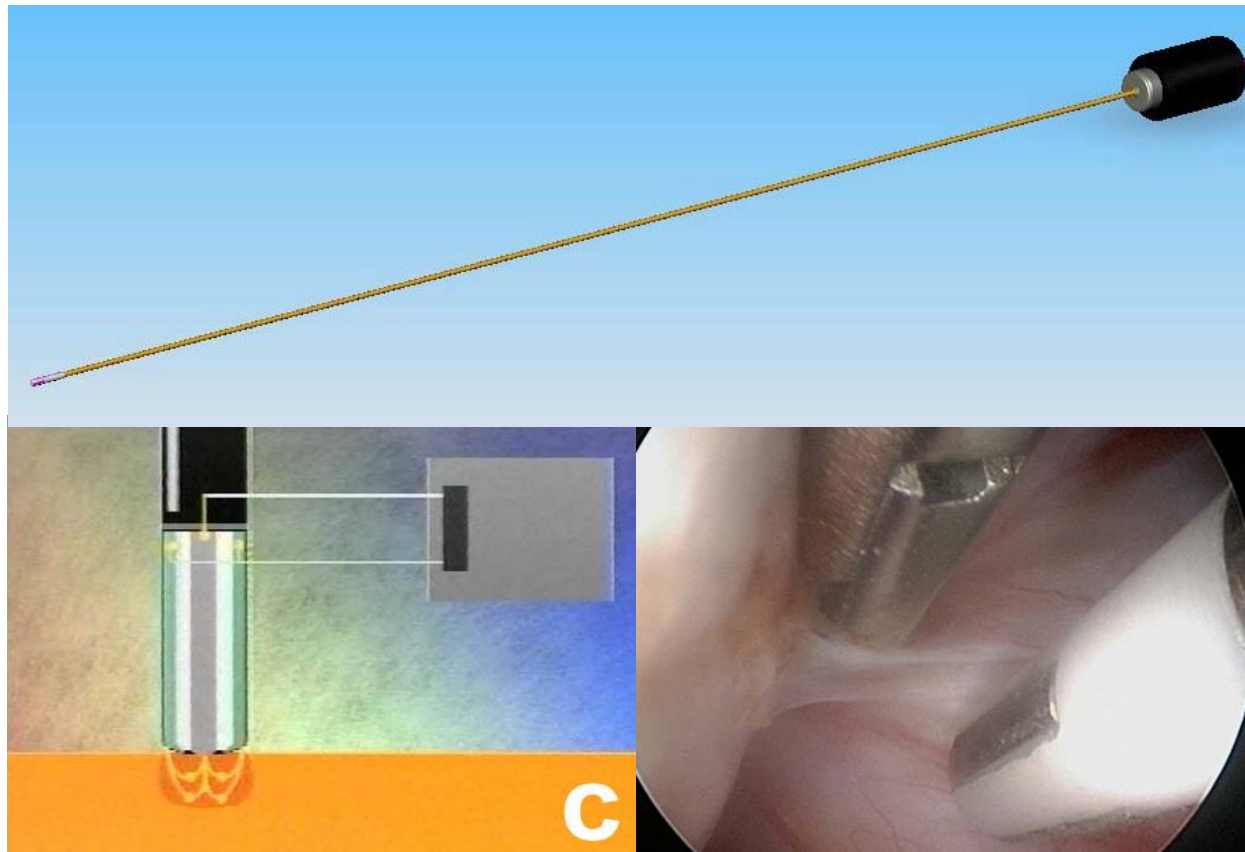
Leuven Institute for Fertility & Embryology

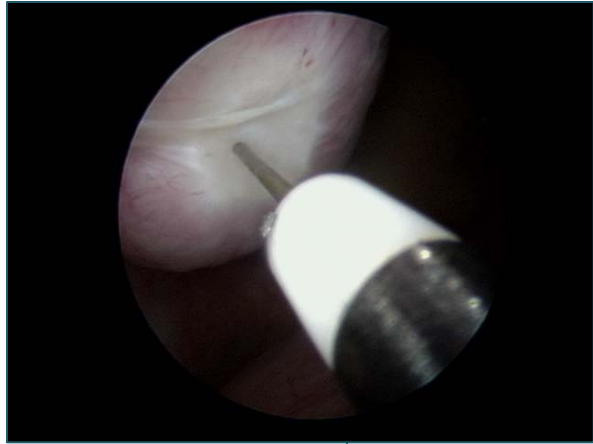


L.I.F.E.

Leuven Institute for Fertility & Embryology

Bipolar coagulation probe (Storz)






5 Fr BIPOLAR NEEDLE



5 French Bipolar probes



L.I.F.E.

Leuven Institute for Fertility & Embryology

Operative Transvaginal laparoscopy

Number	aug. 2006 – aug 2012:	1063	
	normal	500	47%
	endometriosis:	186	17.5%

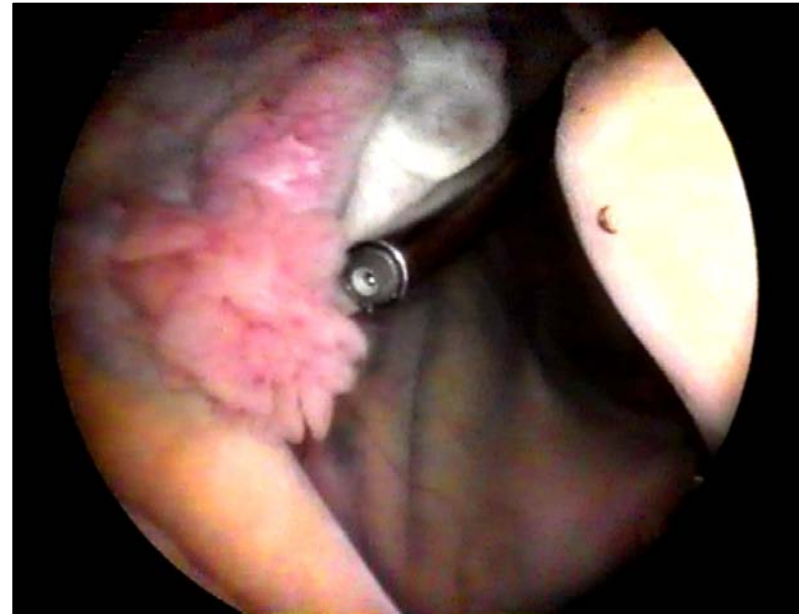

Peritoneal and ovarian endometriosis

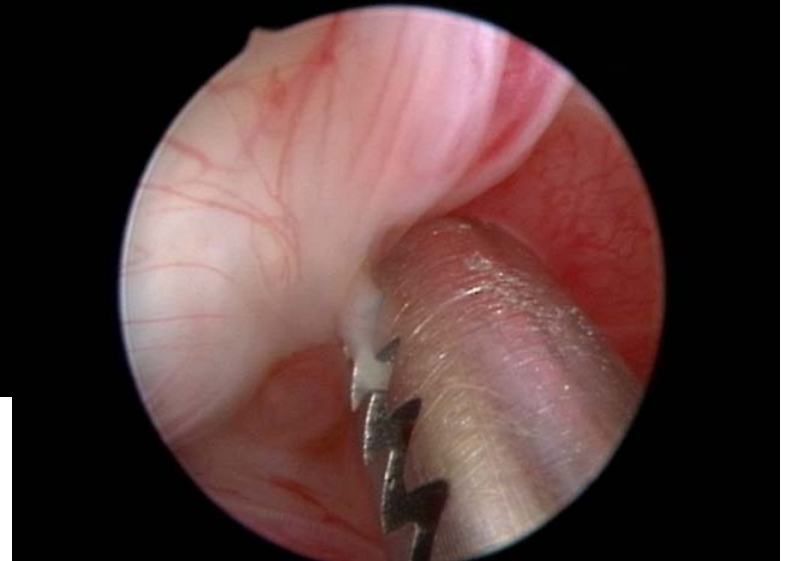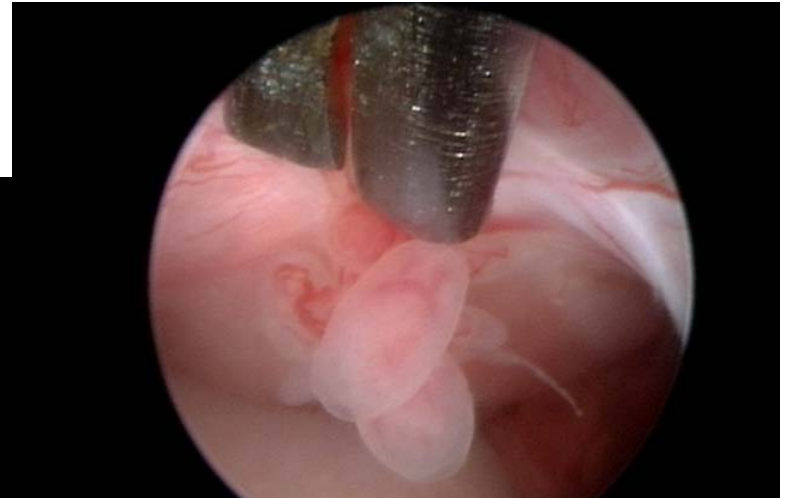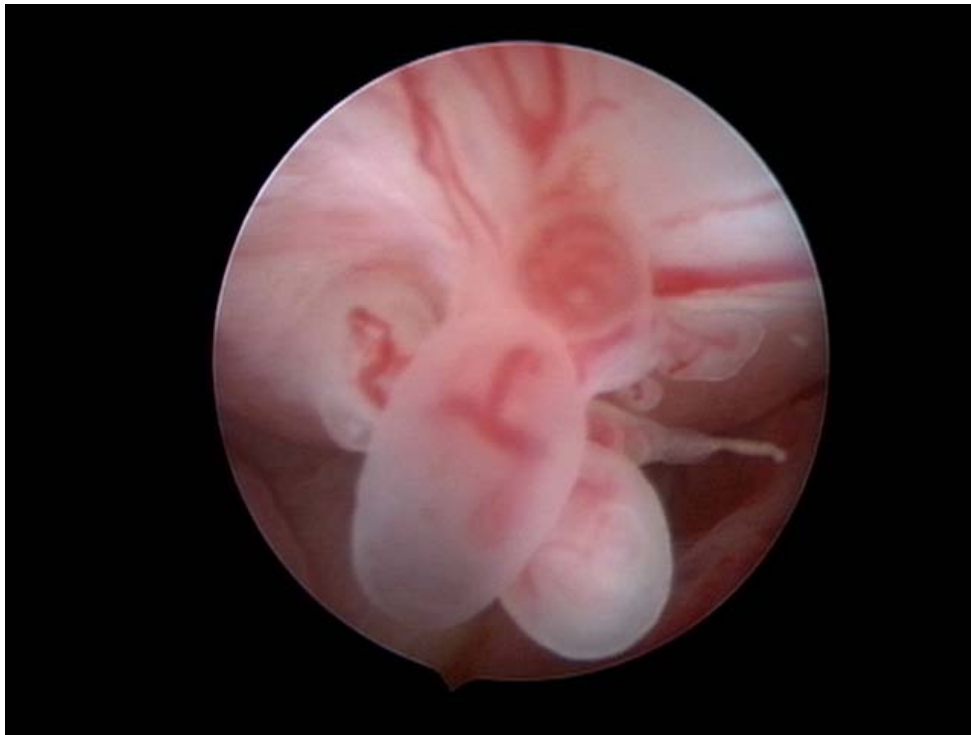Advantages of THL

Watery distension medium: accurate visualization

Easy access to the fossa ovarica



TRANSVAGINAL LAPAROSCOPY

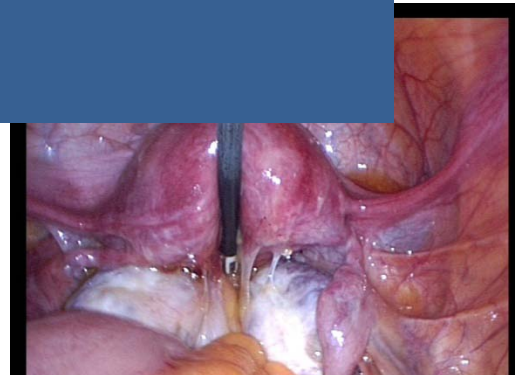

Surgery of ovarian endometrioma

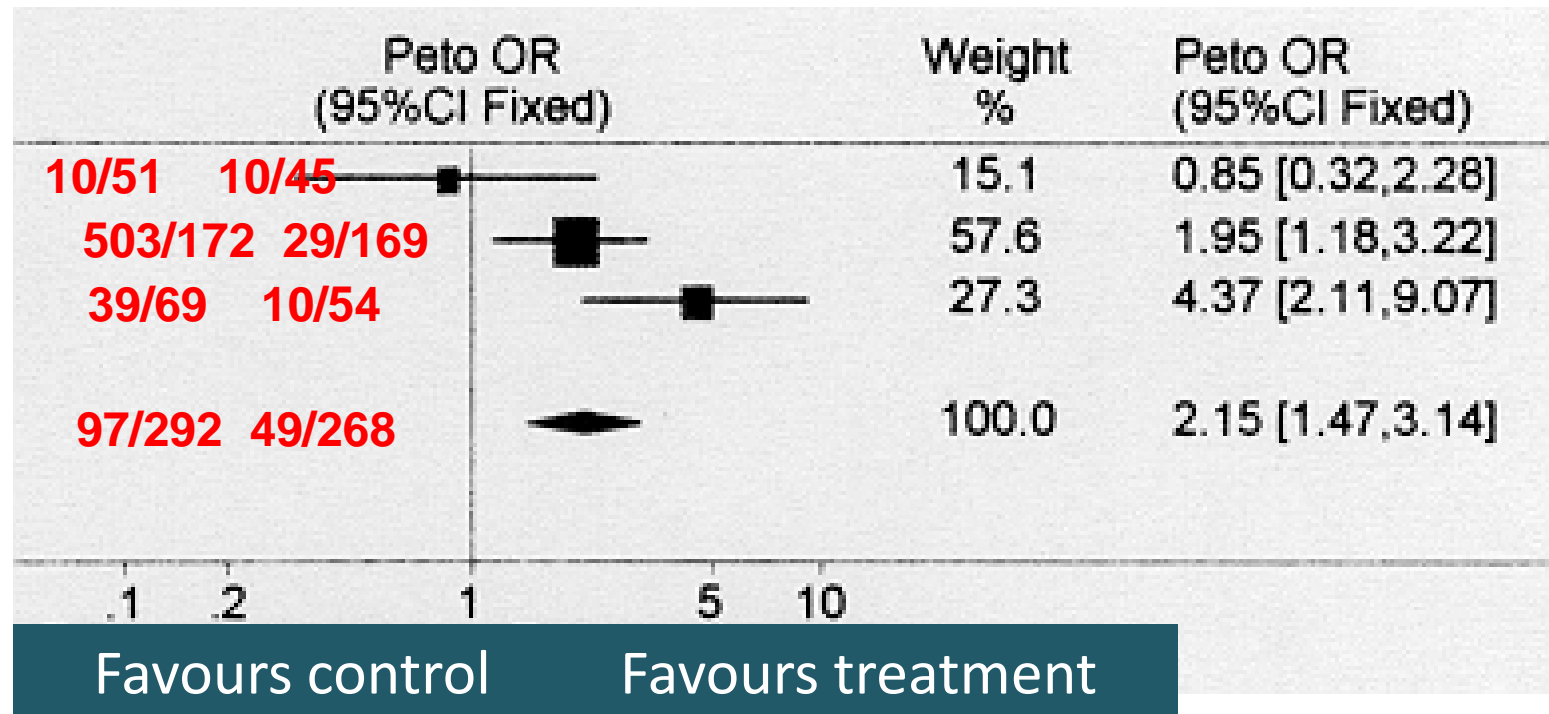
WHY SURGERY ?

POSITIVE APECTS:

- 1. creates possibility of spontaneous pregnancy !!*
- 2. relief of pain*
- 3. increased risk ovarian cancer*



Laparoscopic surgery for subfertility associated with endometriosis - live birth



Cochrane Review - Jacobson, Barlow & Koninckx



Quid fertility preservation?

Growing concern:

the serious risk of diminished ovarian reserve up to POF:

*cystectomy: aggressive stripping
extensive and aggressive hemostasis*



L.I.F.E.

Leuven Institute for Fertility & Embryology

Decline of AMH after cystectomy for ovarian endometrioma

Characteristics	Overall (n=38)	Unilateral (n=20)	Bilateral (n=18)	P-value
Age	33.8 ±4.7	34.0 ±3.9	33.6 ±5.4	0.830
BMI (kg/m ²)	20.1±2.3	20.4±2.7	19.7±1.7	0.781
<i>Serum AMH</i>				
Pre-operative	3.9±2.5	4.1±2.3	3.6±2.7	0.299
Post-operative	2.1±1.6	2.9±1.6	1.2±1.0	0.001

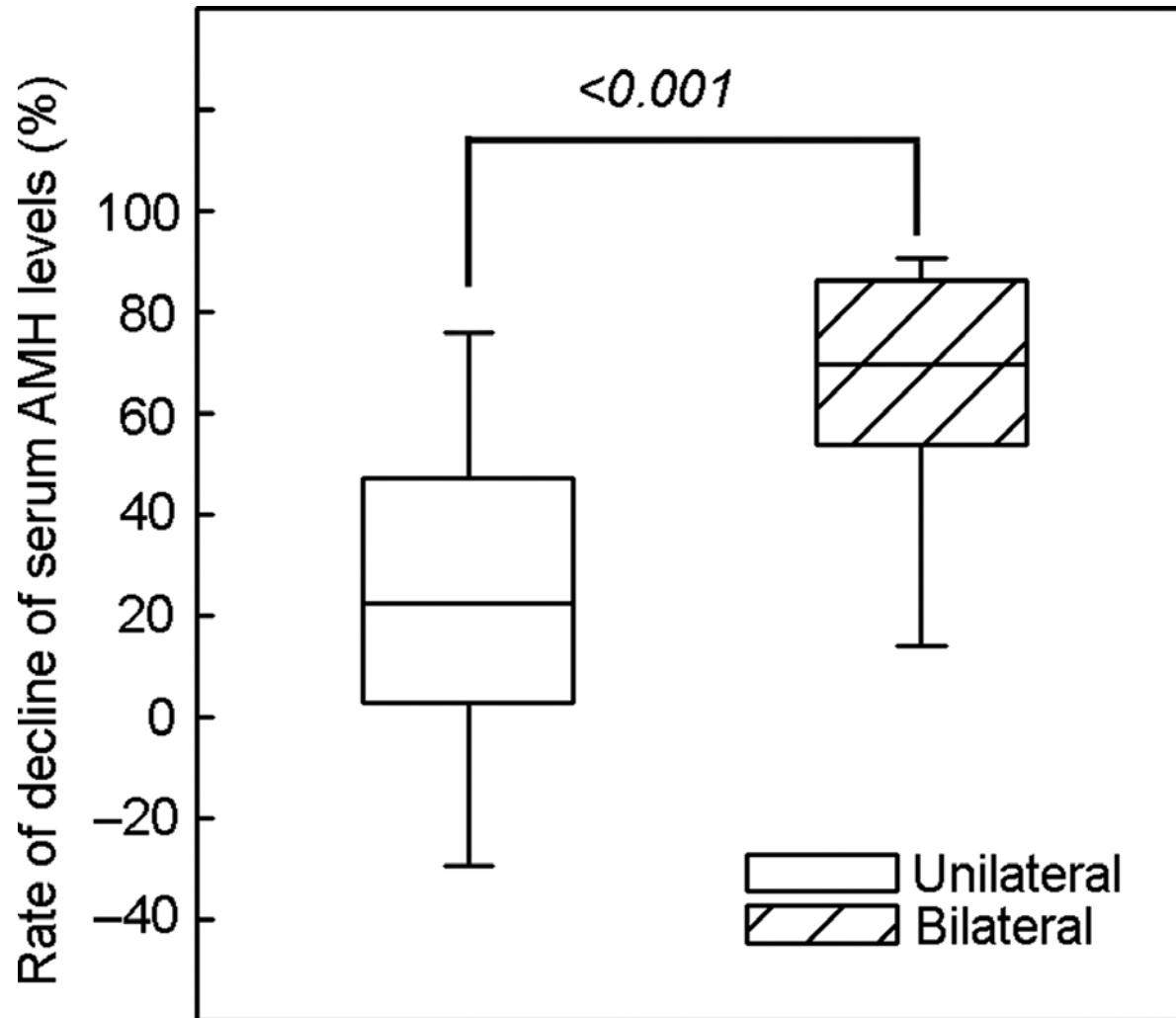
Hirokawa et al. Hum Reprod 2011; 26, 4



L.I.F.E.

Leuven Institute for Fertility & Embryology

The rate of decline in serum AMH is defined as $100 \times [\text{preoperative AMH level} - \text{post-operative AMH level}] / \text{preoperative AMH level}$.



Hirokawa W et al. Hum. Reprod. 2011;26:904-910

OVARIAN RESERVE

	AFC		AMH	
	BEFORE	AFTER	BEFORE	AFTER
GROUP 1 STRIPPING	2,0 (± 0.8)	2.4 (± 0.8)	3.9 (± 0.4)	2.9 (± 0.2)
GROUP 2 3-STEP	1.3 (± 0.5)	4.3 (± 0.8)	4.5 (± 0.4)	3.9 (± 0.6)

Pados et al. Hum Reprod 2010



L.I.F.E.

Leuven Institute for Fertility & Embryology

OVARIAN RESERVE

	Ablation plasmajet <i>N = 15</i>		Cystectomy <i>N = 15</i>	
	Non operated	operated	Non operated	operated
volume	7 (± 2.7)	5.2 (± 2.5)	8.8 (± 4.2)	3 (± 1.6)
AFC	6.8 (± 3.5)	5.5 (± 3.9)	8 (± 5.3)	2.9 (± 2.4)

Roman H Fertil Steril, 2011



L.I.F.E.

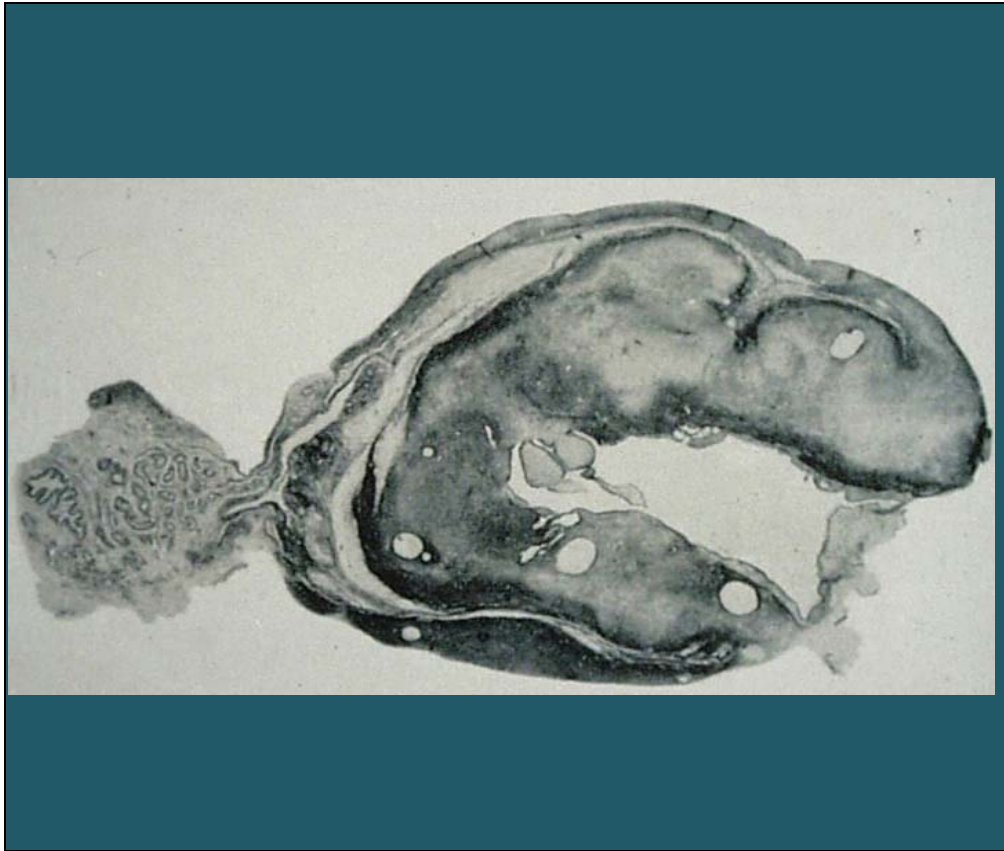
Leuven Institute for Fertility & Embryology

Pathogenesis of ovarian endometrioma

- Superficial endometriotic implants, bleeding and invagination of ovarian cortex.
- Metaplasia of coelomic epithelium
- Involvement of functional ovarian cysts



Pathogenesis of ovarian endometrioma



Implantation of regurgitated endometrial cells on ovarian surface.

Adhesion formation

Bleeding at implantation site and invagination cortex

Hughesdon, 1957 J Obst. Gynec. 44:481



L.I.F.E.

Leuven Institute for Fertility & Embryology

Pathogenesis

- Factors contributing to the growth of the endometrioma:
 - shedding/bleeding of peritoneal implants
 - important fibrosis at the hilus of the ovary with repeated bleeding of venules
 - ovulation towards and hemorrhagic cystic corpus luteum formation inside the endometrioma



Types of endometriomas

Ovarian endometrioma :

type 1: free or loosely fixed, usually small

**type 2: densely adherent to pelvic structures in
fossa ovarica**

type 3: with adenomyosis in adherent tissue

Unilateral/ bilateral



Ovarian endometrioma

Accuracy of US

	Nr	Size (mm)	Sens.	Spec.
Kurjak	113	18-160	84	97
Guerriero	29	40 (SD:10)	84	95
Alcazar	27	?	89	91
Guerriero	58	40 (SD:16)	81	96



564 consecutive infertile women, 169 of whom show endometriosis at TVE

Detection of small endometriomas at TVS & TVE in 169 patients with endometriosis (15-16% of all TVE)

size	TVS +	TVE +	TVS sensitivity
≤ 15 mm	5	11	45 %
> 15 mm	11	11	100 %
total	16	22	16/22 (73%)



Ovarian endometrioma

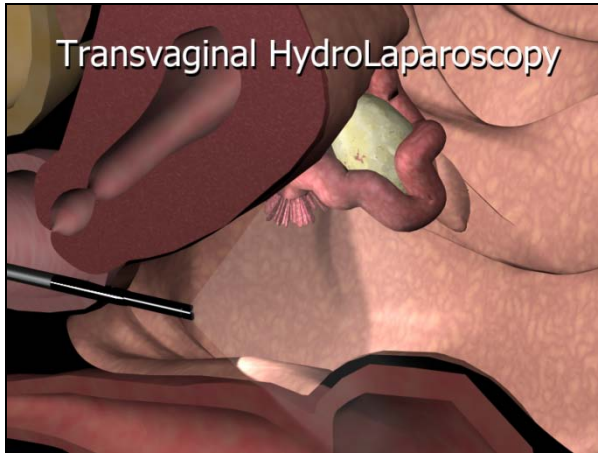
Transvaginal sonography

TVS is useful, if diameter of cyst is 15 mm or more

TVS is the preferred method of diagnosing an asymptomatic endometrioma, but cannot exclude the presence of endometriosis.



The Transvaginal endoscopy



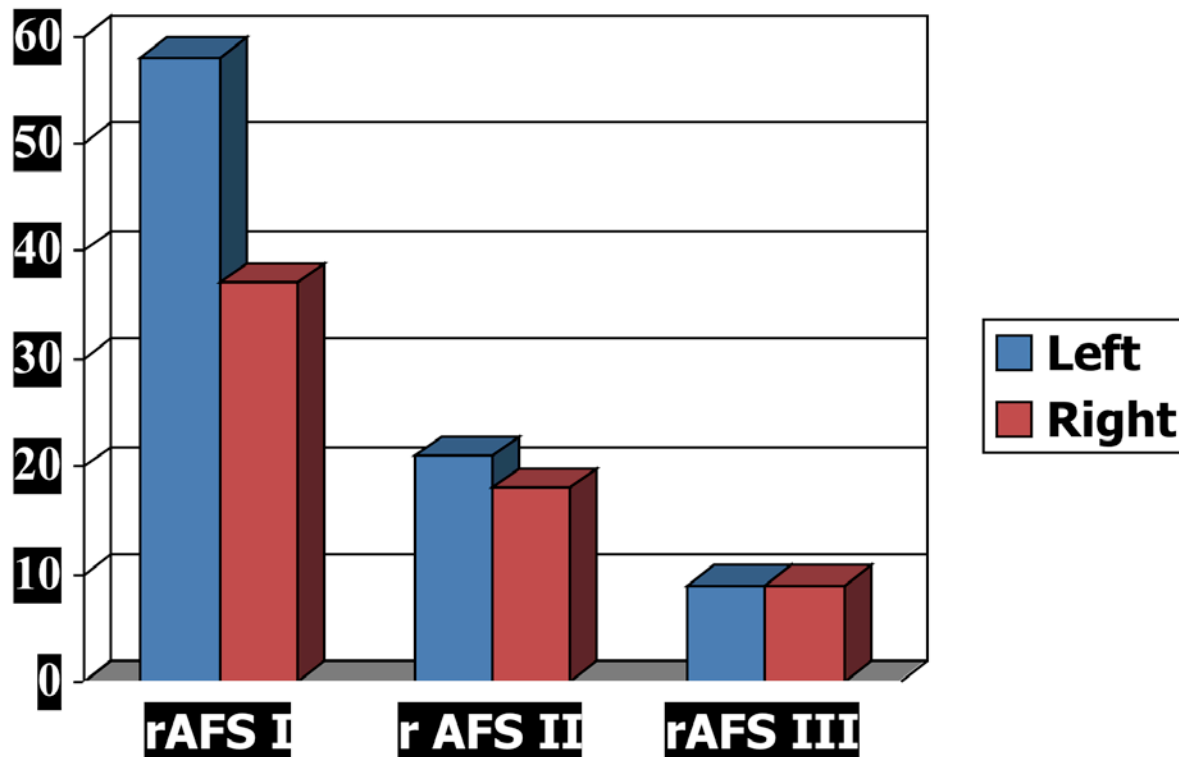
- Hydrolaparoscopy offers the ideal inclination angle to explore the ovarian fossa
- TVE allows for the detection of endometriomas that may be invisible at TVS (<15 mm)



OPERATIVE TRANSVAGINAL LAPAROSCOPY

RESULTS

Operative endometriosis and distribution



TRANSVAGINAL LAPAROSCOPY

Side dependent distribution of endometriosis during THL

Endometriosis n= 77

Left side	n= 43 (55,8%)
Both side	n= 29 (37.7%)
Right side	n= 5 (6.5%)
	p>0.0001

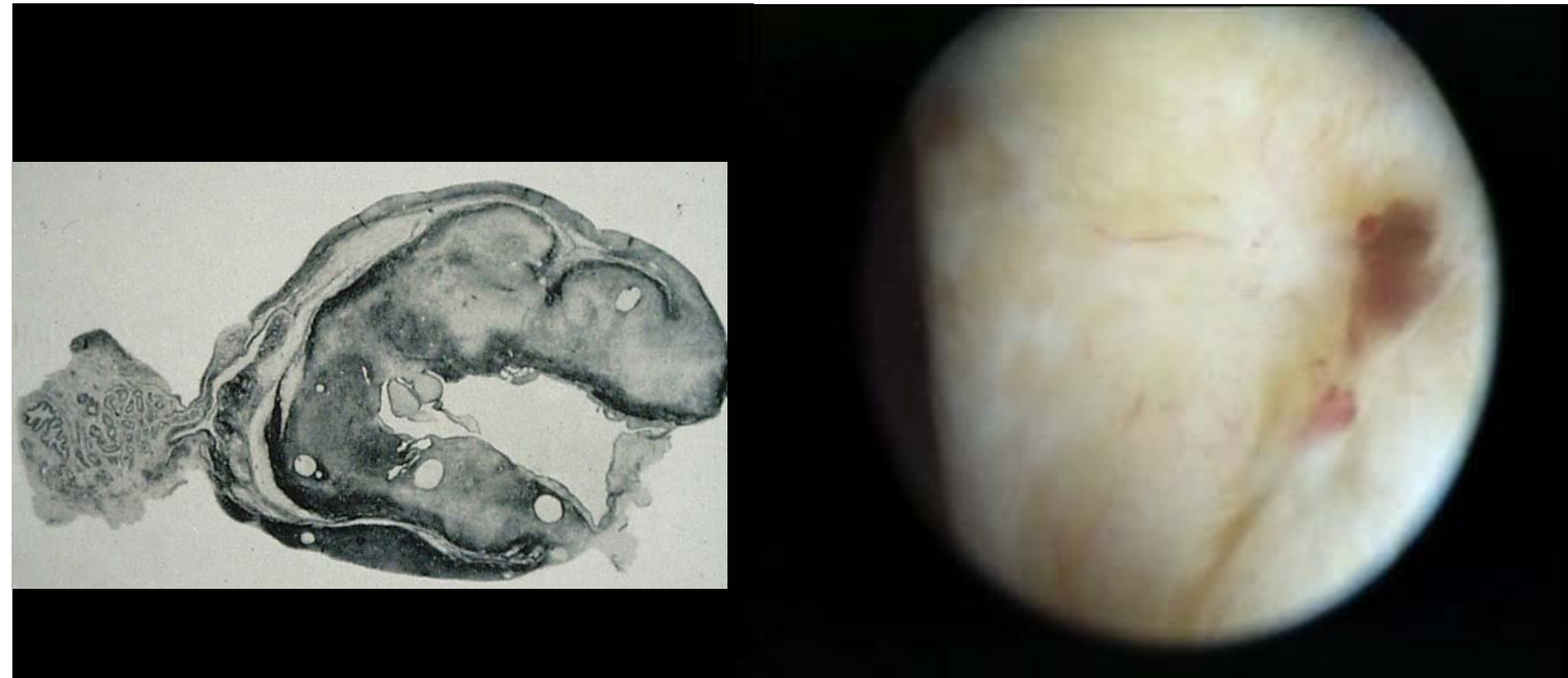Kissler S. et al. EJOG, 2011; 158: 285-88



L.I.F.E.

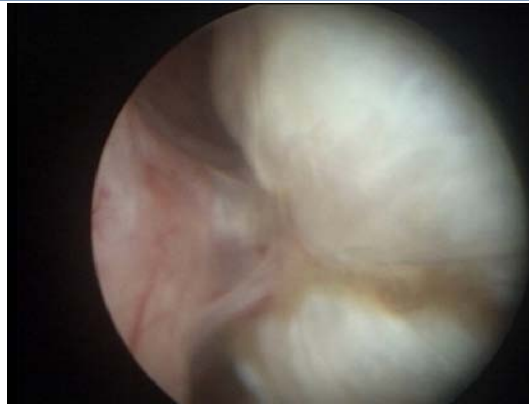Leuven Institute for Fertility & Embryology

Pathogenesis of ovarian endometrioma

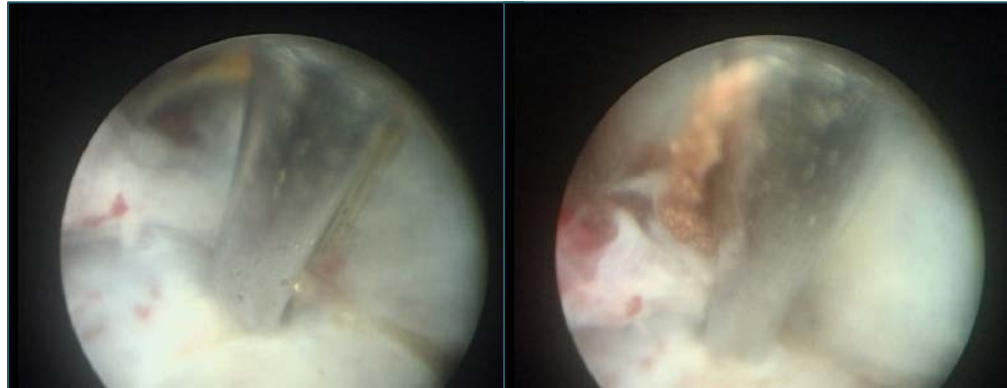


Hughesdon,1957 J Obst.Gynec. 44:481

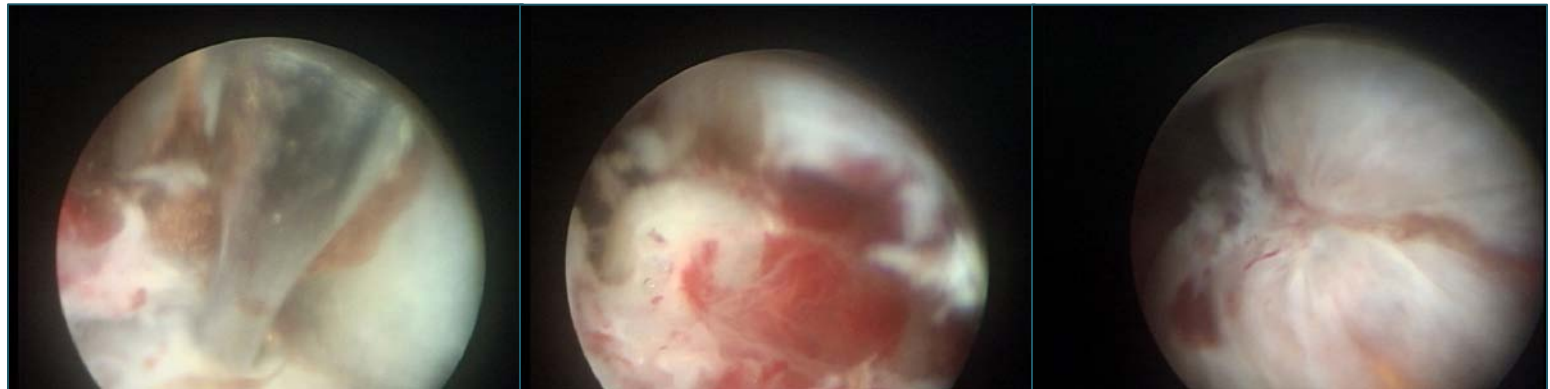



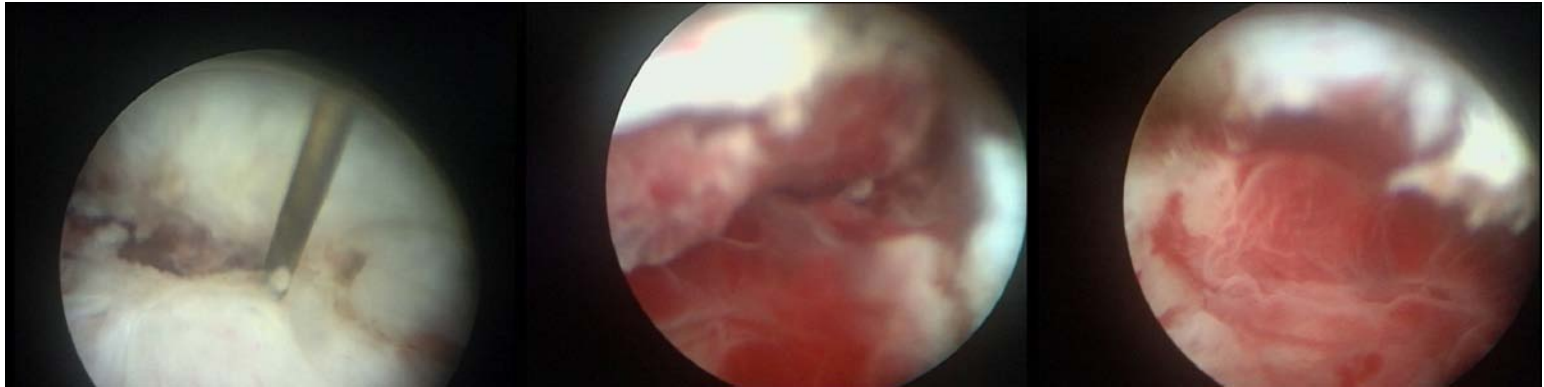Site of invagination
with
adhesions



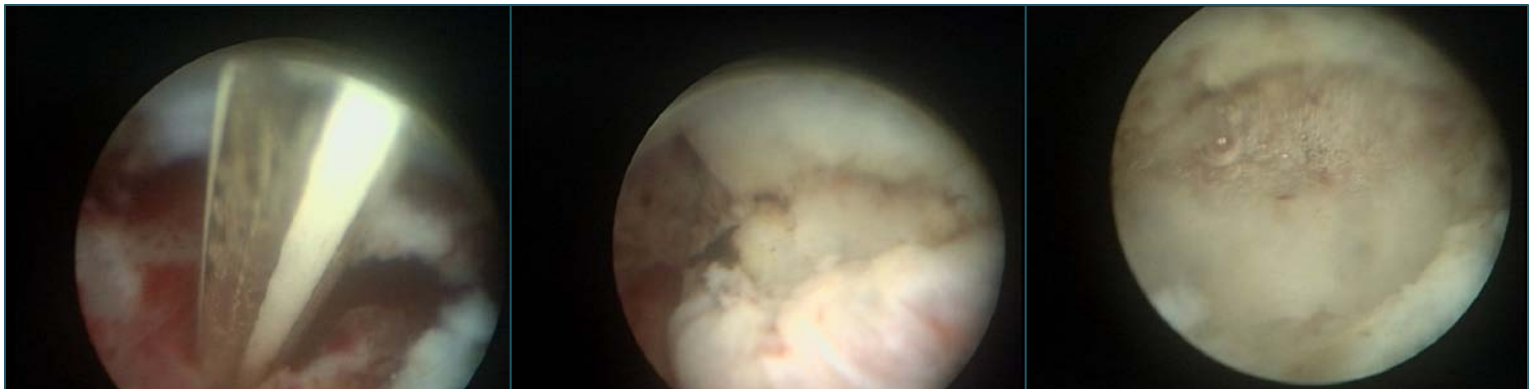1st step
Adhesiolysis

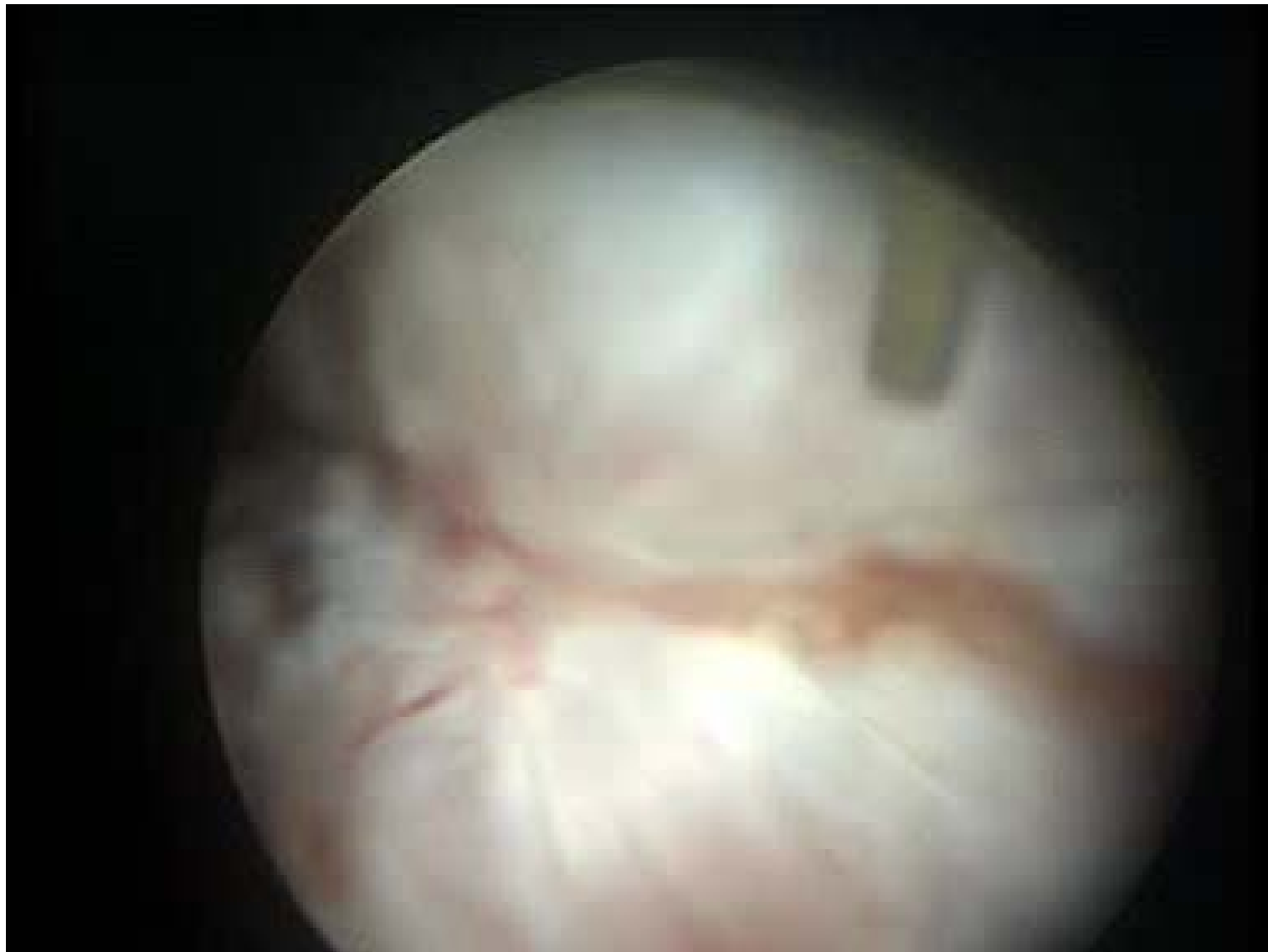

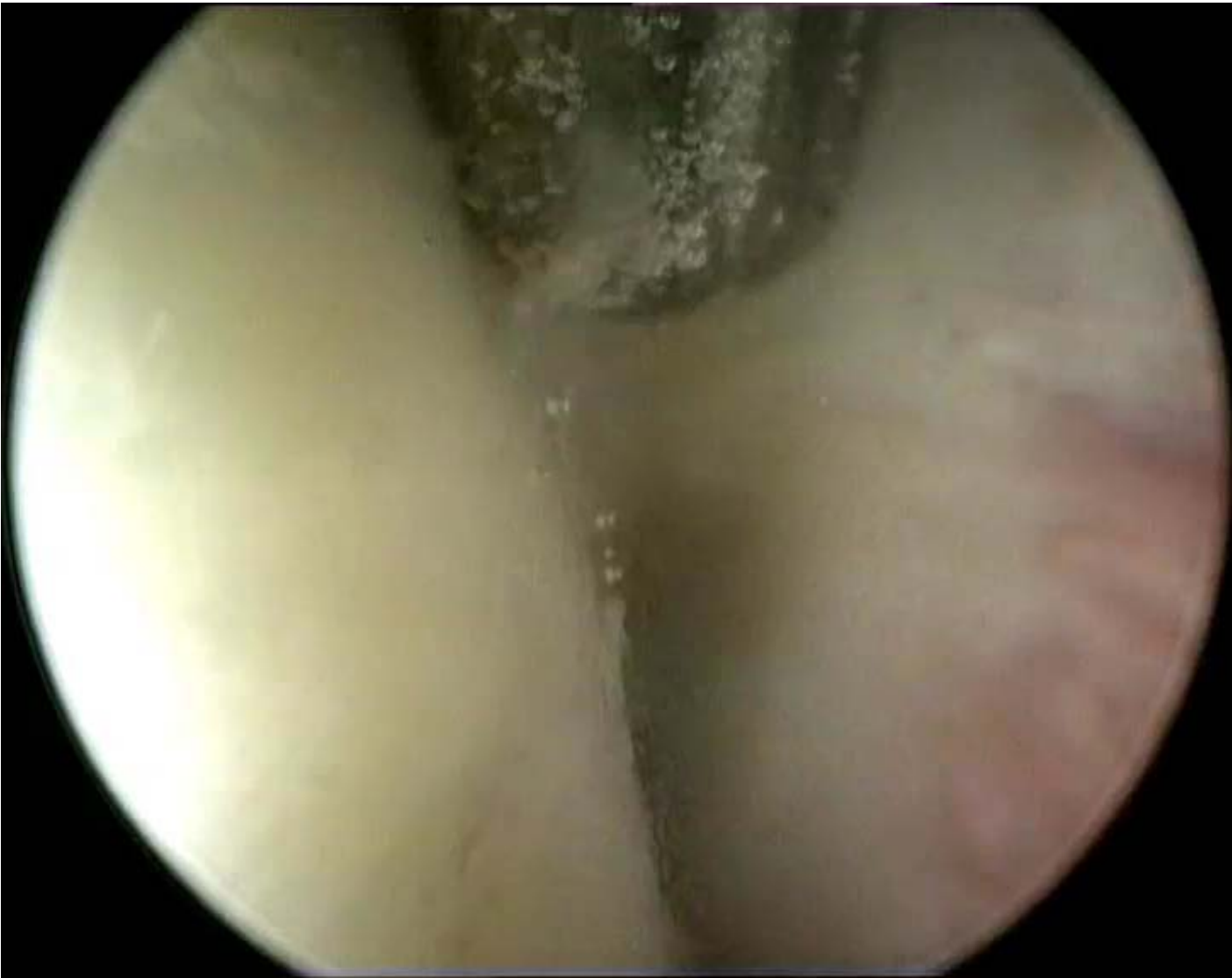2nd step: opening at site of invagination

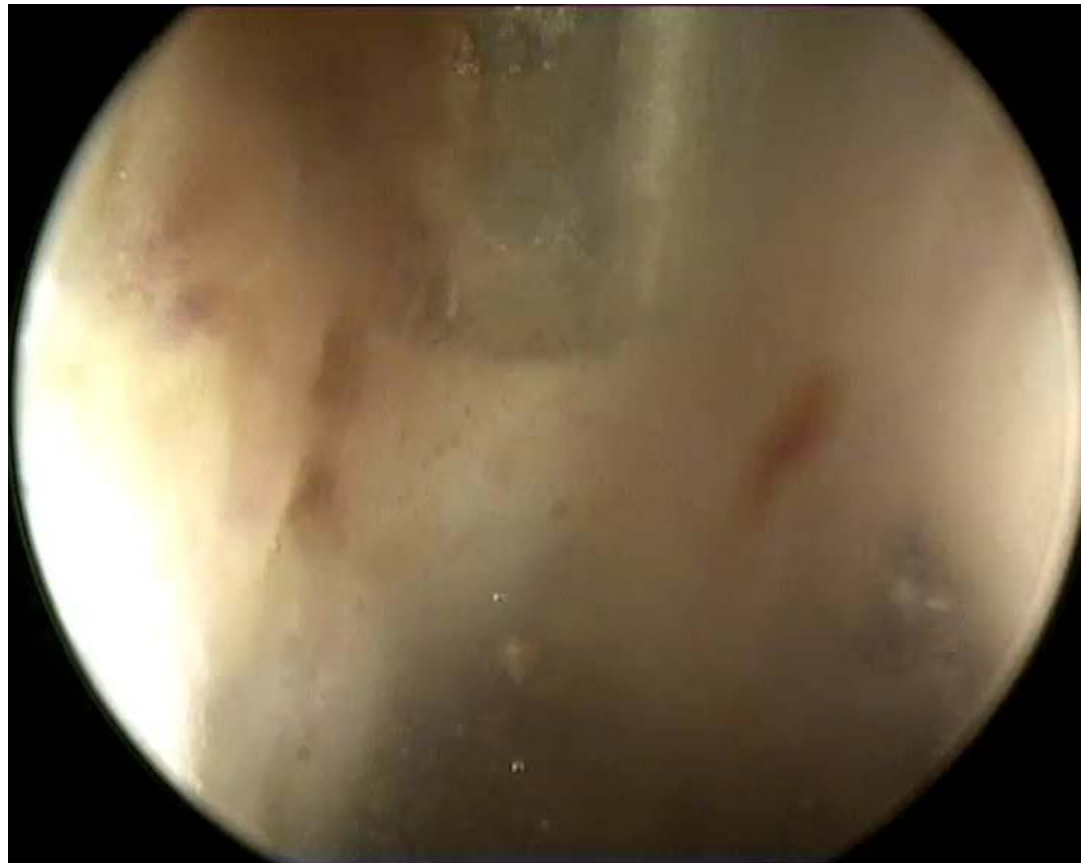


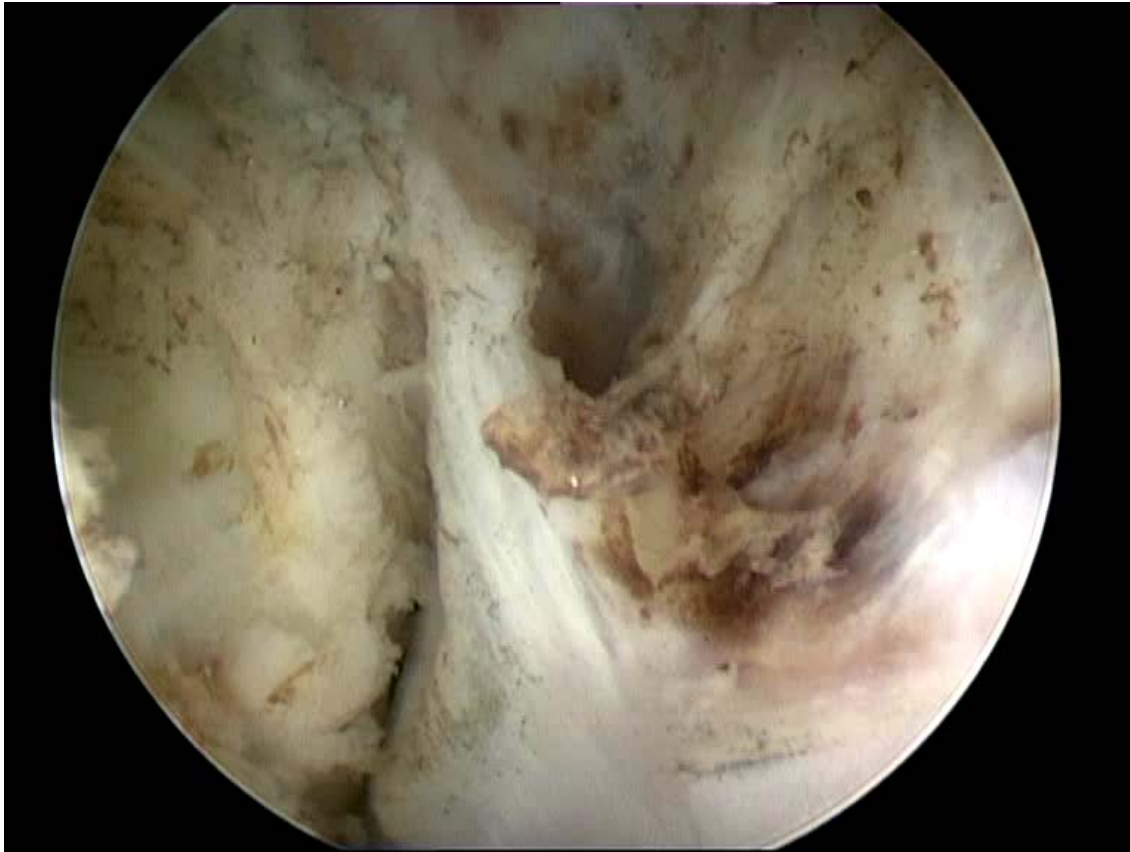3th step: superficial coagulation

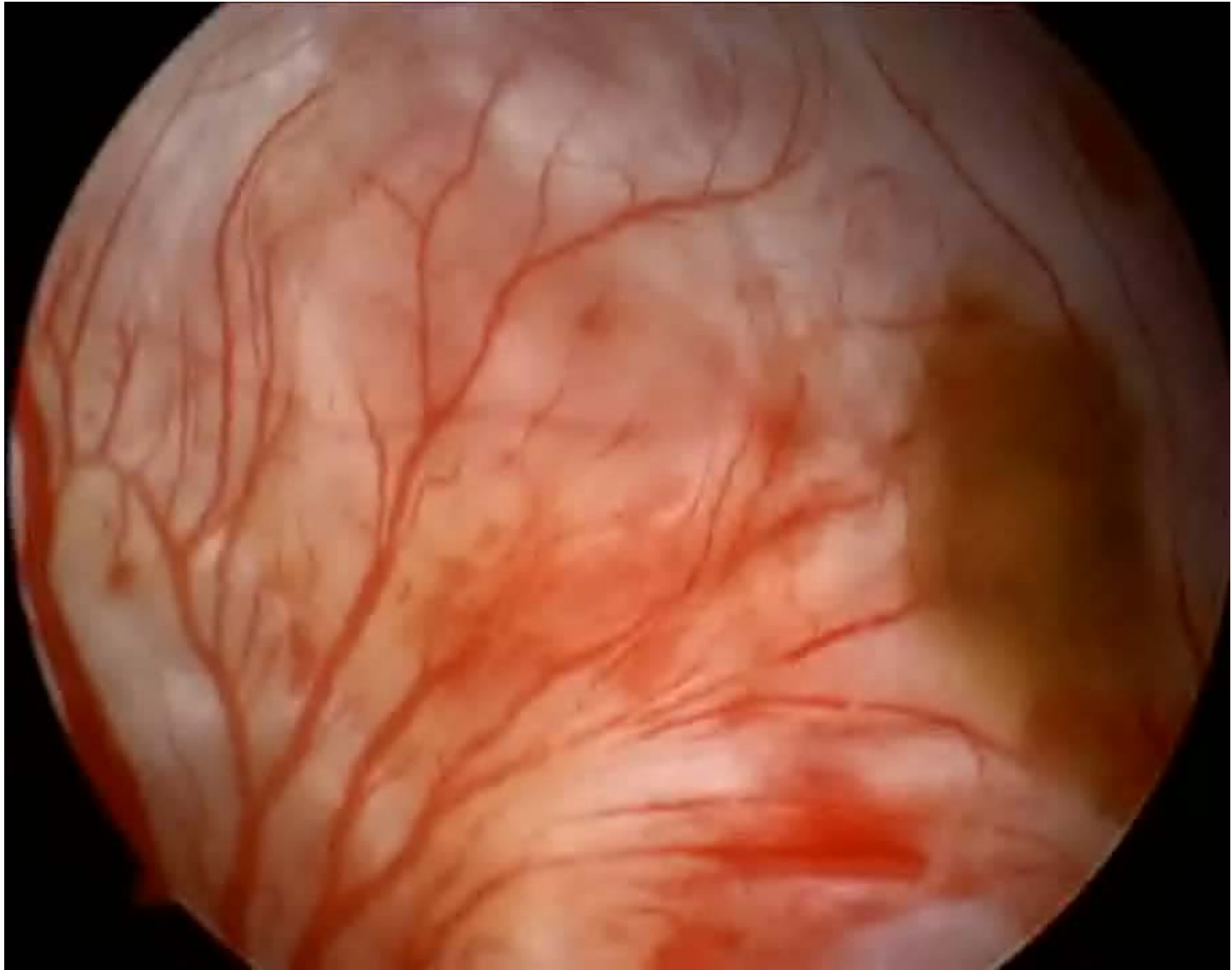












L.I.F.E.

Leuven Institute for Fertility & Embryology

TVE and small endometrioma

- We need to focus on the *early detection* of the small endometrioma in the young female patient (TVS, MRI, CA-125, TVE)
 - We can't make a *distinction* between the small endometrioma with a good prognosis and the one that will continue to grow towards the more destructive stages of the disease.
- Treat when surgery is feasible & efficient, with distinct cleavage planes, minimal fibrosis.
 - ~ maximal preservation of healthy ovarian tissue, i.e. functional prognosis (↓ postop adhesion formation) and reproductive potential of the affected ovary



THL and small endometrioma

Number 747 THL procedures (2006-2011)

All infertile women without obvious preoperative pathology

Aged between 19 and 45

143 endometriosis (19%) I – II:

95 Peritoneal 66.5%

48 endometrioma max 2cm 33.5%



THL and small endometrioma

48 small endometrioma: 2 referred laparoscopy

46 operative procedures: 2 recurrences (4%);
8 pat. lost follow-up

10 spontaneous pregnancies

6 IUI : 1 pregnant

13 IVF-ICSI: 8 pregnant



24 %



L.I.F.E.

Leuven Institute for Fertility & Embryology

Conclusions

- TVE is a feasible, accurate and well tolerated procedure with low complication rates.
- With the direct access to tubes and ovaries, the transvaginal access offers a lot of advantages, not only for diagnosis but also for operative procedures.



Conclusions

In couples with diagnosis of “unexplained” infertility without preceding laparoscopy, endometriosis must always be excluded.



Conclusions

FERTILITY PRESERVATION AND ENDOMETRIOSIS

Ovarian surgery:

minimal tissue damage (*decline ovarian reserve*)

ablative surgery: lower impact ovarian reserve

early intervention



L.I.F.E.

Leuven Institute for Fertility & Embryology





Leuven Institute for Fertility and Embryology



Stephan Gordts
Patrick Puttemans
Sylvie Gordts
Marion Valkenburg
B. Verheyden
Rudi Campo

B-3000 Leuven, Belgium
www.lifeleuven.be

 +32 (16) 270190

 +32 (16) 270197

lifeleuven@lifeleuven.be