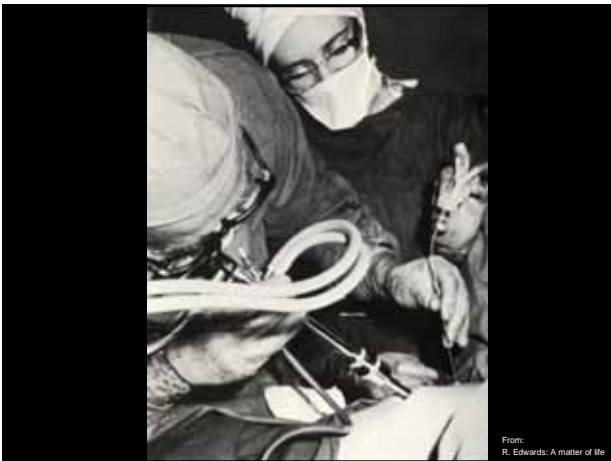

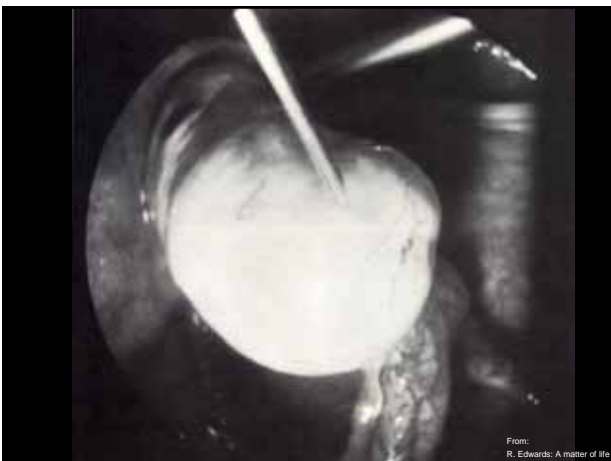
Risks of oocyte pick-up

Priv.- Doz. Dr. med. Annika K. Ludwig
ENDOKRINOLOGIKUM Hamburg
Zentrum für Hormon- und Stoffwechselerkrankungen,
Reproduktionsmedizin und Pränatale Medizin



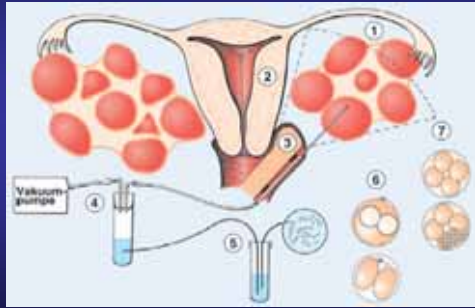


From:
R. Edwards: A matter of life

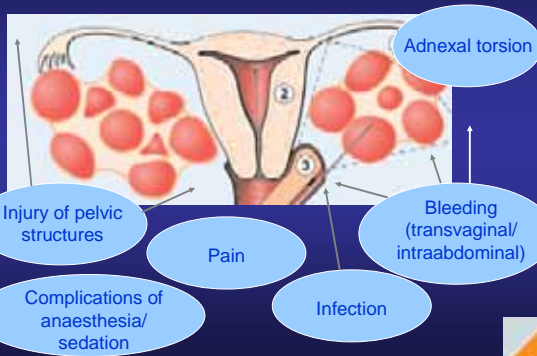


From:
R. Edwards: A matter of life

Transvaginal, ultrasound-guided oocyte pick-up



Potential peri-/postoperative risks



Peri- and postoperative complications documented in the European register in 2001

	Oocyte retrievals (n)	Bleeding (n)	Infection (n)
Belgium	6 023	6	10
Finland	1 783	0	0
France	17 995	7	0
Germany	24 955	323	0
Greece	1936	1	2
Italy	8341	21	6
Norway	1472	0	1
Spain	5 868	9	1
Switzerland	2 071	3	0
UK	11 319	1	0
Denmark	3 016	Not available	Not available
Sweden	3 861	Not available	Not available
The Netherlands	4 142	Not available	Not available

Nyboe Andersen et al. 2005

Peri- and postoperative complications documented in the European register in 2001

	Oocyte retrievals (n)	Bleeding (n)	Infection (n)
Belgium	6 023	6	10
Finland	1 783	0	0
France	17 995	7	0
Germany	24 955	323	0
Greece	1936	1	2
Italy	8341	21	6
Norway	1472	0	1
Spain	5 868	9	1
Switzerland	2 071	3	0
UK	11 319	1	0
Denmark	3 016	Not available	Not available
Sweden	3 861	Not available	Not available
The Netherlands	4 142	Not available	Not available

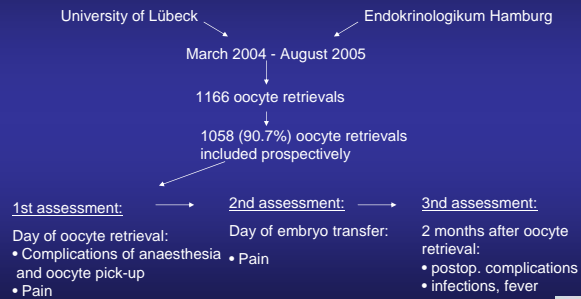
Nyboe Andersen et al. 2005

Peri- and postoperative complications documented in the European register in 2001

	Oocyte retrievals (n)	Bleeding (n)	Infection (n)
Belgium	6 023	6	10
Finland	1 783	0	0
France	17 995	7	0
Germany	24 955	323	0
Greece	1936	1	2
Italy	8341	21	6
Norway	1472	0	1
Spain	5 868	9	1
Switzerland	2 071	3	0
UK	11 319	1	0
Denmark	3 016	Not available	Not available
Sweden	3 861	Not available	Not available
The Netherlands	4 142	Not available	Not available

Nyboe Andersen et al. 2005

Complications of transvaginal ultrasound-guided oocyte retrieval: prospective study of more than 1.000 oocytes retrievals.



Ludwig A.K. et al. Hum Reprod (2006)

Oocyte retrieval

- General anaesthesia or sedation with midazolam 2.5 mg and pethidin 50 mg
- the vagina was soaked with an isotonic saline solution
- covered with a sterile surgical sheet and the gynaecologist wore sterile surgical gloves
- ultrasound transducer was covered with a sterile plastic sheet
- ultrasound-guidance with a 16G single lumen needle
- no prophylaxis with antibiotics

Ludwig A.K. et al. Hum Reprod (2006)



Patients

Oocyte retrievals (n)	1058
Age at retrieval (years)*	34.21 ± 4.52
BMI (kg/m ²) *	23.79 ± 7.39
Prior abdominal surgery	56.1%
Diagnostic laparoscopy	14.6%
Operative laparoscopy	26.1%
Laparotomy	15.4%
Surgeries (n)*	0.84 ± 0.98

*mean ± standard deviation

Ludwig A.K. et al. Hum Reprod (2006)



Cycle outcome

	n = 1058
Number of preceding cycles (n)	1.15 ± 0.43
IVF	23.1%
ICSI	76.9%
Cycle outcome	
Oocytes retrieved (n)*	8.75 ± 5.47
Embryos transferred (n)*	2.10 ± 0.63
Pregnancy rate	
Clinical pregnancy rate	21.4%
Abortion rate	14.0%
Extrauterine pregnancies	6.8%
Ongoing pregnancy rate	16.9%

*mean ± standard deviation

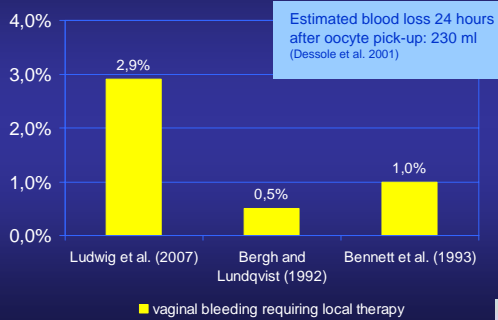
Ludwig A.K. et al. Hum Reprod (2006)



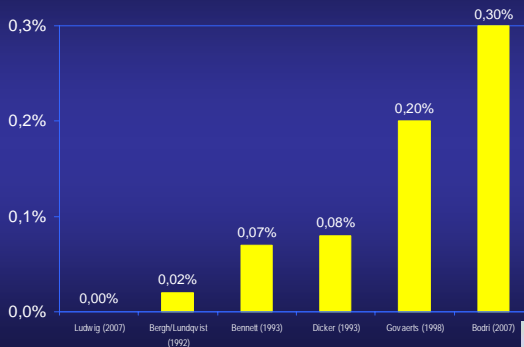
Anaesthesia

- 94.9% (1004/1058) of oocyte pick-ups performed under general anaesthesia
- No complications during/ after general anaesthesia
- Literature: no data on complications of anaesthesia
- Case-report on bradycardia after paracervical administration of mepivacain

Vaginal bleeding



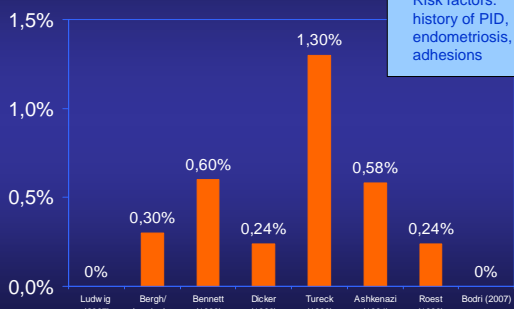
Intraabdominal bleeding



Injury of pelvic structures

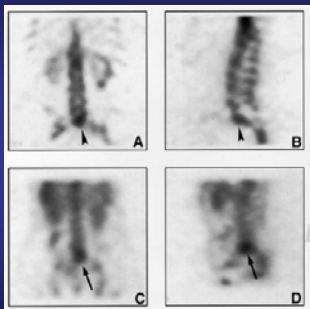
- In our study 1 case of injury of the ureter
- Literature: Case reports
- Case reports of injury of ureter
(Jones *et al.*, 1989; Coroleu *et al.*, 1997; Fugita & Kavoussi, 2001; Miller *et al.*, 2002)
- 2 cases of perforated appendicitis with puncture holes in the appendix
(Akman *et al.*, 1995; Roest *et al.*, 1996).

Pelvic infection



Risk factors:
history of PID,
endometriosis,
adhesions

Vertebral osteomyelitis after oocyte retrieval



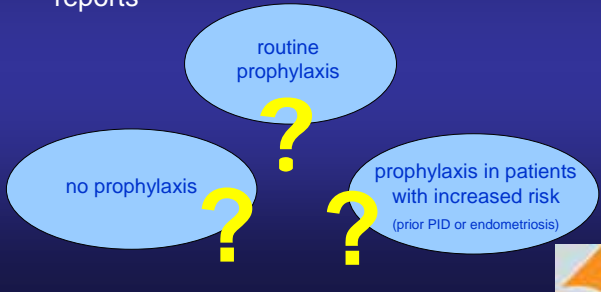
41 y old patient
Unexplained infertility
Lower back pain immediately after oocyte retrieval
1 week later: fever, lower back pain
↓
Intraoperative trauma to the bone and infection

Single-photon emission computed tomographie (SPECT) bone scintigraphy

Almog *et al.* (2000)

Pre-/perioperative antibiotics?

- no prospective, controlled data, only case-reports



Adnexal torsion

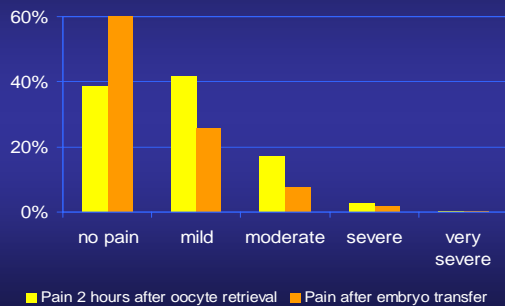
Very rare complication:

- Govaerts et al. (1998): 0.13% (2/1500)
- Bodri et al. 2007: 0.02% (1/4052)



Pain after oocyte retrieval

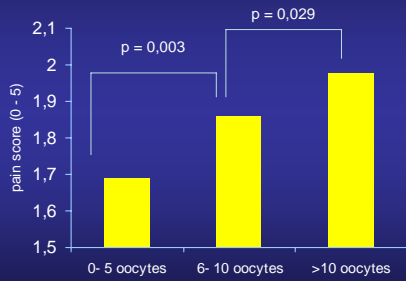
prospective assessment of 1058 patients



Ludwig A.K. et al. Hum Reprod (2006)



Pain depending on number of oocytes



Ludwig A.K. et al. Hum Reprod (2006)

Complications of oocyte pick-up - conclusions for counselling -

- Complications of anaesthesia: very rare
- Vaginal bleeding: 3/ 100
- Severe intraabdominal bleeding: <1/ 1000
- Injury of organs: 1/ 1000
- Pelvic infection: 1-5 /1000
- Adnexal torsion: <1/ 1000
- Severe pain: 3/ 100

Ludwig A.K. et al. Hum Reprod (2006)

Case for discussion

- 38 year old patient
- male factor infertility
- endometriosis rAFS III
- oocyte pick up for ICSI in 01 / 2007
- tuboovarian – abscess
 - 10 days after oocyte pick up
 - → severe abdominal pain, fever
- Treatment: laparoscopy and laparotomy, antibiotic treatment, hospitalisation for 2 weeks

Case for discussion

- 09 / 2007
→ patient returned for another ICSI cycle
- **Questions:**
 - What is her risk to have another tuboovarian-abscess?
 - Is there a possibility of prophylaxis?
 - e.g. intravaginal desinfection preoperatively
 - e.g. peri-operative antibiotics
 - Would you take the risk to perform another oocyte pick-up in this patient?

