

## Uterine congenital anomalies

Marco Gergolet, MD, MSc  
Endoscopy in reproductive medicine  
Leuven

---

---

---

---

---

---

---

---

## Congenital uterine anomalies Prevalence

A critical analysis of studies from 1950 to 2007, done with different diagnostic tools :

- Most accurate diagnostic procedures:
  - hysteroscopy + laparoscopy
  - sonohysterography (SHG)
  - 3D ultrasound
- Less accurate tools:
  - 2D US, and HSG

The study found a 6.7% prevalence of congenital uterine anomalies in the general population, 7.3% in the infertile population and 16.7% in the RM population.

The arcuate uterus was the commonest anomaly found in the general and RM population.

Septate uterus was the commonest anomaly found in the infertile population

(Sarvelos Hum Rep Update 2008)

---

---

---

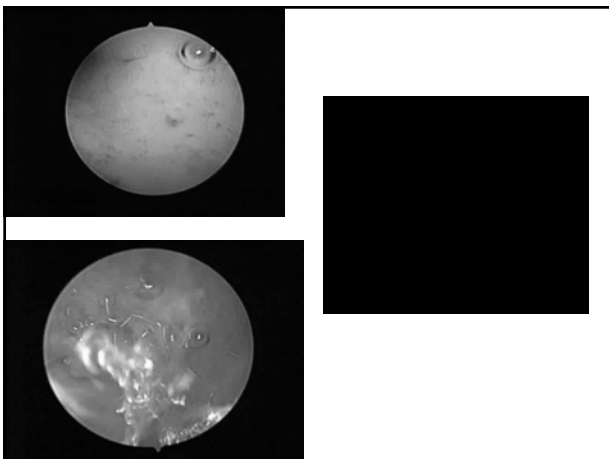
---

---

---

---

---



---

---

---

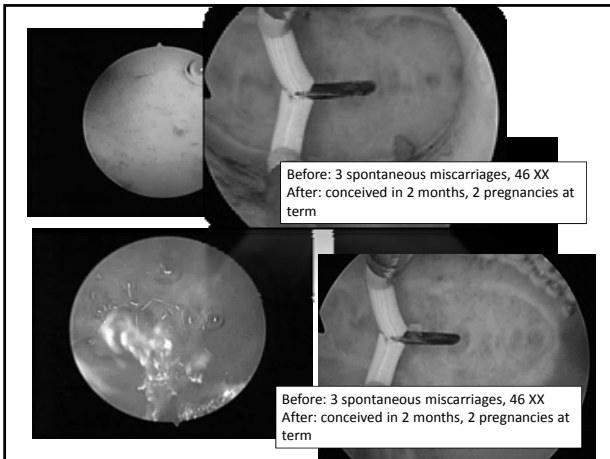---

---

---

---

---




---

---

---

---

---

---

---

---

### Prevalence of congenital uterine malformations General population

Author	Method	Anomalies (%)
Raga 1997	HSG, HSC	3.8
Acién 1997	Vag. US, HSG	4.6*, 7.8**, 16.7***
Jurković 1997	3D US	5.4
Maneschi 1995	HSC	10
Nasri 1990	US	2.7

\*:Previous term pregnancies, \*\*: previous pregnancies and some miscarriage, \*\*\* nulligravidae

---

---

---

---

---

---

---

---

### Prevalence of congenital uterine malformations Infertile population

Author	Method	Incidence %
Tulandi 1980	HSG	1.0
Sorensen 1981	HSG	23.9
Raga 1996	HSG, Vag. US, 3D US	26.2
Acién 1997	HSG, Vag. US	16.0

---

---

---

---

---

---

---

---

## Prevalence of congenital uterine malformations RM population

Author	Method	Incidence %
Clifford 1994	HSG, Vag US	1.8
Jurković 1995	HSG, Vag, US, 3D US	19.7
Raga 1997	HSG, HSC, LAP	6.3
Acien 1997	HSG, Vag, US	25.4

---

---

---

---

---

---

---

---

---

---

## Prevalence of different types of uterine malformations

Author	Method	Arcuate %	Septate %
Exalto 1978	US, Lap	4	40
Acien 1996	Vag US, HSG	27.1	17.1
Raga 1997	HSG, HSC	32.8	33.6
Vercellini 1999	HSC	8.1	54.2

---

---

---

---

---

---

---

---

---

---

### AFS Classification

**Class I:** segmental agenesis and variable degrees of uterovaginal hypoplasia.

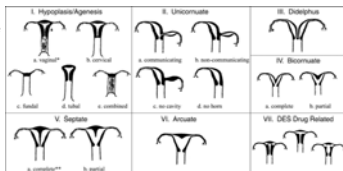
**Class II:** unicornuate uteri (partial or complete unilateral hypoplasia).

**Class III:** uterus didelphys (duplication of the uterus results from complete nonfusion of the müllerian ducts).

**Class IV:** bicornuate uteri with incomplete fusion of the superior segments of the uterovaginal canal.

**Class V:** septate uterus, the external shape of the uterus is a single unit. (distinct from the bicornuate uterus which can be seen branching into two distinct horns when viewed from the outside).

**Class VI:** Arcuate uterus. The uterus is essentially normal in shape with a small, midline indentation in the fundus which results from failure to completely dissolve the median septum.




---

---

---

---

---

---

---

---

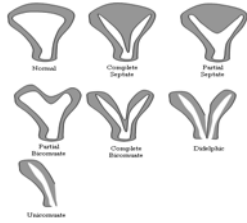
---

---

## TELINDE'S OPERATIVE GYNECOLOGY MODIFIED CLASSIFICATION

(BASED ON EMBRIOLOGIC CONSIDERATION)

This classification  
consider only complete  
septum or partial. The  
term "arcuate uterus"  
has been abandoned,  
considered to be a  
radiologic diagnosis



Telinde's Operative Gynecology 2003

---

---

---

---

---

---

---

---

## TELINDE'S OPERATIVE GYNECOLOGY MODIFIED CLASSIFICATION

(BASED ON EMBRIOLOGIC CONSIDERATION)

**Class I: Dysgenesis of Mullerian Ducts:** includes agenesis of uterus and vagina (Mayer-Rokitansky-Kuester-Hauser syndrome)

**Class II: Disorders of the Vertical Fusion of the Mullerian Ducts:** transverse vaginal septum, cervical agenesis or dysgenesis

**Class III: Disorders of the Lateral Fusion of the Mullerian Ducts:** can be symmetric - unobstructed or asymmetric - obstructed. Obstructive forms associated with absence of ipsilateral kidney. Bilateral obstruction associated with bilateral kidney agenesis- nonviability of the embryo.

**Three asymmetric obstructions**

Unicornuate uterus, Unilateral obstruction of a cavity of double uterus, Unilateral vaginal obstruction

**Five symmetric unobstructed disorders**

Didelphic ut., Septate ut., Bicornuate ut., T shaped and unicornuate with rudimentary horn

**Class IV: Unusual Configuration of Vertical - Lateral Fusion Defects:** unusual configuration of abnormalities

Telinde's Operative Gynecology 2003

---

---

---

---

---

---

---

---

**WHICH IS THE BEST DIAGNOSTIC  
TOOL?**

---

---

---

---

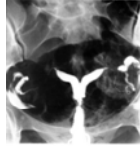---

---

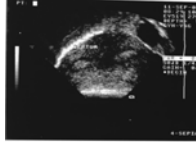
---

---

HSG: Characterization of uterine anomalies can be difficult, however, especially regard to differentiation of a septate from a bicornuate uterus  
(Pellerito 1992)



Vaginal US: reported accuracy of approximately 90%–92%  
(Pellerito 1992)



---

---

---

---

---

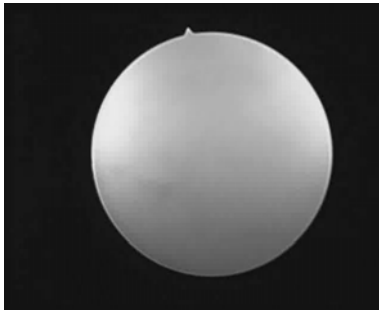
---

---

---

### Diagnostic “office” hysteroscopy

- Visual confirmation of US findings
- Elective in case of uncertain ultrasound
- High compliance of patients. No need of anesthesia or analgesia.



---

---

---

---

---

---

---

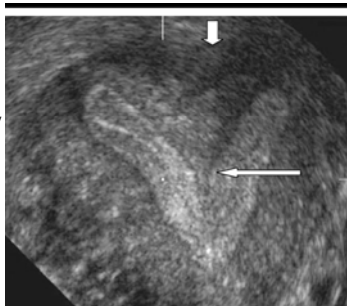
---

### 3D US

3D ultrasound is a reproducible method for the diagnosis of congenital uterine anomalies and for the measurement of uterine cavity dimensions.  
(Salim et al. 2003)

In experienced hands, a sensitivity of 93% and a specificity of 100% have been achieved

(Kupešić and Kurjak 2000)



---

---

---

---

---

---

---

---

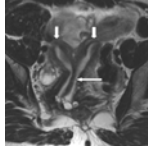
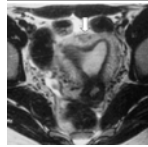
## MRI

Magnetic resonance (MR) imaging has a reported accuracy of up to 100% in the evaluation of muellerian duct anomalies

(Fedele et al. 1989)

Complex anomalies and secondary diagnoses such as endometriosis can often be optimally characterized noninvasively.

(Troiano and McCarty 2004)



---

---

---

---

---

---

---

---

## WHEN IN NECESSARY TO TREAT?

---

---

---

---

---

---

---

---

## When in necessary to treat?

**Pregnancy outcome in untreated patients**

**Pregnancy outcome after metroplasty**

Author	Miscarriage	Preterm d.
Fayez 1986	90.5 %	9.5 %
Perino 1987	88.9 %	11.1 %
Daly 1989	86.7 %	8.7 %
Grimbizis 1998	31.7 %	14.5 %

Author	Miscarriage	Preterm d.
Perino 1987	9.1 %	0 %
Daly 1989	20.2 %	6.0 %
Fedele 1993	15.2 %	15.2 %
Grimbizis 1998	25.0 %	4.5 %

---

---

---

---

---

---

---

---

Author	N. cases	Conclusions
Heinonen et al 2000	17	Women with uterine anomalies who underwent ART had low implantation rates
Pabuçcu et al 2004	61	11% spontaneous misc. after metroplasty (9 cerclage)
Dendrinis et al. 2005	411	Treatment significantly reduced the miscarriage rate
Pace et al.2006	40	75 % spontaneous pregnancy achieved
Kormanyos et al. 2006	94	Removal even of small residual septa > 1 cm after metroplasty
Ban & Tomažević et al 2007	31	Resection of <i>small</i> uterine septa, improves implantation rate in IVF cycles.

---

---

---

---

---

---

---

---

---

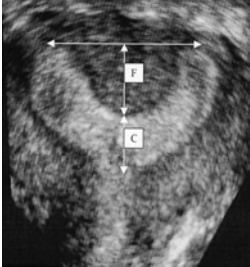
---

**Uterine anomalies – rationale for treatment**

The distortion of uterine anatomy is more severe in congenital anomalies, which are found in women with a history of recurrent first trimester miscarriage.

The degree of distortion of uterine architecture was quantified by the ratio  $F/F+C$ , where F was the length of the uterine septum or depth of the fundal indentation and C was the length of the remaining uterine cavity

(Salim et al 2003)



- F: length of septum
- C: length of remaining cavity

---

---

---

---

---

---

---

---

---

---

**AIM OF THE STUDY**

Aim of the study was to verify whether hysteroscopic metroplasty could be advantageous in treatment of primary and secondary infertility in term of shortening of pregnancy seeking time and reduction of spontaneous miscarriage rate.

---

---

---

---

---

---

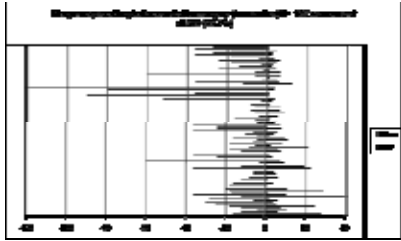
---

---

---

---

Mean duration of infertility before (red) and after (blue) hysteroscopic metroplasty



Median time for achieving a spontaneous pregnancy was 18.0 months (range 2-120) before metroplasty and 4.0 months (range 0-39) after metroplasty ( $p < 0.001$ )

---

---

---

---

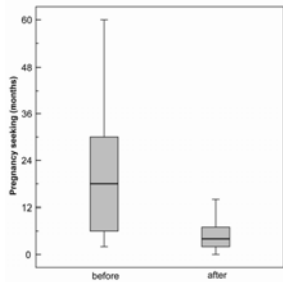
---

---

---

---

Pregnancy seeking before and after metroplasty - nulligravidae




---

---

---

---

---

---

---

---

Outcome	Larger septum (Group 1) n.= 204		Smaller septum (Group 2) n.= 84	
	Before metroplasty	After metroplasty	Before metroplasty	After metroplasty
<b>Pregnancy seeking</b> Months (median and range)	18 (2-120)	4.9 (0-40)	18 (3-108)	4.4 (1-25)
<b>Pregnancies</b>	157	150(137 women)	52	59 (55 women)
<b>Deliveries</b>	32 (20.4 %) a	121 (80.7 %) b	6 (11.5 %) c	51 (86.4 %)d
<b>Abortions</b>	118 (75.2%)	25 (16.7 %)	39 (75 %)	8 (13.6 %)
<b>Ectopic</b>	7 (4.5%)	4 (2.7 %)	7 (13.4 %)	0

Statistics

	Group 1, before vs. after metroplasty	Group 2, before vs. after metroplasty	Before metroplasty, Group 1 vs. Group 2	After metroplasty, Group 1 vs. Group 2
Pregnancy seeking duration (Mann Whitney test)	$p < 0.001$	$p < 0.001$	n.s.	n.s.
Pregnancy failure rate ( $\chi^2$ test)	$p < 0.001$	$p < 0.001$	n.s.	n.s.

---

---

---

---

---

---

---

---



**WHY SEEMS TO BE INDIPENDENT  
FROM THE SIZE?**

---

---

---

---

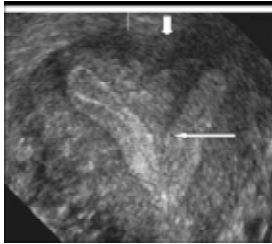
---

---

---

---

### MRI ULTRASTRUCTURE



Imaoka et al. 2003

- MRI intensity similar to the myometrium(Carrington et al 1990)

---

---

---

---

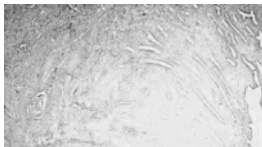
---

---

---

---

### ENDOMETRIUM COVERING SEPTUM



- Fedele described a morphological alteration of mucosa covering the septum (Fedele et al. 1996).

---

---

---

---

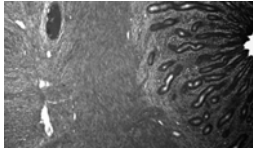
---

---

---

---

## VASCULARIZATION



- Increased miscarriage rate could be consequence of a disrupted vascular architecture within septa (Fayez et al 1986)

---

---

---

---

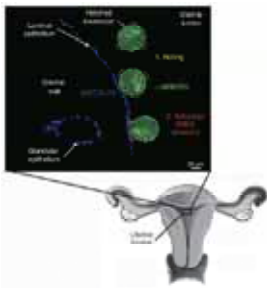
---

---

---

---

## ROLLING AND TETHERING



The mechanism of the trophoblast invasion has analogies with the rolling and tethering of leucocytes on blood vessels. (Red-Horse et al. 2004). Could be that septum covering endometrium cannot express ligands such MECA 79 recognized antibodies that recognize L selectin expressed on blastocyst surface (Red-Horse et al. 2004)

---

---

---

---

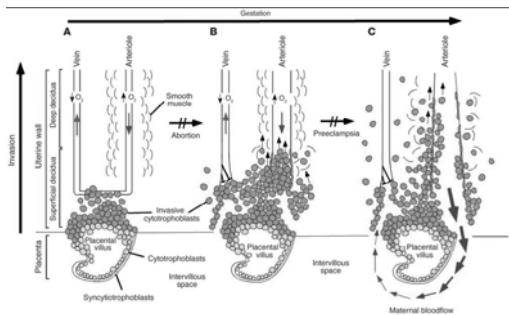
---

---

---

---

## INVASION OF UTERUS



Gerbaev et al. 2004

---

---

---

---

---

---

---

---

## CONCLUSION

Uterine congenital anomalies seem to be an important factor of pregnancy failure and metroplasty seems to improve dramatically the outcome of pregnancies. In front of the benefit of favourable pregnancy outcome after metroplasty, at least vaginal ultrasound should be performed in all cases with history of spontaneous abortion. In case of positive US, office diagnostic hysteroscopy should be performed even after first abortion.

---

---

---

---

---

---

---

---

## CONCLUSION

The long duration of infertility before surgery, absence of other factors to explain their not conceiving, and short time interval subsequent to surgery in which conception occurs, suggests metroplasty has value in treatment of patients with septa and otherwise unexplained infertility

---

---

---

---

---

---

---

---

## CONCLUSION

No differences have been found between women with large septa and those with arcuate uterus either in the obstetric anamnesis before metroplasty or in the outcome after metroplasty. Further studies are needed to assess why the mechanisms that lead to miscarriage seem to be independent from the size of septum.

---

---

---

---

---

---

---

---