

## Patient 1: Kontrol hysteroscopy after myomectomy

32y. G0 P0 A0:  
Subfertility of 3y.

Exploration  
Female

History :	Heavy menstrual periods
Ovulation :	Normal
Biochemistry :	Normal
Ultrasound :	Uterus myomatosus

Male

Sperm normal



European  
**+theAcademy** of  
Gynaecological  
Surgery

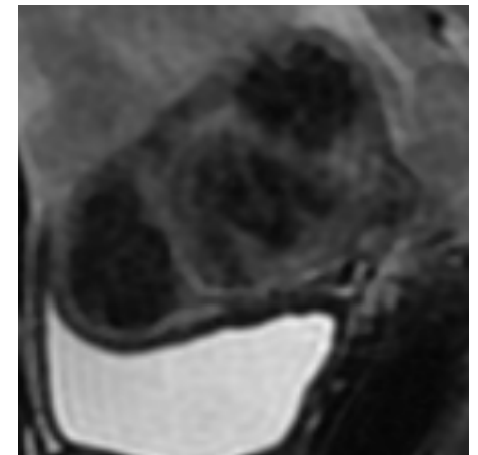
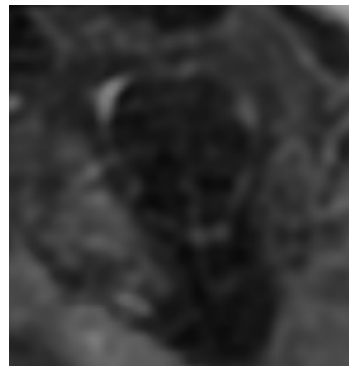
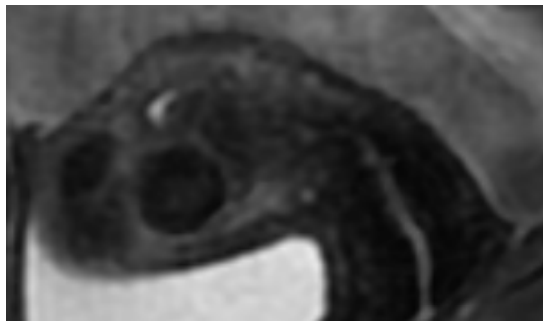


L.I.F.E.

Leuven Institute for Fertility & Embryology

Patient 1: Kontrol hysteroscopy after myomectomy

Pre operative MRI shows multipel myomata in all myometrial regions



09-10-2009

Hysteroscopic exploration with removal of 3 myoma

1 submucuous of 3 cm

2 intramural of max 2 cm



Kontrol Hysteroscopy under sedation

European  
**+theAcademy** of  
Gynaecological  
Surgery



L.I.F.E.

Leuven Institute for Fertility & Embryology

## Patient 2: Hysteroscopy

32y.

G3P0A3: - A1 blind ovum  
- A2 blind ovum  
- A3 Missed abortion at 7 weeks

## Exploration for recurrent miscarriage

History no risk factors

Chromosome NL

Biochemistry NL

Doppler Uterine  
and ovarian vessels NL



European  
**+theAcademy** of  
Gynaecological  
Surgery

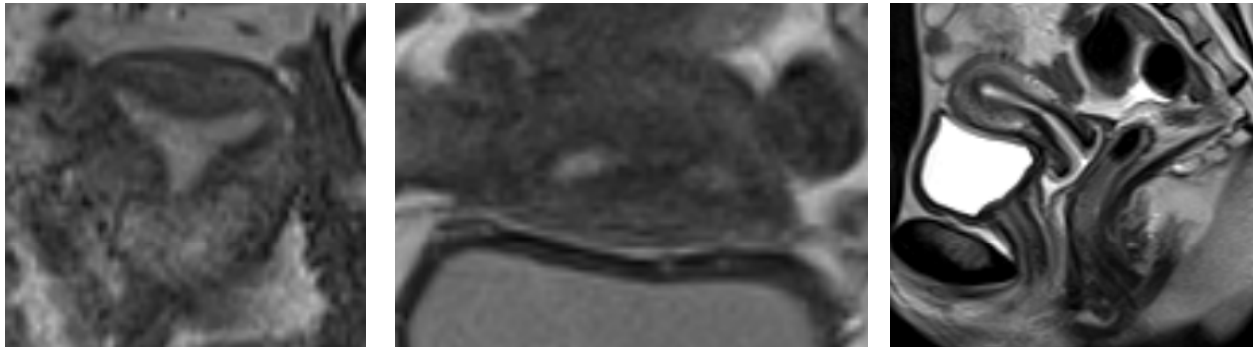


L.I.F.E.

Leuven Institute for Fertility & Embryology

Patient 2 : Hysteroscopy

32y. G3P0A3  
MRI



HSC small septum ?

HOME: Hysteroscopic operative myometrial exploration



L.I.F.E.  
Leuven Institute for Fertility & Embryology

## Patient 3: Hysteroscopy

40 y.

Sec. Subfertility

A0P1G1 : 2001 normal partus

2005 : Embolisation uterus myomatosus (the Netherlands).

10/2009 : Laparoscopy diagnose of bilateral intramural tubal occlusion  
no hysteroscopy performed (the Netherlands).



European  
**+theAcademy** of  
Gynaecological  
Surgery

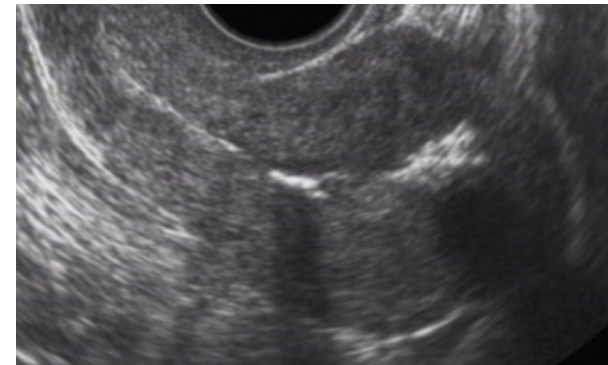


L.I.F.E.

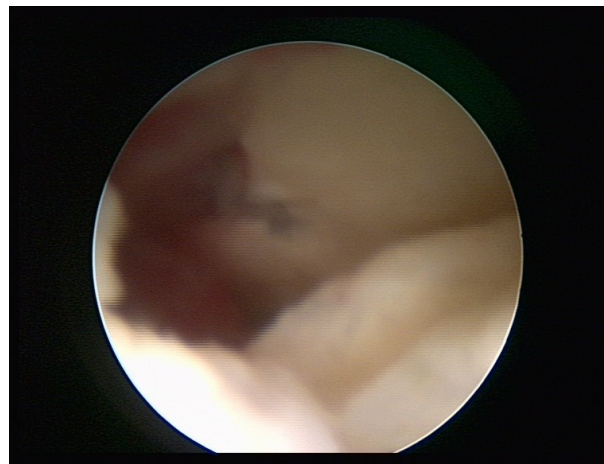
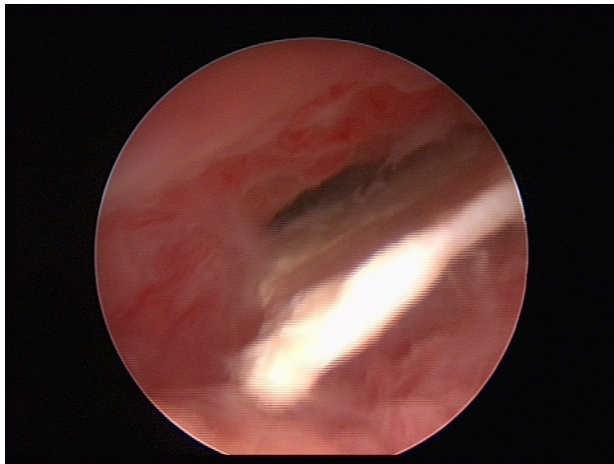
Leuven Institute for Fertility & Embryology

## Patient 3: Hysteroscopy

Referral to Genk for IVF treatment.  
Ultrasound shows hyperechogenic zones



HSC pre IVF shows intrauterine cavity filled with hard material !



European  
**+theAcademy** of  
Gynaecological  
Surgery



Patient 4: Hysteroscopy

33 y.

Sec. Subfertility A1G0P1

2007 : missed abortion

Female fertility exploration : normal

Male : teratospermie (4%)

IUI no pregnancy after 4 trials referral for IVF

HSC pre IVF shows intrauterine blood cloths, Polyp



European  
**+theAcademy** of  
Gynaecological  
Surgery



L.I.F.E.

Leuven Institute for Fertility & Embryology

## Patient 5: Hysteroscopy

34 y.

Sec amenorrhoe

Ovarian drilling

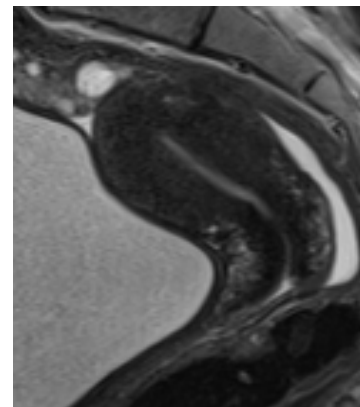
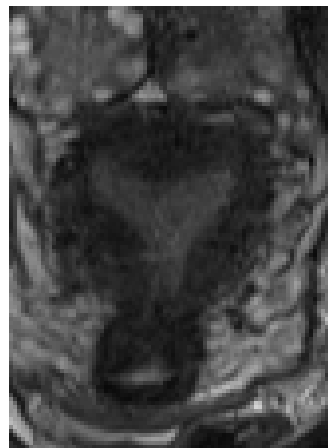2 pregnancies after ovulation induction

Since 09/2007 sec. Subfertility

MRI shows absence of normal myometrial differentiation, arcuate uterus

HSC small septum

Hysteroscopy under sedation after 1 month of GnRH therapy for HOME



European  
**+theAcademy** of  
Gynaecological  
Surgery



L.I.F.E.

Leuven Institute for Fertility & Embryology