

# Knotting



Endoscopy in reproductive medicine  
2011

+theAcademy

---

---

---

---

---


---

---

---

## Knotting

- ✓ Knots classification
- ✓ Knotting technique



+theAcademy

---

---

---

---

---


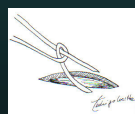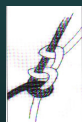
---

---

---

## Knots Classification

- ✓ **Simple knots:**
  - Flat Knot
  - Half loop / Demi-clé
- ✓ **Complete knots:**
  - Square Knot (2 sequential identical flat knots)
  - Surgical Knot (locking sequence of flat knots)
  - Sliding/Rolling Knot (locking sequence of half loops/demi-clé)
  - Sliding/Pushing Knot: Roeder, endoloops



+theAcademy

---

---

---

---

---

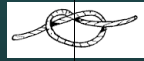
---

---

---

## Flat knot

- ✓ An hypothetical midline divides this knot in two **symmetric parts**
- ✓ To tie this knot we need to pull with equal intensity the two ends of the thread.



theAcademy

---

---

---

---

---

---

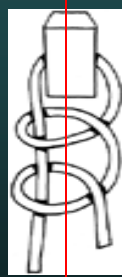
---

---

## Half Loop/Demi-clé

A hypothetical midline divides this knot in two asymmetric parts

To tie this knot we need to pull the passive thread and to push the active one



PASSIVE ACTIVE



theAcademy

---

---

---

---

---

---

---

---

## The Laparoscopic Knotting techniques

The Intra-corporeal Knotting technique

The Extra -corporeal knotting technique



theAcademy

---

---

---

---

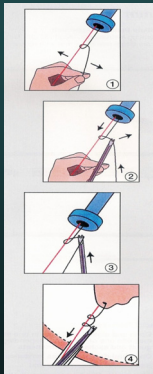
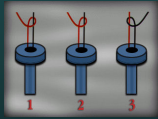
---

---

---

---

## Extracorporeal knot



Length = 120 to 150 cm



theAcademy

---

---

---

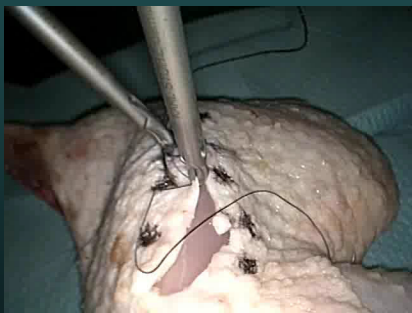
---

---

---

---

## Extracorporeal knotting



theAcademy

---

---

---


---

---

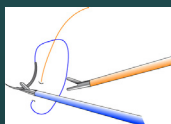
---

---

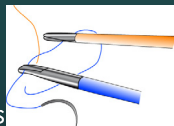
## Intracorporeal Knots



Gladiator



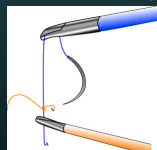
Smiley



Expert



Spaghetti / Noodle



Cinch



theAcademy

Length = 15 to 18 cm

---

---

---


---

---

---

---

## Expert or C-technique



+theAcademy

---

---

---

---


---

---

---

---

## Expert or C-technique



+theAcademy

---

---

---

---


---

---

---

---

## Expert or C-technique



+theAcademy

---

---

---

---

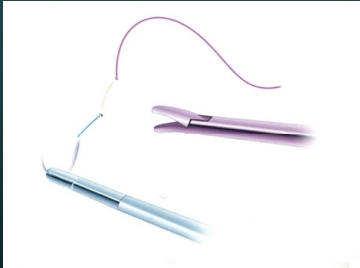
---

---

---

---

## Expert or C-technique



+heAcademy

---

---

---

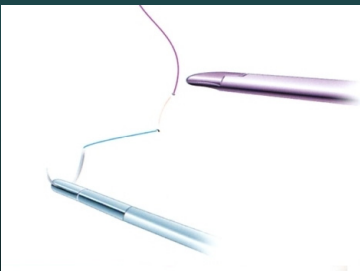
---

---

---

---

## Expert or C-technique



+heAcademy

---

---

---

---

---

---

---

## Expert or C-technique



+heAcademy

---

---

---

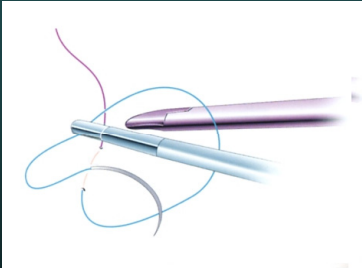
---

---

---

---

## Expert or C-technique



+theAcademy

---

---

---

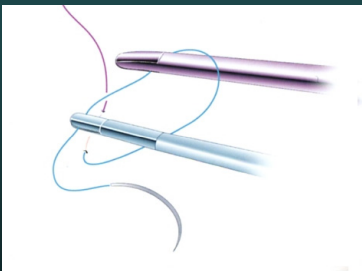
---

---

---

---

## Expert or C-technique



+theAcademy

---

---

---

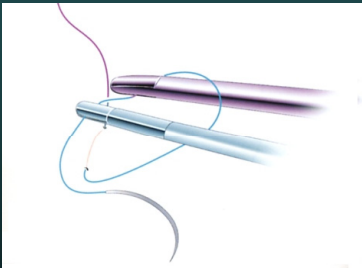
---

---

---

---

## Expert or C-technique



+theAcademy

---

---

---

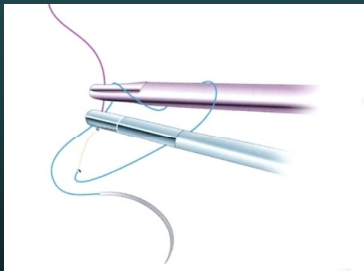
---

---

---

---

## Expert or C-technique



+theAcademy

---

---

---

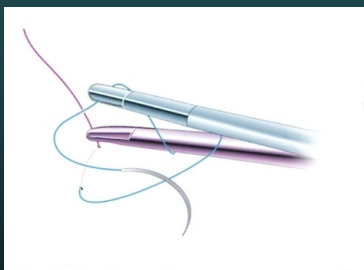
---

---

---

---

## Expert or C-technique



+theAcademy

---

---

---

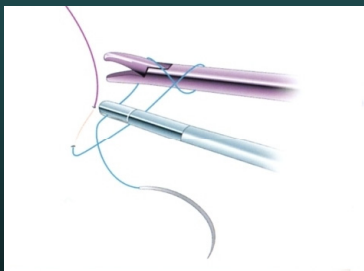
---

---

---

---

## Expert or C-technique



+theAcademy

---

---

---


---

---

---

---

### Expert or C-technique



---

---

---

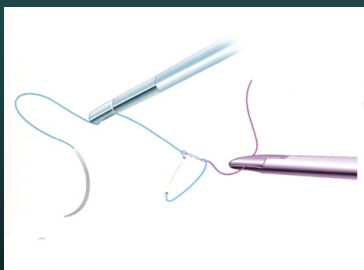
---

---

---

---

### Expert or C-technique



---

---

---

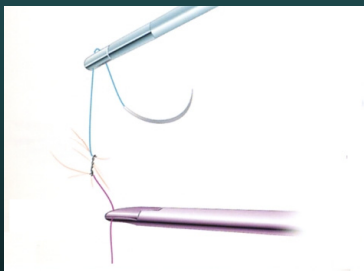
---

---

---

---

### Expert or C-technique



---

---

---

---


---

---

---



## Expert or C-technique



+theAcademy

---

---

---

---

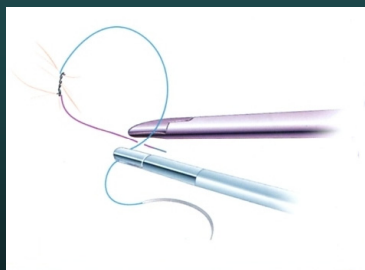---

---

---

---

## Expert or C-technique



+theAcademy

---

---

---

---

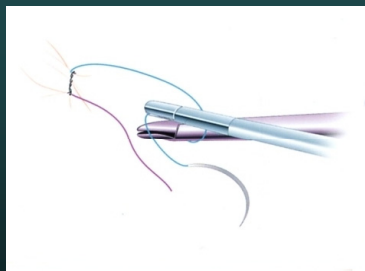
---

---

---

---

## Expert or C-technique



+theAcademy

---

---

---

---

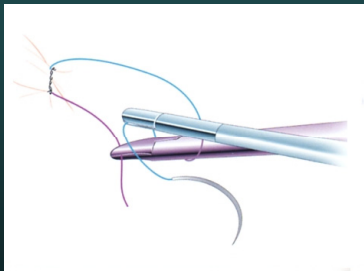
---

---

---

---

### Expert or C-technique



+theAcademy

---

---

---

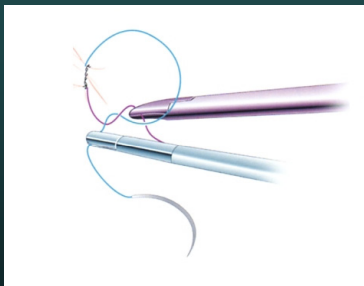
---

---

---

---

### Expert or C-technique



+theAcademy

---

---

---

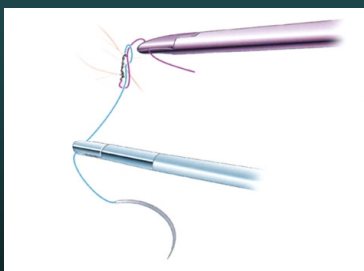
---

---

---

---

### Expert or C-technique



+theAcademy

---

---

---

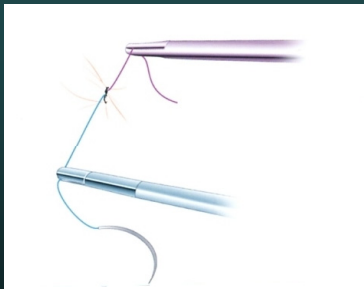
---

---

---

---

### Expert or C-technique



+heAcademy

---

---

---

---

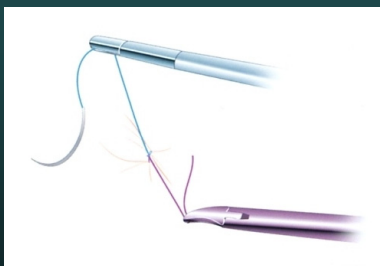
---

---

---

---

### Expert or C-technique



+heAcademy

---

---

---

---


---

---

---

---

### Expert or C-technique



+heAcademy

---

---

---

---

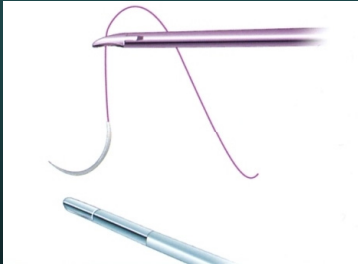---

---

---

---

## Simley technique



+heAcademy

---

---

---

---

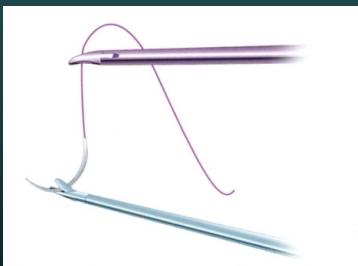
---

---

---

---

## Simley technique



+heAcademy

---

---

---

---

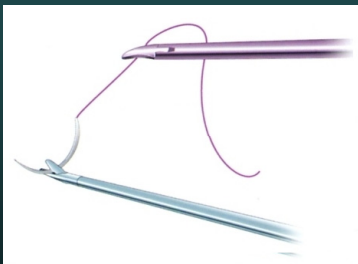---

---

---

---

## Simley technique



+heAcademy

---

---

---

---

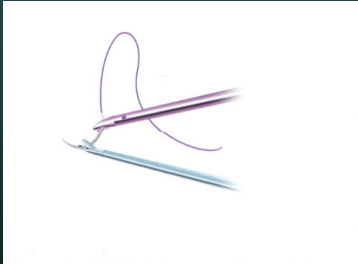
---

---

---

---

## Simley technique



+theAcademy

---

---

---

---

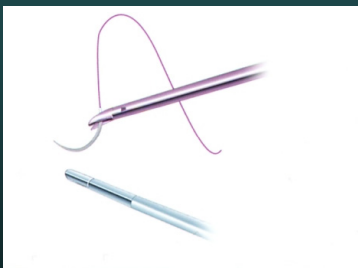
---

---

---

---

## Simley technique



+theAcademy

---

---

---

---


---

---

---

---

## Simley technique



+theAcademy

---

---

---

---

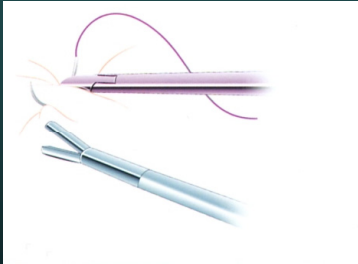
---

---

---

---

## Simley technique



+heAcademy

---

---

---

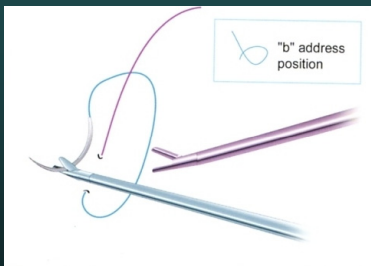
---

---

---

---

## Simley technique



+heAcademy

---

---

---

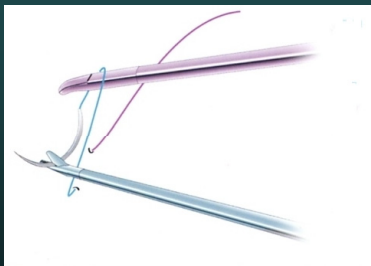
---

---

---

---

## Simley technique



+heAcademy

---

---

---


---

---

---

---

## Simley technique



theAcademy

---

---

---


---

---

---

---

## Simley technique



theAcademy

---

---

---


---

---

---

---

## Simley technique



theAcademy

---

---

---

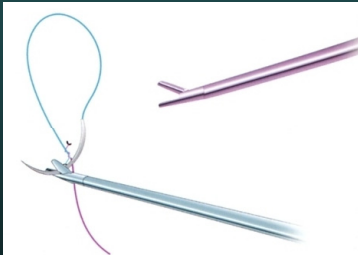
---

---

---

---

## Simley technique



+heAcademy

---

---

---

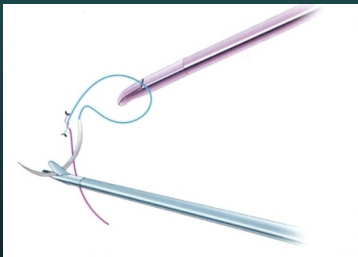
---

---

---

---

## Simley technique



+heAcademy

---

---

---

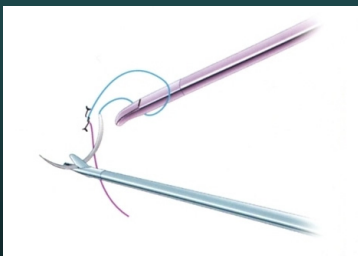
---

---

---

---

## Simley technique



+heAcademy

---

---

---

---

---

---

---



## Simley technique



+theAcademy

---

---

---

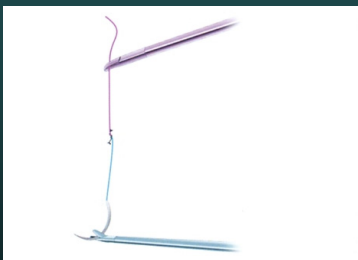
---

---

---

---

## Simley technique



+theAcademy

---

---

---

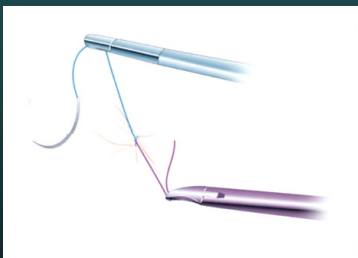
---

---

---

---

## Simley technique



+theAcademy

---

---

---

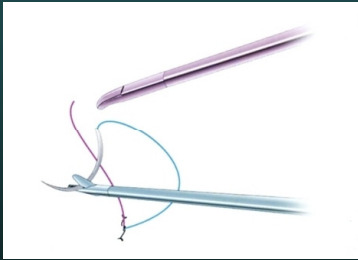
---

---

---

---

## Simley technique



+heAcademy

---

---

---

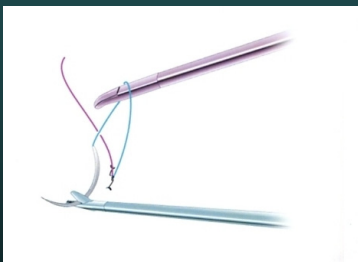
---

---

---

---

## Simley technique



+heAcademy

---

---

---

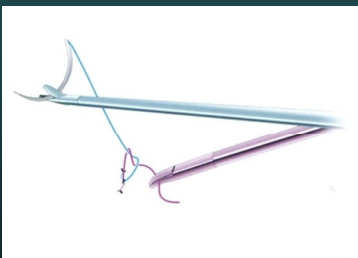
---

---

---

---

## Simley technique



+heAcademy

---

---

---

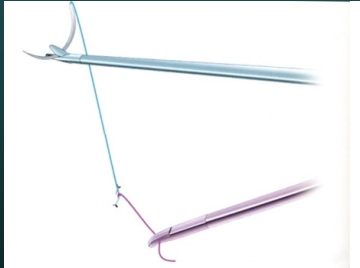
---

---

---

---

## Simley technique



+heAcademy

---

---

---

---

---

---

---

---

## Simley technique



+heAcademy

---

---

---

---

---

---

---

---

## Cinch technique



+heAcademy

---

---

---

---

---

---

---

---

## Cinch technique



theAcademy

---

---

---

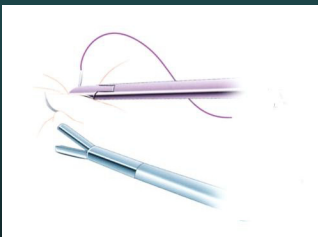
---

---

---

---

## Cinch technique



theAcademy

---

---

---


---

---

---

---

## Cinch technique



theAcademy

---

---

---


---

---

---

---

## Cinch technique



+theAcademy

---

---

---

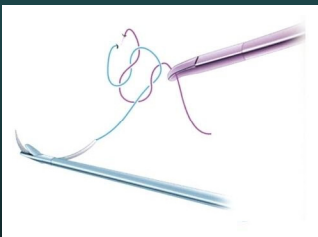
---

---

---

---

## Cinch technique



+theAcademy

---

---

---

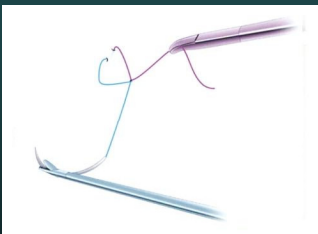
---

---

---

---

## Cinch technique



+theAcademy

---

---

---

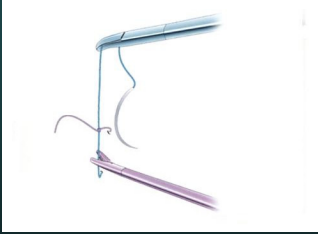
---

---

---

---

## Cinch technique



+heAcademy

---

---

---

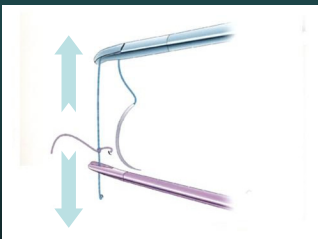
---

---

---

---

## Cinch technique



+heAcademy

---

---

---

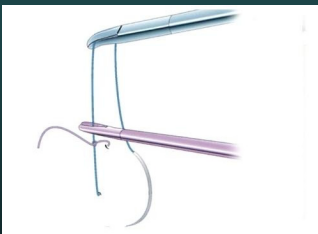---

---

---

---

## Cinch technique



+heAcademy

---

---

---

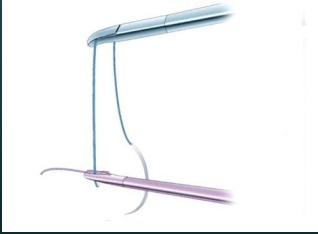
---

---

---

---

## Cinch technique



---

---

---

---

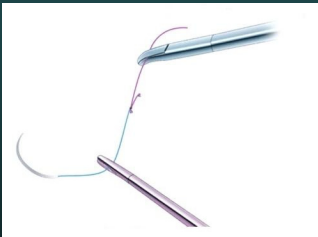
---

---

---

---

## Cinch technique



---

---

---

---

---

---

---

---

## Cinch technique

✓ Cinch



---

---

---

---

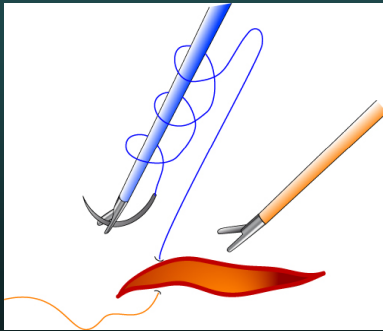
---

---

---

---

## Spaghetti or Noodle technique



+theAcademy

---

---

---

---

---

---

---

---

## Noodle technique

✓ [Spaghetti / Noodles](#)



+theAcademy

---

---

---

---


---

---

---

---

## Gladiator's technique



+theAcademy

---

---

---

---

---

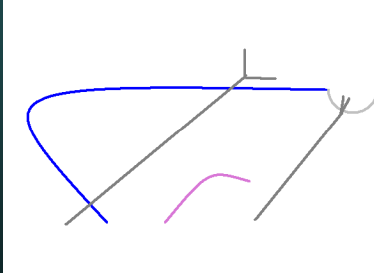
---

---

---



## Gladiator's technique



theAcademy

---

---

---

---

---

---

---

---

## Gladiator's technique



theAcademy

---

---

---

---

---

---

---

---

## Gladiator's technique



theAcademy

---

---

---

---

---

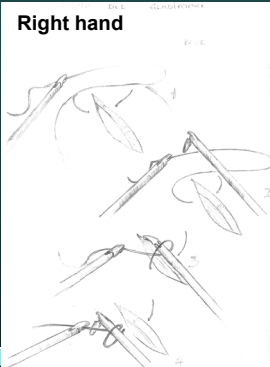
---

---

---

## Gladiator's technique

Right hand



Left hand



---

---

---

---

---

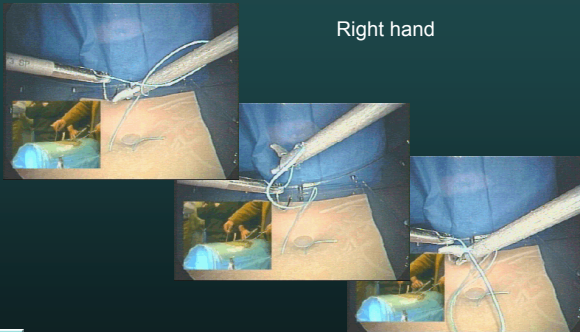
---

---

---

## Gladiator's technique

Right hand



---

---

---

---

---


---

---

---

## Gladiator's technique

Left hand



---

---

---

---

---

---

---

---

## Continuous suturing

- ✓ Knot – suture – knot
- ✓ Suture – single knot at the end



---

---

---

---

---

---

---

## Intracorporeal and extracorporeal knotting - indications

- ✓ Flat knot
  - No overlap of tissue
  - Less risk of leakage
  - Bladder suturing
  - Bowel suturing
- ✓ Half loop
  - Overlap of tissue



---

---

---

---

---

---

---

### INTRACORPOREAL AND EXTRACORPOREAL SUTURING : INDICATIONS

	INTRACORPOREAL KNOTS	EXTRACORPOREAL KNOTS
"SOFT" TISSUES REPAIRATION (URETER, BOWEL, BLADDER...)	+++	+
"SOLIDE" TISSUES REPAIRATION (VAGINA, UTERUS)	++	+++
HEMOSTASIS	-	+++
SUSPENSION/ FIXATION	+	+++
DEEP SURGERY	+	+++



---

---

---

---

---

---

---

## Exercises

- ✓ Extracorporeal knotting
- ✓ Interrupted intra corporeal knotting
  - Expert technique
  - Smiley technique
  - Gladiator technique
- ✓ **NOW** : TRY TO FIND WHAT KNOT SUITS YOU THE MOST
- ✓ **AFTER** : DO THE KNOT YOU ARE USED TO DO



theAcademy

---

---

---

---

---

---

---

Thank you for your attention !



European  
theAcademy of  
Gynaecological  
Surgery

[www.theacademyhouse.org](http://www.theacademyhouse.org)



theAcademy

---

---

---

---

---

---

---