

Do small uterine septa have an impact on reproductive outcome?

Marco Gergolet, MD, MSc
S.I.S.ME.R., Reproductive Medicine Unit, Bologna, Italy
S.I.F.E.S. Slovene Institute for Fertility and Endoscopic
Surgery, Nova Gorica, Slovenia



S.I.F.E.S.
Slovene Institute for Fertility and Endoscopic Surgery

Congenital uterine anomalies Prevalence

A critical analysis of studies from 1950 to 2007, done with different diagnostic tools :

- Most accurate diagnostic procedures:
hysteroscopy + laparoscopy
sonohysterography (SHG)
3D ultrasound
- Less accurate tools:
2D US, and HSG

The study found a 6.7% prevalence of congenital uterine anomalies in the general population, 7.3% in the infertile population and 16.7% in the RM population.

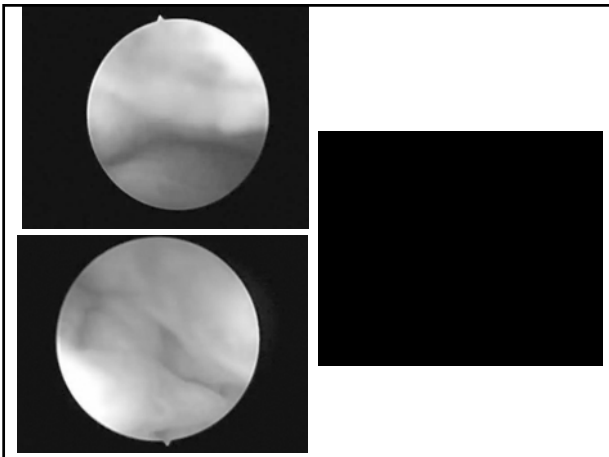
The arcuate uterus was the commonest anomaly found in the general and RM population.

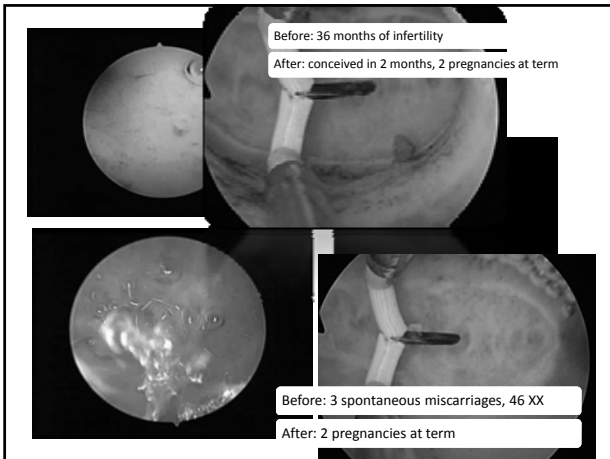
Septate uterus was the commonest anomaly found in the infertile population



S.I.F.E.S.
Slovene Institute for Fertility and Endoscopic Surgery

(Sarvelos Hum Rep Update 2008)





Prevalence of congenital uterine malformations General population

Author	Method	Anomalies (%)
Raga 1997	HSG, HSC	3.8
Acién 1997	Vag. US, HSG	4.6*, 7.8**, 16.7***
Jurković 1997	3D US	5.4
Maneschi 1995	HSC	10
Nasri 1990	US	2.7

*:Previous term pregnancies, **: previous pregnancies and some miscarriage, *** nulligravidae

Slovene Institute for Fertility and Reproductive Surgery

Prevalence of congenital uterine malformations Infertile population

Author	Method	Incidence %
Tulandi 1980	HSG	1.0
Sorensen 1981	HSG	23.9
Raga 1996	HSG, Vag. US, 3D US	26.2
Acién 1997	HSG, Vag. US	16.0

Slovene Institute for Fertility and Reproductive Surgery

Prevalence of congenital uterine malformations RM population

Author	Method	Incidence %
Clifford 1994	HSG, Vag US	1.8
Jurković 1995	HSG, Vag, US, 3D US	19.7
Raga 1997	HSG, HSC, LAP	6.3
Acien 1997	HSG, Vag, US	25.4



Prevalence of different types of uterine malformations

Author	Method	Arcuate %	Septate %
Exalto 1978	US, Lap	4	40
Acien 1996	Vag US, HSG	27.1	17.1
Raga 1997	HSG, HSC	32.8	33.6
Vercellini 1999	HSC	8.1	54.2



AFS Classification

Class I: segmental agenesis and variable degrees of uterovaginal hypoplasia.

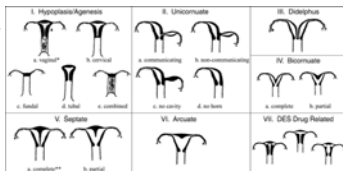
Class II: unicornuate uteri (partial or complete unilateral hypoplasia).

Class III: uterus didelphys (duplication of the uterus results from complete nonfusion of the müllerian ducts).

Class IV: bicornuate uteri with incomplete fusion of the superior segments of the uterovaginal canal.

Class V: septate uterus, the external shape of the uterus is a single unit. (distinct from the bicornuate uterus which can be seen branching into two distinct horns when viewed from the outside).

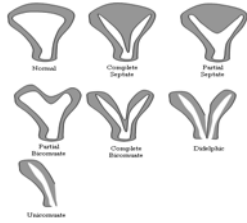
Class VI: Arcuate uterus. The uterus is essentially normal in shape with a small, midline indentation in the fundus which results from failure to completely dissolve the median septum.



TELINDE'S OPERATIVE GYNECOLOGY MODIFIED CLASSIFICATION

(BASED ON EMBRIOLOGIC CONSIDERATION)

This classification consider only complete septum or partial. The term "arcuate uterus" has been abandoned, considered to be a radiologic diagnosis



Slovene Institute for Fertility and Reproductive Surgery

Telinde's Operative Gynecology 2003

TELINDE'S OPERATIVE GYNECOLOGY MODIFIED CLASSIFICATION

(BASED ON EMBRIOLOGIC CONSIDERATION)

Class I: Dysgenesis of Mullerian Ducts: includes agenesis of uterus and vagina (Mayer-Rokitansky-Kuester-Hauser syndrome)
Class II: Disorders of the Vertical Fusion of the Mullerian Ducts: transverse vaginal septum, cervical agenesis or dysgenesis
Class III: Disorders of the Lateral Fusion of the Mullerian Ducts: can be symmetric – unobstructed or asymmetric - obstructed. Obstructive forms associated with absence of ipsilateral kidney. Bilateral obstruction associated with bilateral kidney agenesis- nonviability of the embryo.
Three asymmetric obstructions
 Unicornuate uterus, Unilateral obstruction of a cavity of double uterus, Unilateral vaginal obstruction
Five symmetric unobstructed disorders
 Didelphic ut., Septate ut., Bicornuate ut., T shaped and unicornuate with rudimentary horn
Class IV: Unusual Configuration of Vertical - Lateral Fusion Defects: unusual configuration of abnormalities

Slovene Institute for Fertility and Reproductive Surgery

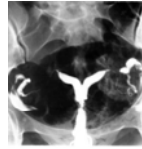
Telinde's Operative Gynecology 2003

WHICH IS THE BEST DIAGNOSTIC TOOL?



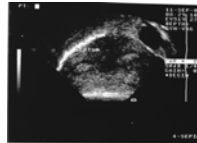
Slovene Institute for Fertility and Reproductive Surgery

HSG: Characterization of uterine anomalies can be difficult, however, especially regard to differentiation of a septate from a bicornuate uterus
(Pellerito 1992)



Vaginal US: reported accuracy of approximately 90%–92%

(Pellerito 1992)

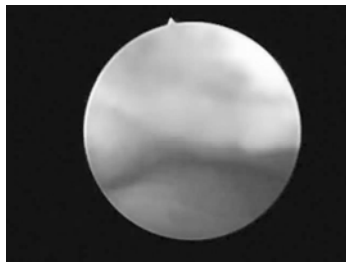


SIFES

Slovene Institute of Family and Reproductive Surgery

Diagnostic “office” hysteroscopy

- No speculum and tenaculum
- Visual confirmation of US findings
- Elective in case of uncertain ultrasound
- High compliance of patients. No need of anesthesia or analgesia.



SIFES

Slovene Institute of Family and Reproductive Surgery

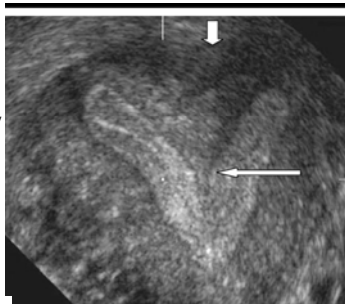
3D US

3D ultrasound is a reproducible method for the diagnosis of congenital uterine anomalies and for the measurement of uterine cavity dimensions.

(Salim et al. 2003)

In experienced hands, a sensitivity of 93% and a specificity of 100% have been achieved

(Kupešić and Kurjak 2000)



SIFES

Slovene Institute of Family and Reproductive Surgery

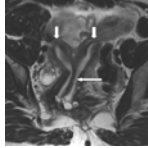
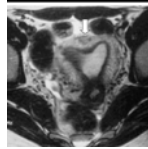
MRI

Magnetic resonance (MR) imaging has a reported accuracy of up to 100% in the evaluation of muellerian duct anomalies

(Fedele et al. 1989)

Complex anomalies and secondary diagnoses such as endometriosis can often be optimally characterized noninvasively.

(Troiano and McCarty 2004)



Slovene Institute of Fertility and Reproductive Surgery **SIFES**

WHEN IN NECESSARY TO TREAT?



Slovene Institute of Fertility and Reproductive Surgery **SIFES**

When in necessary to treat?

Pregnancy outcome in untreated patients

Pregnancy outcome after metroplasty

Author	Miscarriage	Preterm d.
Fayez 1986	90.5 %	9.5 %
Perino 1987	88.9 %	11.1 %
Daly 1989	86.7 %	8.7 %
Grimbizis 1998	31.7 %	14.5 %

Author	Miscarriage	Preterm d.
Perino 1987	9.1 %	0 %
Daly 1989	20.2 %	6.0 %
Fedele 1993	15.2 %	15.2 %
Grimbizis 1998	25.0 %	4.5 %



Slovene Institute of Fertility and Reproductive Surgery **SIFES**

Author	N. cases	Conclusions
Heinonen et al 2000	17	Women with uterine anomalies who underwent ART had low implantation rates
Pabuçcu et al 2004	61	11% spontaneous misc. after metroplasty (9 cerclage)
Dendrinis et al. 2005	411	Treatment significantly reduced the miscarriage rate
Pace et al.2006	40	75 % spontaneous pregnancy achieved
Kormanyos et al. 2006	94	Removal even of small residual septa > 1 cm after metroplasty
Ban & Tomaževič et al 2007	31	Resection of <i>small</i> uterine septa, improves implantation rate in IVF cycles.

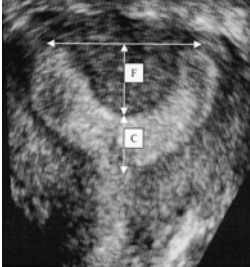


Uterine anomalies – rationale for treatment

The degree of distortion of uterine architecture was quantified by the ratio $F/F+C$, where F was the length of the uterine septum or depth of the fundal indentation and C was the length of the remaining uterine cavity

The distortion of uterine anatomy is more severe in congenital anomalies, which are found in women with a history of recurrent first trimester miscarriage.

(Salim et al 2003)



- F: length of septum
- C: length of remaining cavity



AIM OF THE STUDY

Aim of the study was to verify whether hysteroscopic metroplasty of small uterine septa (arcuata) could be advantageous in term of shortening of the pregnancy seeking time and reducing miscarriage rate.



MATERIALS AND METHODS

288 patients were included in the study.

From the study were excluded cases with male factor infertility and bilateral tubal pathology, ovulatory disorders, because of the need of ART or other hormonal treatment.

Unilateral tubal occlusion or "status post" salpingectomy due to ectopic pregnancy were admitted to the study in case of contralateral tubal patency.

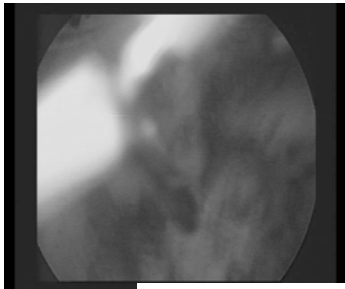


Preparation of endometrium:
Contraceptive pill till 10 days
before metroplasty
(synchronization)

8 mm monopolar operative
hysteroscope with 1.5 % glycine or 5
% glucose solution as distension
medium
or a bipolar resectoscope and
saline solution as distension
medium.

No postoperative complications

Day surgery



Slovene Institute of Fertility and Reproductive Surgery
SIFERS

MATERIALS AND METHODS

A database file was set up using Microsoft Excel for Windows (Redmond, WA, USA) to facilitate data entry and retrieval.

SPSS/PC 14.0 program was used for statistical analysis. Kolmogorov - Smirnov test showed non normal distribution of the variables "months of infertility before surgery" and "months of infertility after surgery". Due to this abnormal distribution a Wilcoxon Mann Whitney non-parametric test was used for analyzing those variables.

Differences between groups were analyzed by the Pearson's χ^2 test.




Slovene Institute of Fertility and Reproductive Surgery
SIFERS

Outcome	Larger septum (Group 1) n.= 204		Smaller septum (Group 2) n.= 84	
	Before metroplasty	After metroplasty	Before metroplasty	After metroplasty
Pregnancy seeking Months (median and range)	18 (2-120)	4.9 (0-40)	18 (3-108)	4.4 (1-25)
Pregnancies	157	150 (137 women)	52	59 (55 women)
Deliveries	32 (20.4 %) a	121 (80.7 %) b	6 (11.5 %) c	51 (86.4 %)d
Abortions	118 (75.2%)	25 (16.7 %)	39 (75 %)	8 (13.6 %)
Ectopic	7 (4.5%)	4 (2.7 %)	7 (13.4 %)	0

Statistics

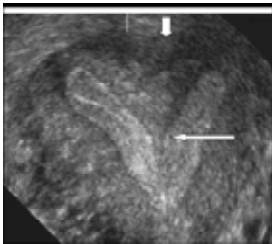
	Group 1, before vs. after metroplasty	Group 2, before vs. after metroplasty	Before metroplasty, Group 1 vs. Group 2	After metroplasty, Group 1 vs. Group 2
Pregnancy seeking duration (Mann Whitney test)	p < 0.001	p < 0.001	n.s.	n.s.
Pregnancy failure rate (χ^2 test)	p < 0.001	p < 0.001	n.s.	n.s.

WHY SEEMS TO BE INDEPENDENT FROM THE SIZE?




Slovene Institute for Fertility and Reproductive Surgery

MRI ULTRASTRUCTURE



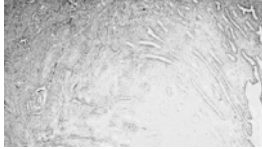
- MRI intensity similar to the myometrium (Carrington et al 1990)

...a et al. 2003



Slovene Institute for Fertility and Reproductive Surgery

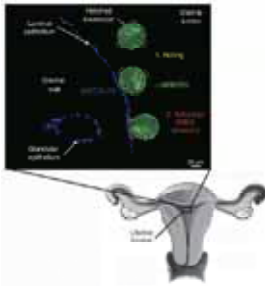
ENDOMETRIUM COVERING SEPTUM



- Fedele described a morphological alteration of mucosa covering the septum (Fedele et al. 1996).



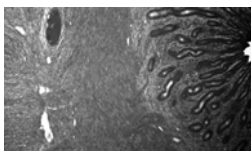
ROLLING AND TETHERING



The mechanism of the trophoblast invasion has analogies with the rolling and tethering of leucocytes on blood vessels. (Red-Horse et al. 2004). Could be that septum covering endometrium cannot express ligands such MECA 79 recognized antibodies that recognize L selectin expressed on blastocyst surface (Red-Horse et al. 2004)



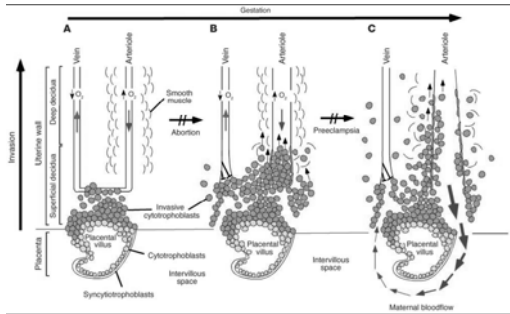
VASCULARIZATION



- Increased miscarriage rate could be consequence of a disrupted vascular architecture within septa (Fayez et al 1986)



INVASION OF UTERUS



Gerbacev et al. 2004

CONCLUSION

The long duration of infertility before surgery, absence of other factors to explain their not conceiving, and short time interval subsequent to surgery in which conception occurs, suggests metroplasty has value in treatment of patients either with septate or arcuate uterus.



CONCLUSION

No differences have been found between women with large septa and those with arcuate uterus either in the obstetric history before metroplasty or in the outcome after metroplasty. Further studies are needed to assess why the mechanisms that lead to miscarriage seem to be independent from the size of septum.