

# ADOLESCENT VARICOCELE

***Giorgio Bozzini***

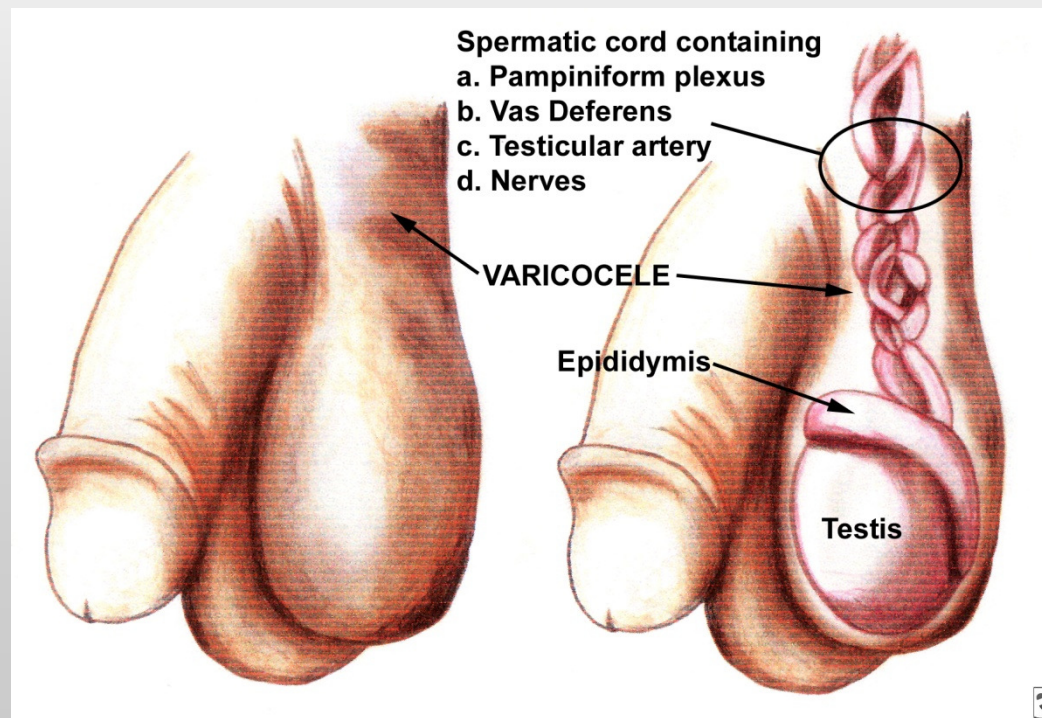
**Academic Division of Urology,  
IRCCS Policlinico San Donato,  
University of Milan**

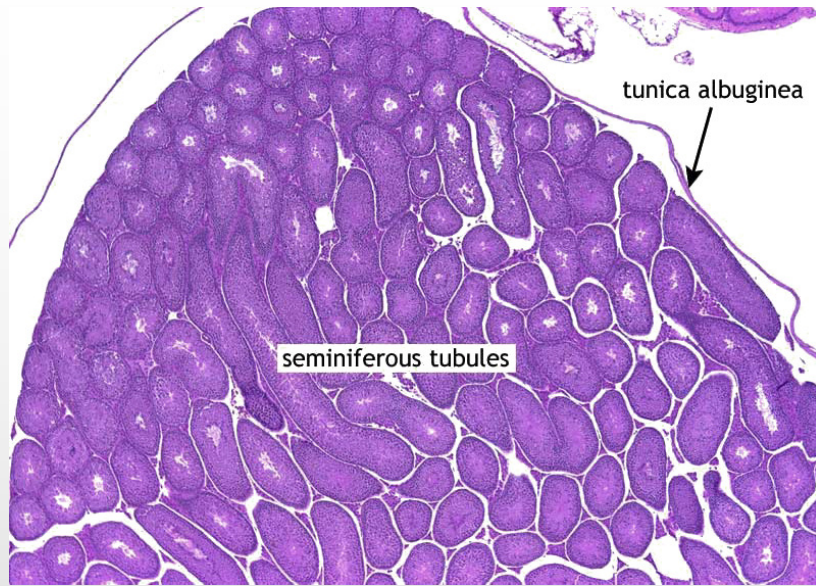
**H.Dep: prof. L. Carmignani**



# INTRODUCTION

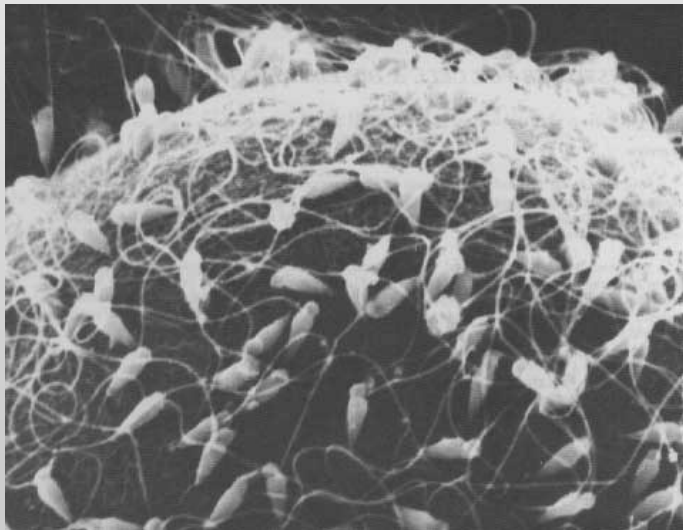Varicocele is an abnormal dilation of the veins of the pampiniform plexus of the spermatic cord and represents the most common identifiable cause of male infertility.





## MECHANISM?

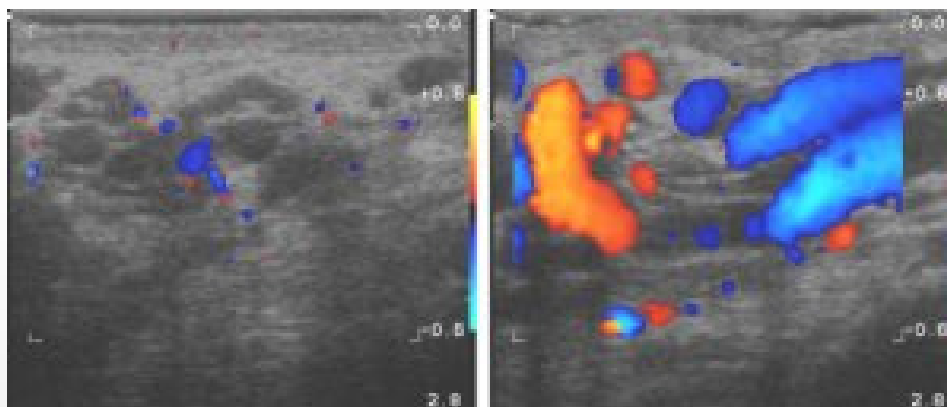
Many theories have been proposed to explain the mechanism by which the disease disrupts normal testicular function and causes infertility; however, none has been proved and the exact cause remains an enigma.



# Interest on Adolescents



Interest has **focused on adolescents** with a varicocele because varicocelectomy in the adolescent population has been proposed as a **therapeutic intervention both to preserve fertility and to preserve testicular growth**

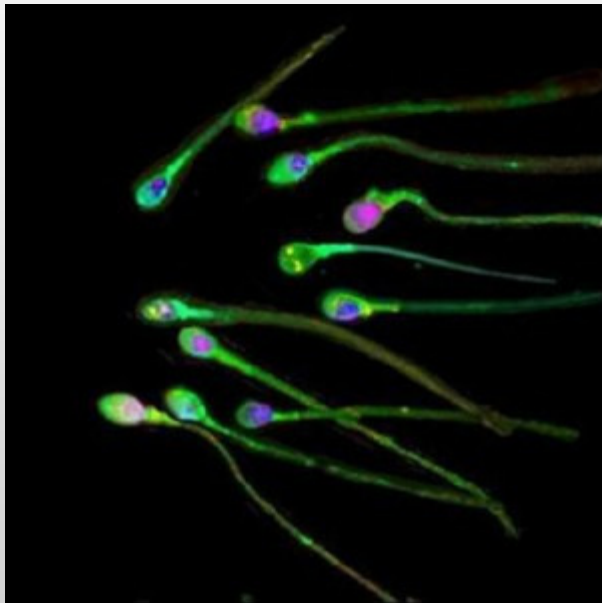

Adolescent varicocele is becoming a more widely appreciated and diagnosed entity.

Although the **incidence** of adolescent varicoceles has been **estimated at 15%**, some have reported a rate as high as **29%**.

The widespread use of **testicular ultrasound** has helped to further define scrotal anatomy and **identify subclinical varicoceles**.

# Risk of infertility?



However, because these patients are younger, perhaps the affected testicle will be exposed to the deleterious effects of the varicocele for a longer period of time.

**Does this mean that these patients are at higher risk for infertility?**

0022-5347/97/1582-0605\$03.00/0

THE JOURNAL OF UROLOGY

Copyright © 1997 by AMERICAN UROLOGICAL ASSOCIATION, INC.

Vol. 158, 605-607, August 1997

Printed in U.S.A.

## IPSILATERAL TESTICULAR HYPOTROPHY IS ASSOCIATED WITH DECREASED SPERM COUNTS IN INFERTILE MEN WITH VARICOCELES

MARK SIGMAN AND JONATHAN P. JAROW\*

*From the Departments of Urology, Brown University School of Medicine, Providence, Rhode Island, and Bowman Gray School of Medicine, Wake Forest University, Winston-Salem, North Carolina*

In 1997, Sigman and Jarow identified an **association between ipsilateral hypotrophy and larger varicoceles in adults** and found that both were associated with worse semen parameters.

**So the practice of adolescent varicocelectomy for ipsilateral hypotrophy made sense.**

## IPSILATERAL TESTICULAR HYPOTROPHY IS ASSOCIATED WITH DECREASED SPERM COUNTS IN INFERTILE MEN WITH VARICOCELES

MARK SIGMAN AND JONATHAN P. JAROW\*

*From the Departments of Urology, Brown University School of Medicine, Providence, Rhode Island, and Bowman Gray School of Medicine, Wake Forest University, Winston-Salem, North Carolina*

But this study is retrospective, varicocele was graduated clinically, hypotrophy was defined as a 3 cc difference in the size of the testes, and testicular size was measured using a Takihara orchidometer.

While the patients with grade III varicocele had a statistically higher likelihood of hypotrophy, **there was no difference between patients with grade I and grade II varicocele.**



## TESTICULAR HYPOTROPHY DOES NOT CORRELATE WITH GRADE OF ADOLESCENT VARICOCELE

JOSEPH P. ALUKAL,\* DAVID ZURAKOWSKI, ANTHONY ATALA, STUART B. BAUER,  
JOSEPH G. BORER, BARTLEY G. CILENTO, JR., JAMES MANDELL, CRAIG A. PETERS,  
HARRIET J. PALTIEL, ALAN B. RETIK AND DAVID A. DIAMOND

*From the Department of Urology, Children's Hospital Boston, Boston, Massachusetts*

### ABSTRACT


**Purpose:** Testicular hypotrophy is the most widely accepted indication for correcting adolescent varicocele. Previous studies in adolescents have shown a relationship between increasing grade of varicocele and the likelihood of testicular hypotrophy. As this relationship has significant clinical implications, we studied the correlation between grade and testicular volume disproportion in our adolescent varicocele population.

**Materials and Methods:** We reviewed the adolescent varicocele database at our institution. A total of 168 patients 8 to 21 years old were studied. We routinely calculated testis volumes using scrotal ultrasound. Testicular disproportion was calculated using the equation  $[(\text{size of unaffected testis}) - (\text{size of affected testis})]/(\text{size of unaffected testis}) \times 100\%$ . Disproportion was categorized as less than 10%, 10% to 20% and more than 20%. Varicoceles were graded by an attending urologist with the patient standing, using the system of Dubin and Amelar. Analysis of variance and Pearson chi-square indicated no significant differences in volume differential between varicocele grades.

**Results:** Mean  $\pm$  SD volume differential was  $18\% \pm 15\%$  for grade I,  $25\% \pm 20\%$  for grade II and  $19\% \pm 14\%$  for grade III. ANOVA revealed no significant difference in mean volume differential between the 3 varicocele grades ( $p = 0.10$ ). When categorizing patients into 3 levels of volume differential (less than 10%, 10% to 20%, more than 20%) no significant correlation was observed between varicocele and volume differential ( $p = 0.48$ , chi-square test).

**Conclusions:** Grade of varicocele does not correlate with presence or severity of testicular disproportion in adolescent boys with varicocele as measured by scrotal ultrasound.

KEY WORDS: varicocele, adolescent, testis, growth and development



An another study showed that varicocele grade does not correlate with abnormal semen analysis.

This series differed from previously published series most notably in the use of ultrasound for measurement of testicular volumes and grade of varicocele, which is potentially more accurate.

## TESTICULAR HYPOTROPHY DOES NOT CORRELATE WITH GRADE OF ADOLESCENT VARICOCELE

JOSEPH P. ALUKAL,\* DAVID ZURAKOWSKI, ANTHONY ATALA, STUART B. BAUER,  
JOSEPH G. BORER, BARTLEY G. CILENTO, JR., JAMES MANDELL, CRAIG A. PETERS,  
HARRIET J. PALTIEL, ALAN B. RETIK AND DAVID A. DIAMOND

*From the Department of Urology, Children's Hospital Boston, Boston, Massachusetts*

### ABSTRACT

**Purpose:** Testicular hypotrophy is the most widely accepted indication for correcting adolescent varicocele. Previous studies in adolescents have shown a relationship between increasing grade of varicocele and the likelihood of testicular hypotrophy. As this relationship has significant clinical implications, we studied the correlation between grade and testicular volume disproportion in our adolescent varicocele population.

**Materials and Methods:** We reviewed the adolescent varicocele database at our institution. A total of 168 patients 8 to 21 years old were studied. We routinely calculated testis volumes using scrotal ultrasound. Testicular disproportion was calculated using the equation [(size of unaffected testis) - (size of affected testis)]/(size of unaffected testis) × 100%. Disproportion was categorized as less than 10%, 10% to 20% and more than 20%. Varicoceles were graded by an attending urologist with the patient standing, using the system of Dubin and Amelar. Analysis of variance and Pearson chi-square indicated no significant differences in volume differential between varicocele grades.

**Results:** Mean ± SD volume differential was 18% ± 15% for grade I, 25% ± 20% for grade II and 19% ± 14% for grade III. ANOVA revealed no significant difference in mean volume differential between the 3 varicocele grades (p = 0.10). When categorizing patients into 3 levels of volume differential (less than 10%, 10% to 20%, more than 20%) no significant correlation was observed between varicocele and volume differential (p = 0.48, chi-square test).

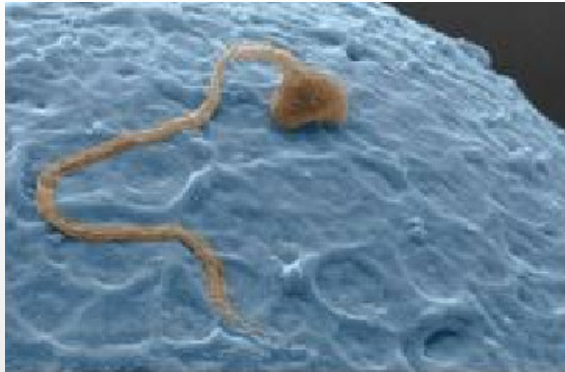**Conclusions:** Grade of varicocele does not correlate with presence or severity of testicular disproportion in adolescent boys with varicocele as measured by scrotal ultrasound.

**KEY WORDS:** varicocele, adolescent, testis, growth and development

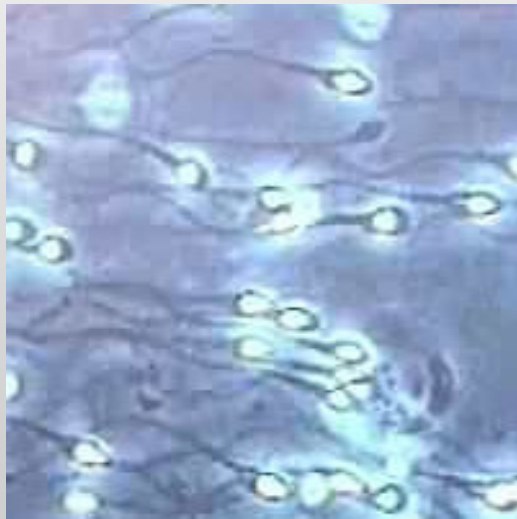
Results showed no difference in relationship of varicocele severity to hypotrophy based on age.

This analysis was performed using a cutoff of 15 years, beyond which most adolescents are considered postpubertal. In the younger and older patients no significant association between grade of varicocele and hypotrophy was identified.

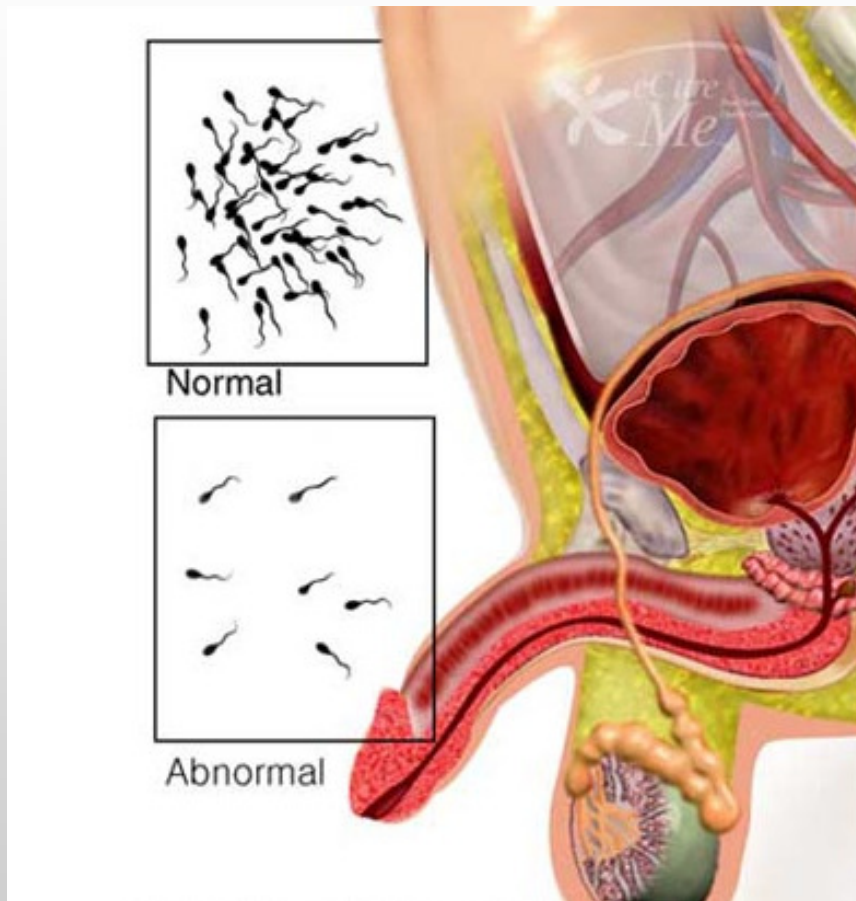
This finding argues against the possibility that the effect of a varicocele needs to be present during specific periods of pubertal development for clinically significant hypotrophy to occur.



In addition, it has been shown that **ipsilateral testicular hypotrophy can be a progressive phenomenon, and in the presence of hypotrophy semen parameters can continue to worsen with age.**



Supporting the notion that progressive testicular damage can occur with time is the **higher incidence of varicoceles found in men who have already fathered a child but cannot again** (secondary infertility) as compared with males who have never fathered a child (primary).



Gorelick and Goldstein found **varicoceles in 35% of males with primary infertility**, but in **secondary infertility, there was an 82% incidence of varicocele**.

The implication here is that **men with secondary infertility represent an older group who are fertile initially but with time, injury from the varicocele is progressive**, resulting in abnormal semen analysis.

*BJU International* (2001), 87, 499–501

## **Varicocele in adolescence induces left and right testicular volume loss**

E.J. KASS, B.R. STORK and B.W. STEINERT

*Division of Paediatric Urology, Department of Urology, William Beaumont Hospital, Royal Oak, Michigan*

It is intuitive to believe that because a left varicocele can effect total sperm count and other semen parameters, the right testicle also must be affected.

**The finding that the right testicle is often smaller in the presence of a left varicocele (though to a lesser degree) supports this hypothesis, and this contralateral hypotrophy can be seen as early as adolescence.**

*BJU International* (2001), 87, 499–501

## **Varicocele in adolescence induces left and right testicular volume loss**

E.J. KASS, B.R. STORK and B.W. STEINERT

*Division of Paediatric Urology, Department of Urology, William Beaumont Hospital, Royal Oak, Michigan*

They found that the presence of a grade I varicocele appears to have no effect on normal testicular growth. On the other hand, patients with a grade II varicocele were found to be at risk of left testicular volume loss and patients with grade III varicoceles were at risk of bilateral testicular volume loss.

In this study varicocele was graduated clinically, and testicular size was measured using a standard orchidometer.

# ETIOLOGY and EPIDEMIOLOGY

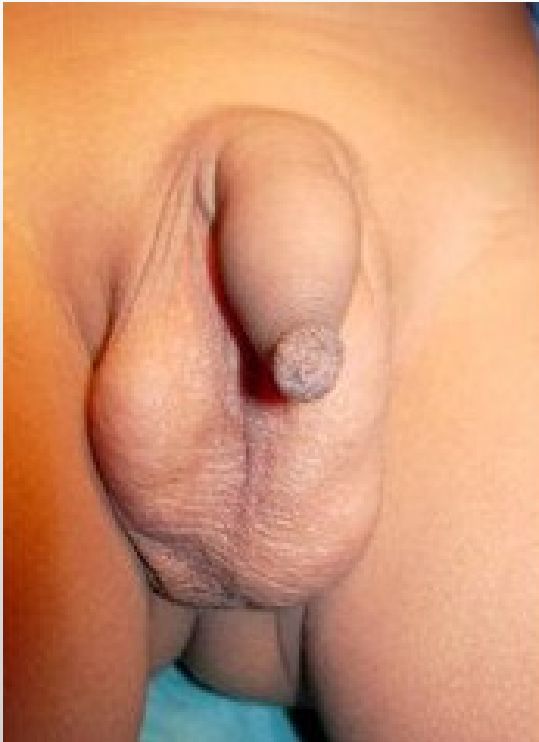Varicoceles are almost exclusively seen in pubertal or postpubertal patients.



They are rarely found in patients younger than 10 years, and the **incidence reaches 16% between ages 10 and 19 years.**

Other studies have noted that the **incidence varies from 9% to 29% between ages 10 and 17 years,** with the incidence in adults being approximately 15%.

# INCIDENCE

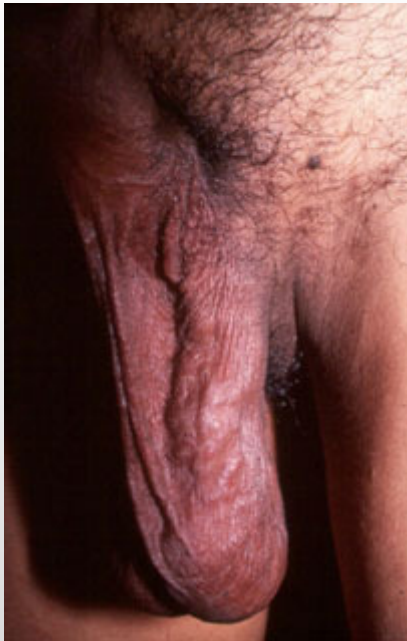

However, the true incidence in the pediatric population is difficult to ascertain because

**varicoceles could be asymptomatic** and may not come to the attention of health care providers until later in adulthood.

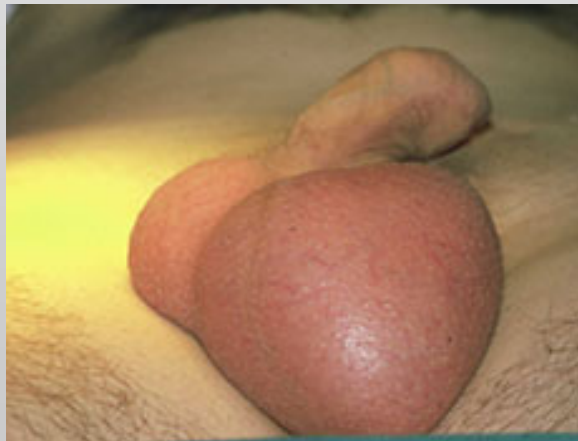

## DIAGNOSIS



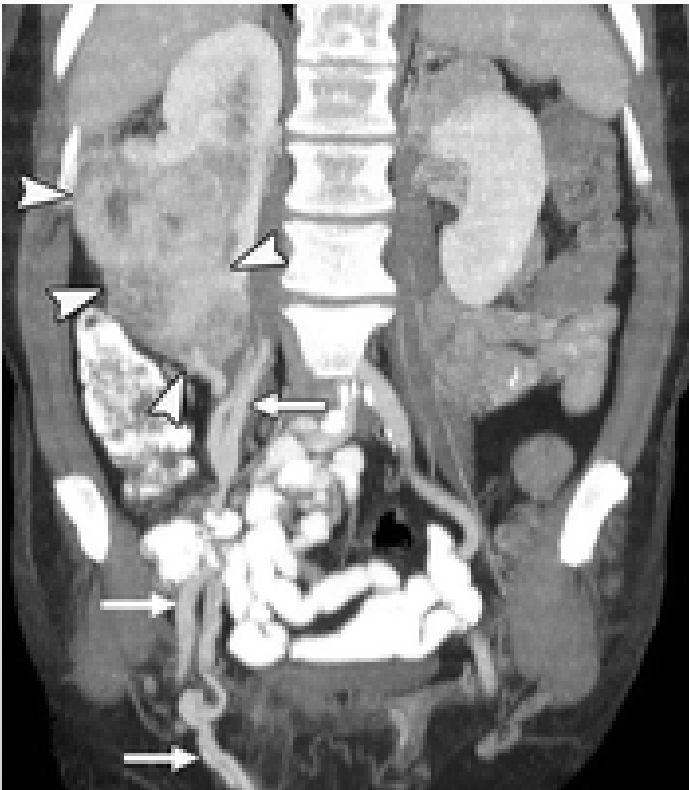
**Most adolescent varicoceles are asymptomatic** and are usually diagnosed as part of a routine physical examination or during testicular self-examination.

**Sometimes patients will present with scrotal or testicular discomfort or “heaviness.”**



Obviously, other causes of scrotal and testicular abnormalities include hernias, hydroceles, spermatoceles, and testicular or paratesticular masses.

# WATCH OUT

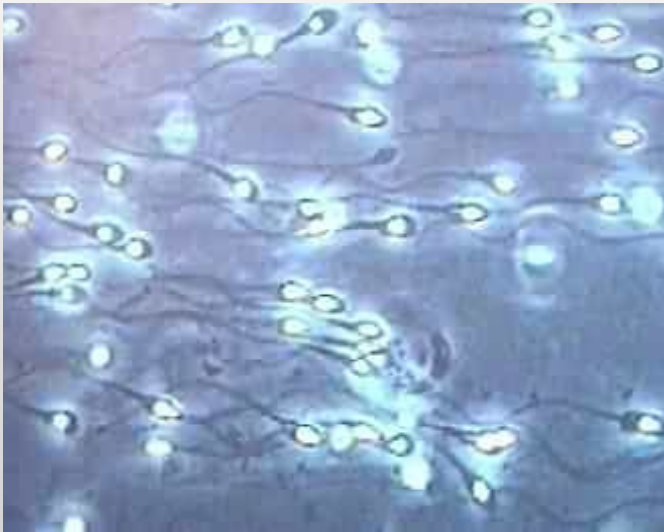


Approximately **90% of varicoceles are left-sided.**

**Bilateral varicoceles are palpable in approximately 3% of adolescents** and may be detected by ultrasound in up to 30% of adolescents with a palpable unilateral varicocele.

It has been advocated that patients with the sudden onset of a varicocele, a right-sided varicocele should undergo ultrasonography or CT to rule out malignancy before receiving treatment for the varicocele.

# SEMEN ANALYSIS

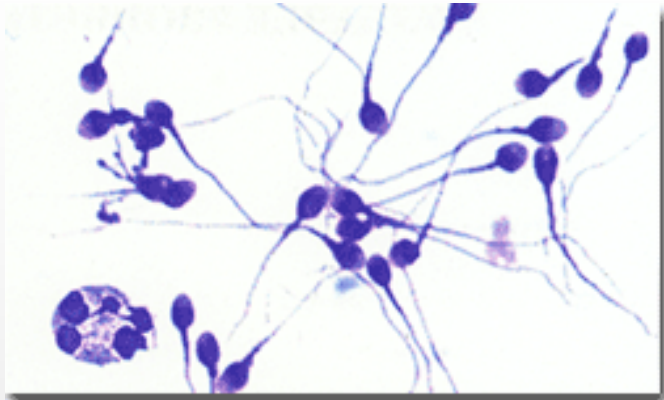


**It is a challenge to obtain semen samples in adolescents**


and

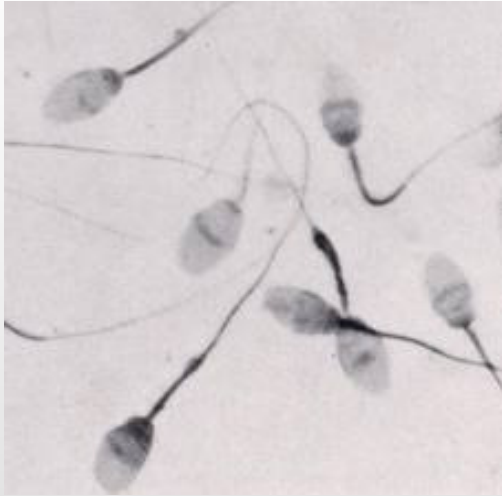few studies are available regarding the effect of varicocele on semen parameters.

**The “normal” ranges for semen parameters in adolescents are not established.**

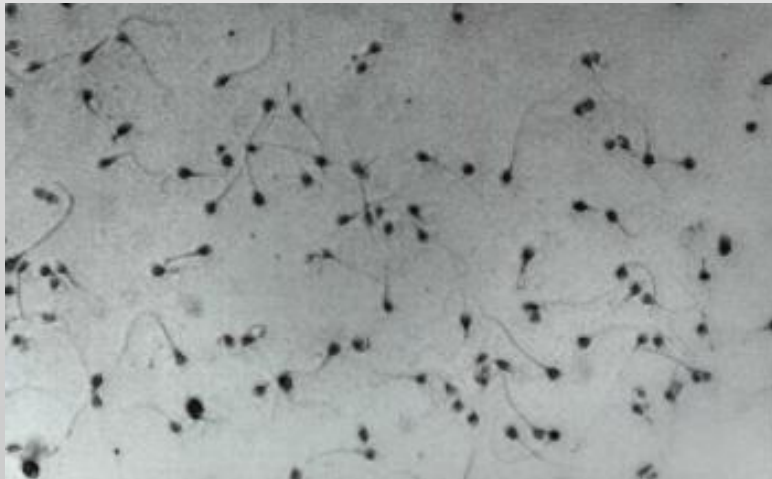


In 1996, a study comparing 36 boys without varicocele and 38 boys with varicocele **found statistically significant differences in sperm motility, viability, and total sperm counts between the two groups, indicating that varicocele does have a deleterious effect on semen parameters in adolescents.**





**A meta-analysis in 1994 showed that sperm concentration improved postoperatively in 12 of 16 published series and sperm morphology improved in 5 of 10.**



**In contrast, other study showed that varicocele grade does not correlate with abnormal semen analysis.**

## Clinical Prize Finalists

---

### Relationship of Varicocele Grade and Testicular Hypotrophy to Semen Parameters in Adolescents

David A. Diamond,\* David Zurakowski, Stuart B. Bauer, Joseph G. Borer, Craig A. Peters, Bartley G. Cilento, Jr., Harriet J. Paltiel, Ilina Rosoklija and Alan B. Retik

*From the Departments of Urology and Radiology (HJP), Children's Hospital Boston, Harvard Medical School, Boston, Massachusetts*

---

**Sonographically determined testicular differentials greater than 10% between normal and affected testes correlate with decreased total motile sperm count and may serve to identify adolescents with unilateral varicocele who are at greatest risk for future infertility.**

## Clinical Prize Finalists

---

### **Relationship of Varicocele Grade and Testicular Hypotrophy to Semen Parameters in Adolescents**

**David A. Diamond,\* David Zurakowski, Stuart B. Bauer, Joseph G. Borer, Craig A. Peters, Bartley G. Cilento, Jr., Harriet J. Paltiel, Ilina Rosoklija and Alan B. Retik**

*From the Departments of Urology and Radiology (HJP), Children's Hospital Boston, Harvard Medical School, Boston, Massachusetts*

---

This study was appropriately confined to Tanner stage V patients.

There are some limitations: of the boys 61% submitted 1 semen specimen, there is not a control group for comparison and the number of Patients (57 pts) available for study was modest.


**Longitudinal Study of Semen Quality  
in Adolescents with Varicocele: To Treat  
or Not?**

Nicola Zampieri, Michele Corroppolo, Veronica Zuin, Raimondo Maximillian Cervellone,  
Alberto Ottolenghi, and Francesco Saverio Camoglio

In **another study of 214** patients with varicoceles, Zampieri et al. **found no differences in semen parameters** when comparing men with or without testicular hypotrophy.



# TESTICULAR VOLUME

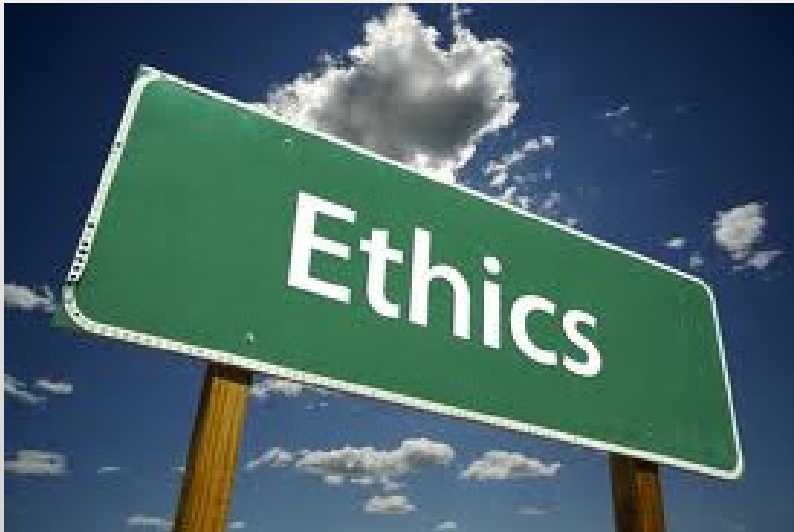

**Testicular volumes are** not only important for initial clinical planning but are also **helpful in assessing response to treatment.**

During examination, **it is imperative to assess the size and consistency of the testicles.**

**Important to compare the volume of the testes with each other.**

# TREATMENT



**The treatment of the adolescent varicocele raises several interesting clinical and ethical dilemmas.**

In adults, it is well established that patients with varicoceles exhibit abnormalities in their semen parameters and abnormal testicular function that may ultimately affect fertility potential.



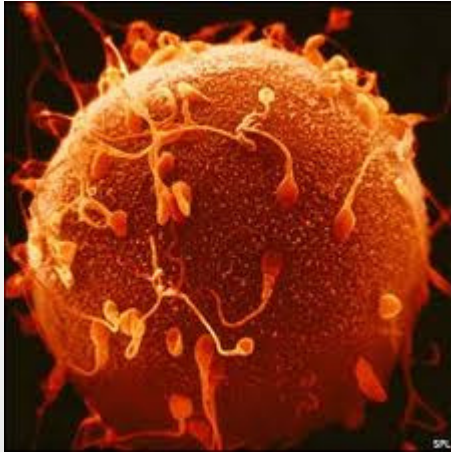
On semen analysis, **adults with varicoceles are known to have increased number of pathologic sperm forms, decreased sperm motility, and decreased sperm density.**

**In presence of a clinically detectable varicocele associated with an abnormal semen analysis in an infertile couple is an appropriate indication for treatment.**

**If we treat all adolescents with varicoceles, are we potentially decreasing the time period that the affected testicle is exposed to the deleterious conditions created by a varicocele?**

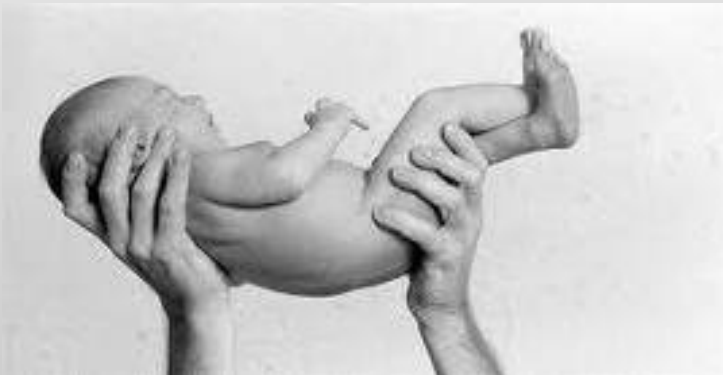**So, where does this leave the adolescent varicocele patient who presumably is several years away from needing to worry about fertility potential?**






Interestingly, the **incidence of varicoceles is much higher than that of male factor infertility.**

Furthermore, the finding that **only 15% to 20% of men with varicoceles seek treatment for fertility implies that most men with varicoceles either choose not to seek treatment or are fertile.**





Perhaps **the main difference is that the adolescent testicle may recover from damage more readily than the adult testicle.**

**Adolescent testicles after varicocele repair almost always exhibit “catch-up” growth.**

**But, it is not known whether varicocele in adolescence impairs fertility or whether surgery restores fertility.**

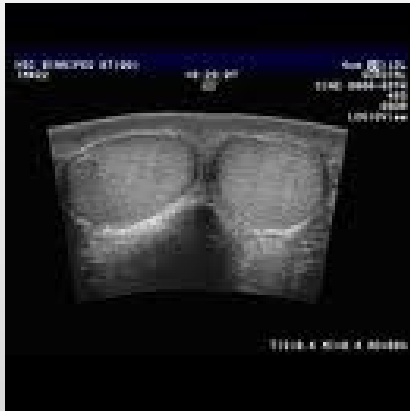
**The evaluation and choice of treatment for the adolescent varicocele patients is based not on objective fertility criteria (paternity)**

**But**

**on indirect evidence that there may be compromise to testicular function or spermatogenesis and thus eventual fertility.**



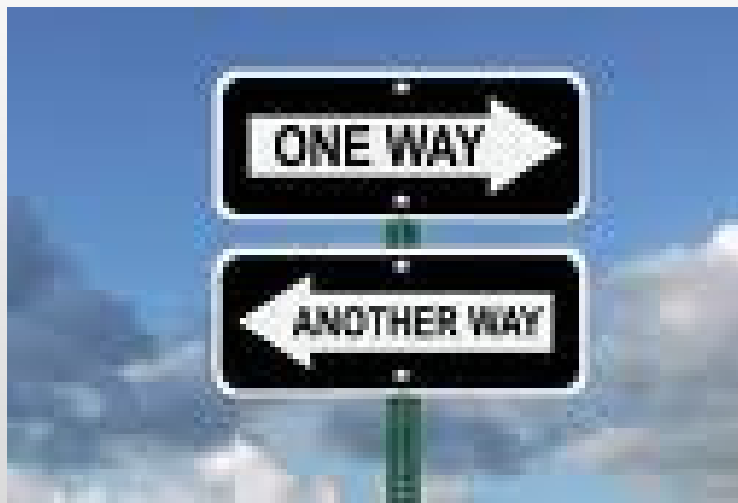# VARICOCELE REPAIR and TESTICULAR GROWTH



**Testicular Growth After Varicocele Repair Catch-up growth of the affected testicle following varicocele surgery has been reported by several groups.**



Studies suggest that varicocele repair in older adolescents significantly increases sperm values, especially motility and total motile sperm count



Adding to the controversy in this patient population is the report by some of testicular growth in conservatively managed patients with varicoceles

# **SURGICAL TREATMENT**

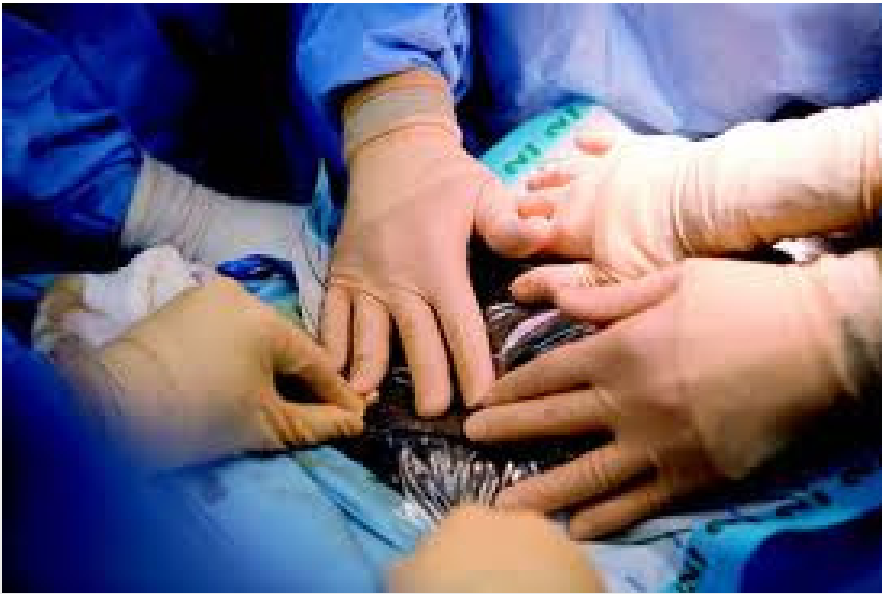**Current recommendations for adolescent varicocele repair are based on the findings of persistently impaired testicular growth.**

**The main indication for surgery is testicular hypotrophy ( > 2 mL or > 20%) on the affected side.**

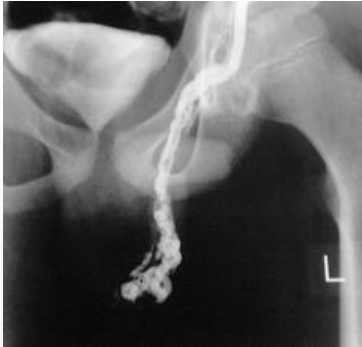As growth can vary between the testes, the difference in size should be confirmed by two measurements made 12 months apart.

**Relative indications for varicocele repair are:**

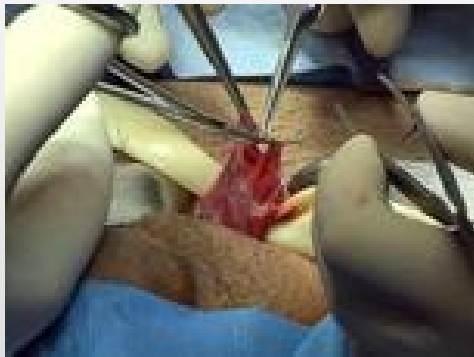- **a soft testis,**
- **bilateral grade 3 varicocele with no testicular hypotrophy,**
- **presence of varicocele in a solitary testis,**
- **poor semen analysis in a Tanner V adolescent** (preferably confirmed on two specimens),
- **the rare conditions of pain or intratesticular varicocele.**



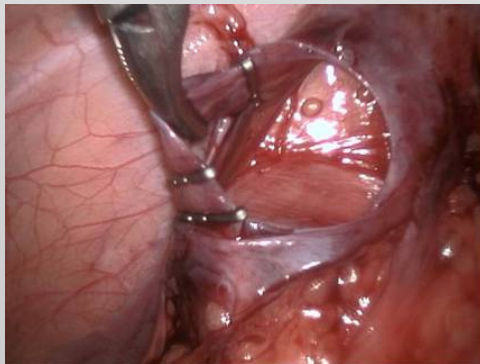
**The boys and their families must be aware of the uncertainties about the significance of varicocele and the indications for surgery.**

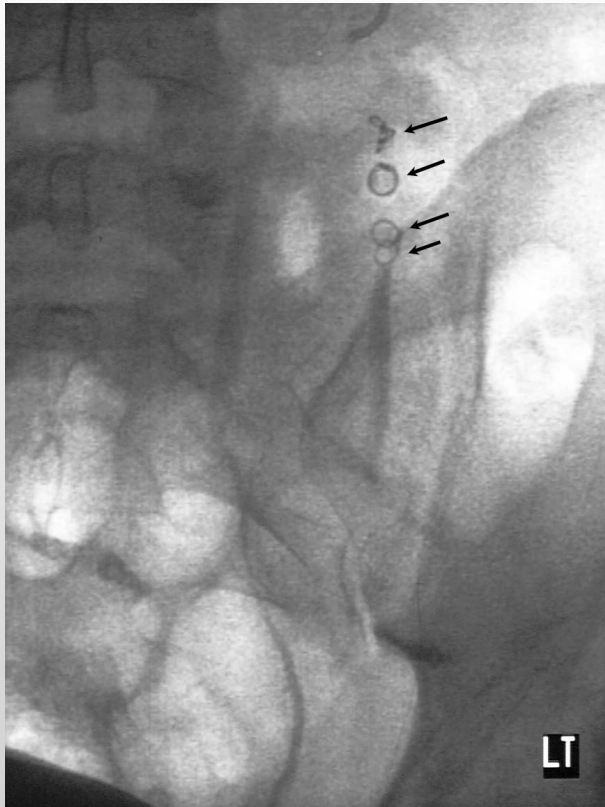


**All of the methods available for treating adults, including radiological, laparoscopic and open surgery, are appropriate for adolescents.**



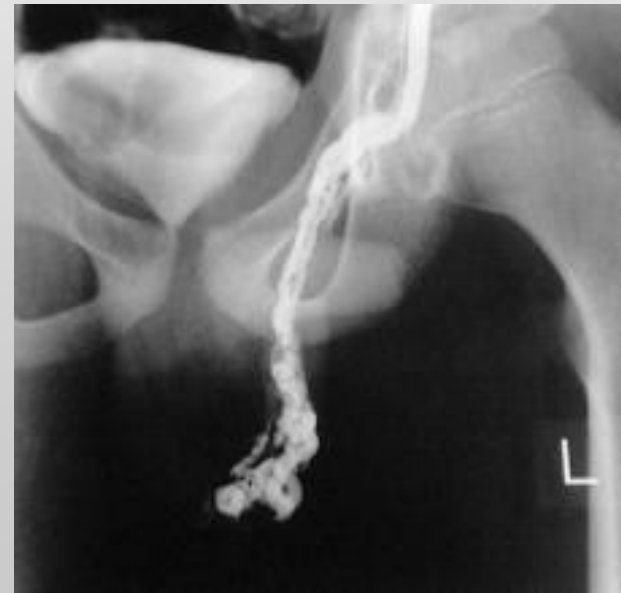**The best treatment for varicocele should include elimination of the varicocele, with low complication rates.**



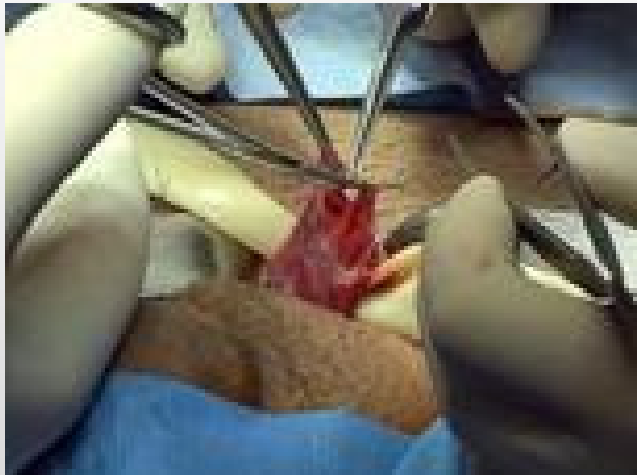


**Radiological embolization or sclerotherapy of spermatic veins is a minimally invasive procedure**, but it has a **failure rate of up to 15%**, and needs sufficient skill and experience.

Antegrade sclerotherapy is minimally invasive and might be done under local or general anaesthesia. The success rate is  $> 90\%$  and hydroceles are not a complication.

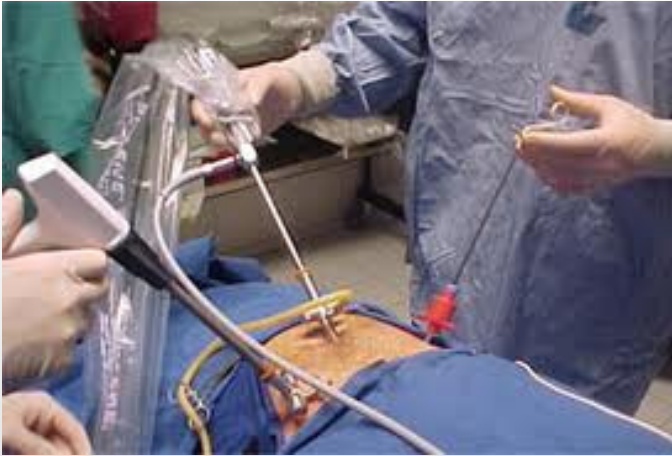

The high retroperitoneal (**Palomo**) and laparoscopic approaches **can be used for internal spermatic vein ligation.**



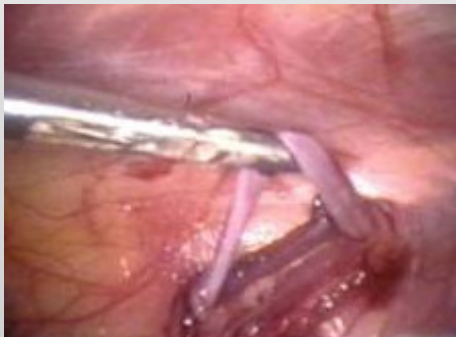The inguinal (**Ivanissevich**) and subinguinal approaches **can be also used to ligate the external spermatic veins.**

The use of high magnification allows the testicular artery, lymphatics and small venous channels to be identified, giving a significant decrease in the incidence of hydrocele formation, testicular artery injury and varicocele recurrence.

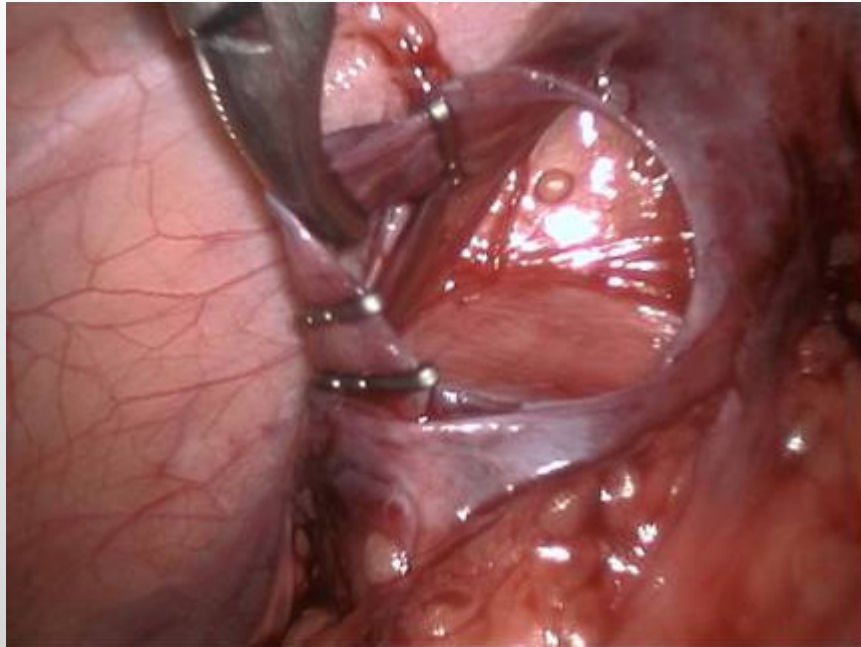

**Laparoscopic and retroperitoneoscopic varicocelectomy have gained popularity in the last decade.**

**Irrespective of the approach, the procedure is a Palomo high ligation of the vein.**

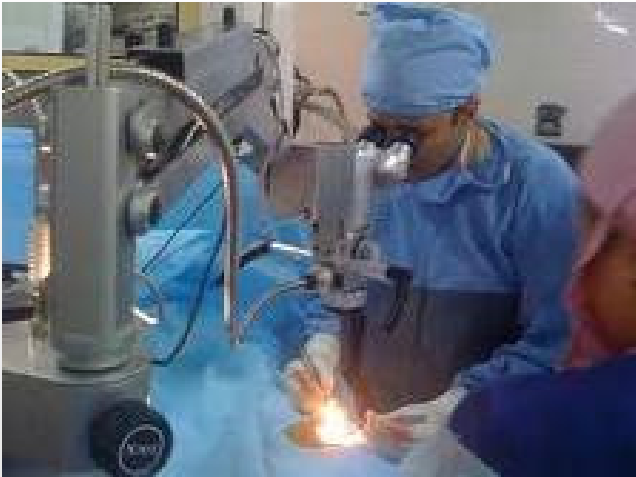



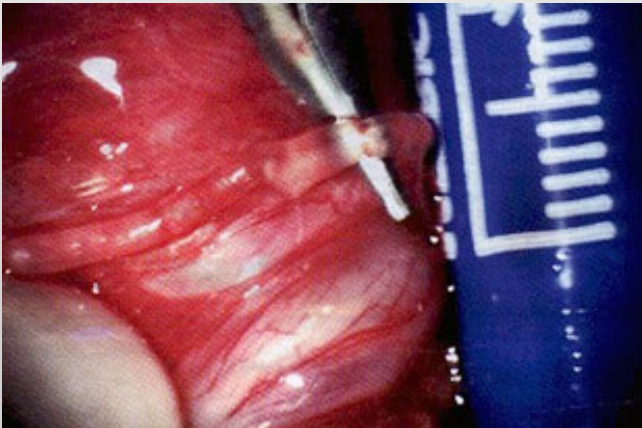


The **optical magnification of the laparoscope** and the **broad anatomical view** through the peritoneum **allow for precise identification of all the dilated veins**, as well as for sparing the lymphatic vessels in order to also prevent postoperative hydrocele.

**Use of a vital dye enhancing the lymphatic vessels** after injection in the scrotum close to the tunica vaginalis has been suggested to make lymphatic sparing easier.



Although most methods of varicocelectomy result in similar short-term results, **open microsurgical inguinal or subinguinal techniques in adults have been shown to cause fewer recurrences and complications.**



# COMPLICATIONS

**Complications after surgery vary with surgical techniques.**

**Recurrences after varicocele repair are reported in 0–16.6%,  
varying with the technique used.**

**Hydrocele in adolescents is a potential problem, with an  
incidence of 0–24%.**

The low, selective venous approaches using magnification to  
preserve the lymphatics reduce this risk.

# COMPLICATIONS

**Other complications** include **wound infection, testicular atrophy and ilio-inguinal nerve damage, but the incidence is unrecorded.**

Testicular atrophy would be a devastating complication.

None of the major series report this complication, but personal communication suggests that it can occur.

# OUR PERSONAL EXPERIENCE

**Urologia**  
Internationalis

Original Paper

Urol Int 425  
DOI: 10.1159/000XXXXXX

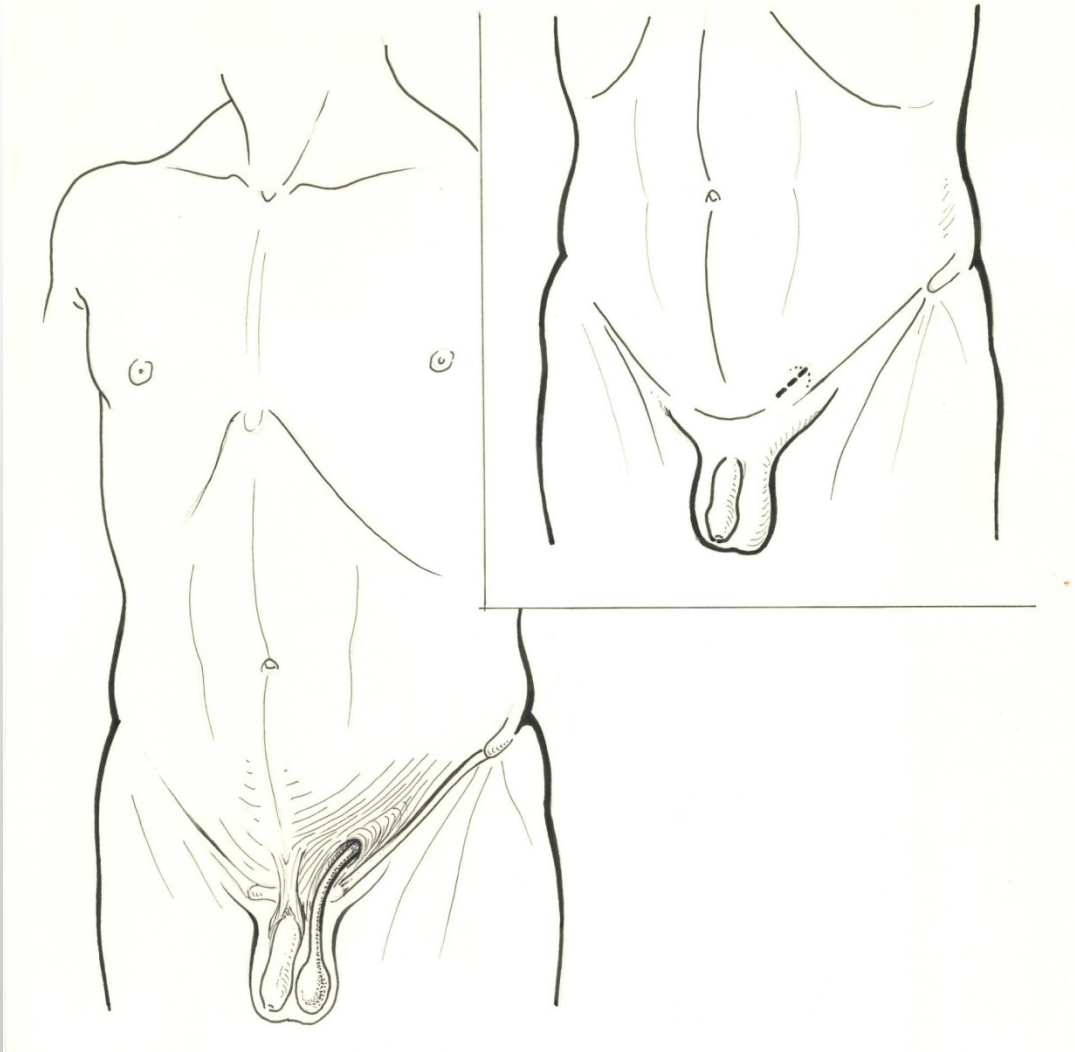
Received: March  
Accepted after

## **Sclerotherapy of the Pampiniform Plexus with Modified Marmar Technique in Children and Adolescents**

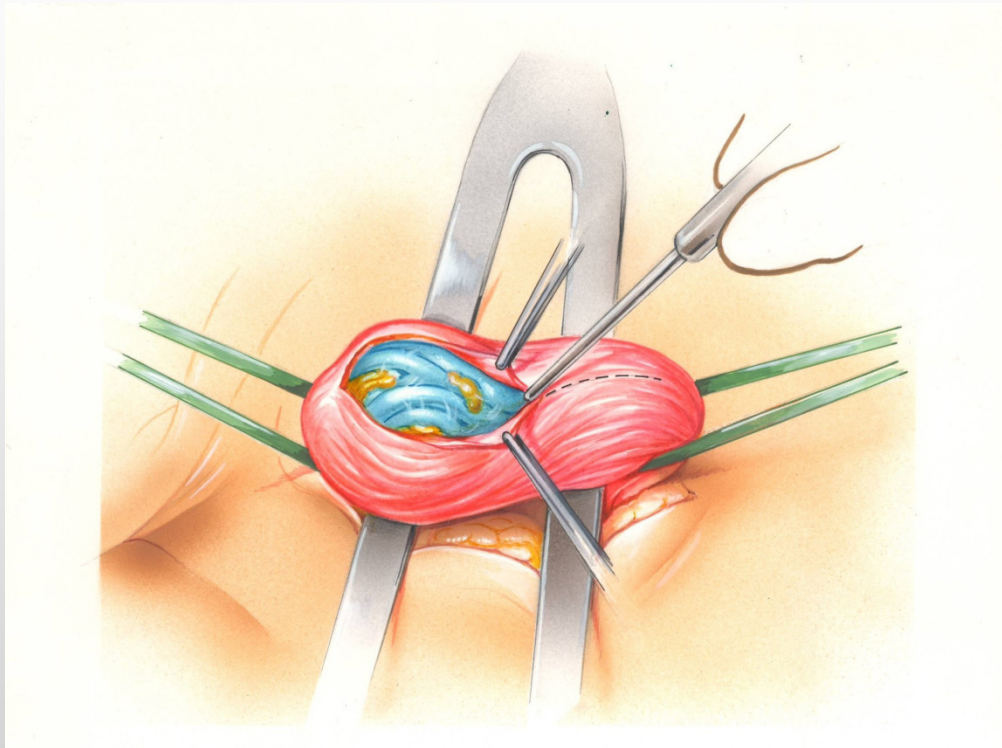
Luca Carmignani<sup>a</sup> Stefano Casellato<sup>a</sup> Giacomo Galasso<sup>a</sup> Giorgio Bozzini<sup>a</sup>  
Matteo Spinelli<sup>a</sup> Carlo Alberto Dell'Agnola<sup>b</sup> Francesco Rocco<sup>a</sup>

<sup>a</sup>Urology Unit, Ospedale Maggiore Policlinico, Mangiagalli e Regina Elena, University of Milan, and

<sup>b</sup>Pediatric Surgery Unit, Ospedale Ca' Granda Niguarda, University of Milan, Milan, Italy

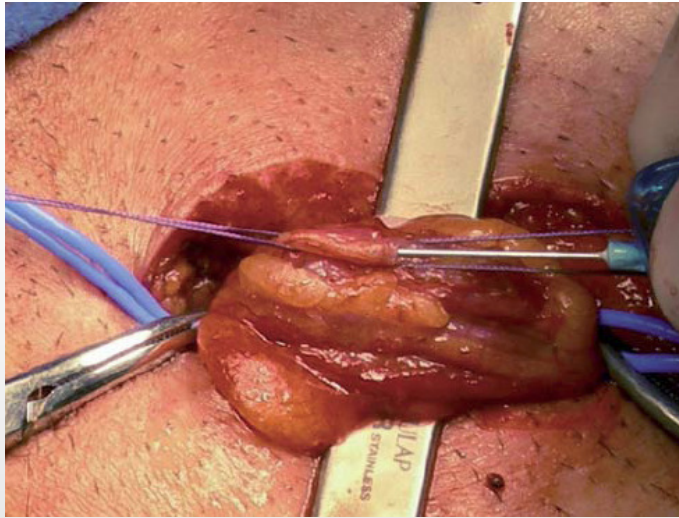


A 2-3 cm, distal subinguinal incision is made at the level of the superficial inguinal ring.

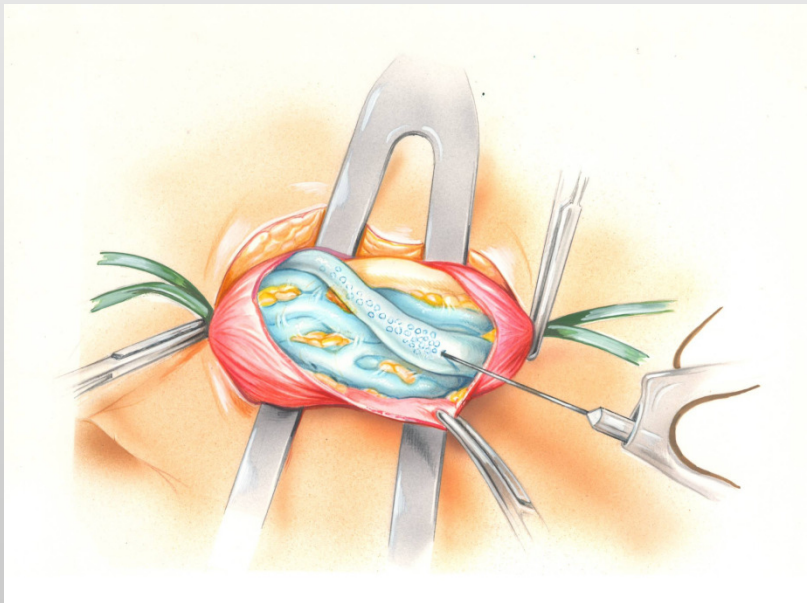


The exposure of the spermatic cord, subsequently extended between two ligatures.

A separate opening of the external and internal spermatic fasciae is shown.



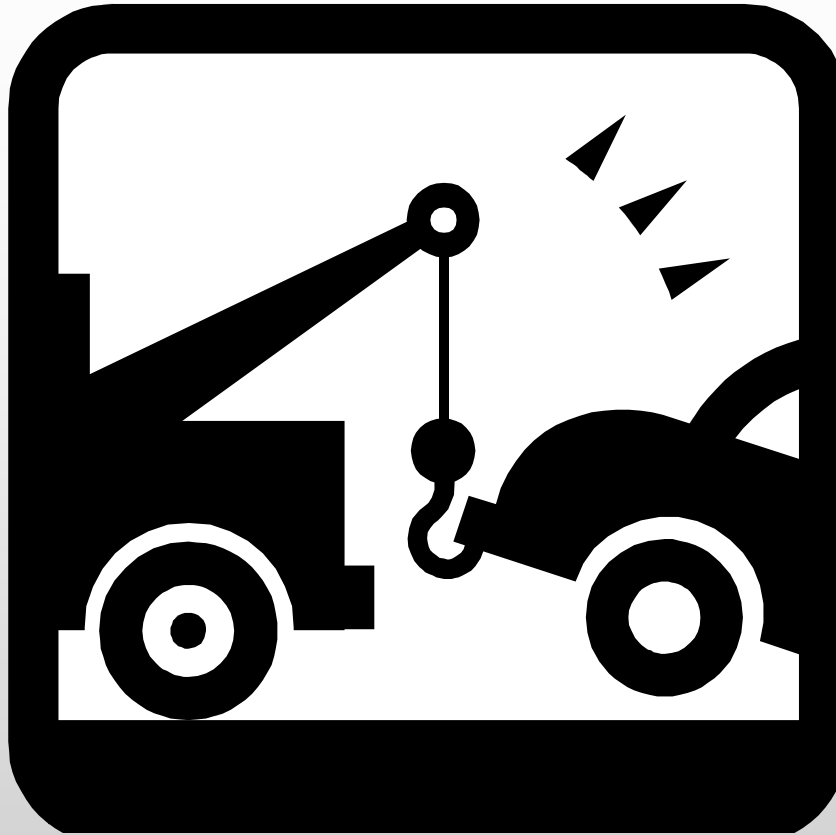The cannulation of the most dilated vein and the injection of the sclerosing agent. Bubbles migrate into the veins.





**Table 1.** Persistence/recurrence of varicocele 6 months after surgery and main complications

Period	2004	2005	Total
Number of operations	12	13	25
Recurrences	1	0	1 (4%)
Complications	1	1	2 (8%)
Lymphangitis	0	0	0
Orchialgia	0	0	0
Orchio-funiculitis	0	0	0
Hydrocele	1	0	1 (4%)
Spermatic cord edema	0	1	1 (4%)



Thank You